

Abdominal Wall Abscess Secondary to Spilled Gallstones 20 Years after Laparoscopic Cholecystectomy

Rubiya Ali¹, Asia Mohammad Azam², Uzair Yaqoob² and Lubna Habib²

¹Department of Medicine, The Indus Hospital, Karachi, Pakistan

²Department of General Surgery, Hamdard University Hospital, Karachi, Pakistan

ABSTRACT

This case report describes an intra-abdominal and abdominal wall abscess formation in a 53-year male. The abscess developed 20 years after an uncomplicated laparoscopic cholecystectomy. He presented to multiple clinics with complaints of abdominal swelling and pain and had been prescribed multiple courses of antibiotics in the preceding six months before a definitive diagnosis was made. Subsequent ultrasound and computed tomography scans confirmed intra-abdominal abscess infiltrating the liver and the abdominal wall abscess. Incision and drainage were performed and multiple gallstones in the abscess cavity were visualised. Early postoperative complications including abscess formation usually come to attention; however, the importance of late complications should not be undervalued, especially when an abscess develops in a patient with a history of recent or remote cholecystectomy. Thorough investigation, consideration of possible diagnosis related to abscess formation post-cholecystectomy, and timely action is the key to management.

Key Words: Abdominal wall abscess, Laparoscopic cholecystectomy, Complications, Retained gallstones.

How to cite this article: Ali R, Azam AM, Yaqoob U, Habib L. Abdominal Wall Abscess Secondary to Spilled Gallstones 20 Years after Laparoscopic Cholecystectomy. *JCPSP Case Rep* 2023; 1:68-70.

INTRODUCTION

While most patients with gallstones are asymptomatic, 10% develop cholecystitis. The timing of surgical intervention for acute cholecystitis is still debated, but early laparoscopic cholecystectomy has been widely accepted as the gold standard treatment since 1992, offering significant advantages over open techniques such as reduced postoperative pain, lower morbidity, improved cosmetic outcomes, and shorter hospital stays.¹ Nevertheless, it is important to acknowledge that the minimally invasive nature does come with potential complications.²

Gallbladder perforation with subsequent gallstone spillage is one potential complication that is reported in 6 to 40% of cases. This spillage is most commonly observed during the dissection phase (42–75%), followed by traction (15–51%), or during the removal of the gallbladder through a narrow trocar incision (5–10%).² Additionally, about one-third of spilled gallstones are not retrieved. Complications resulting from spilled gallstones can vary in incidence, ranging from 0.04 to 19%.³

Abscess formation secondary to spilled gallstones can occur in months to years after laparoscopic cholecystectomy,⁴ primarily occurring along the surgical incision or port insertion sites.² Presented here is a unique case of abscess formation occurring 20 years after an uneventful laparoscopic cholecystectomy, substantial in size, and situated away from the surgical incision or port insertion site.

CASE REPORT

A 53-year male, known diabetic and on oral hypoglycemics for the last 20 years, presented to the emergency department with complaints of abdominal swelling for six months and abdominal pain for 20 days. He was in the usual state of health until six months back when he noticed a swelling in the right iliac fossa that gradually increased in size and progressed up to the right hypochondrium. He also complained of pain over the swelling which was throbbing in character, non-radiating, had no aggravating factors, and was relieved by over-the-counter analgesics. He also had on-and-off fever of low-grade intensity, 3–4 times a day, and was undocumented. He denied any weight loss, anorexia, or other gastrointestinal symptoms. He was prescribed multiple courses of antibiotics by general practitioners, whose record was unavailable. At a tertiary care hospital, a diagnosis of abdominal wall abscess was made after an ultrasound-guided aspiration three months back. After the procedure, he again started noticing a gradual increase in the size of the swelling.

Correspondence to: Dr. Uzair Yaqoob, Department of General Surgery, Hamdard University Hospital, Karachi, Pakistan

E-mail: ozair_91393@hotmail.com

Received: March 31, 2023; Revised: July 12, 2023;

Accepted: July 21, 2023

DOI: <https://doi.org/10.29271/jcpspcr.2023.68>

According to the records, he had a history of laparoscopic cholecystectomy 20 years back which went uneventful. The remainder of his systemic review was unremarkable.

Physical inspection revealed a large, diffuse, soft, and fluctuant swelling of around 15×5 cm with irregular borders, extending from the right hypochondrium to the upper border of the anterior superior iliac spine. The swelling was fixed to the skin but not to the abdominal muscles. On the contraction of abdominal wall muscles, the mass became fixed and more prominent. Importantly, the cough impulse was negative.

During the initial investigations, his total leucocyte count was $11.2 \times 10^3/\text{mm}^3$, C-reactive protein was 6.38 mg/dl, the erythrocyte sedimentation rate was 40 mm/1st hour, and haemoglobin A1c was 9.4%. The rest of the laboratory investigations were normal. Ultrasound of abdomen revealed an ill-defined hypoechoic area in the right abdominal wall of 18.0 × 1.5 × 4.5 cm, likely representing an abdominal wall abscess.

A computed tomography scan of the abdomen and pelvis showed a loculated abscess with surrounding inflammation along the anterior and lateral aspect of the right lobe of the liver infiltrating the adjacent right lower chest wall muscles and in the right anterior and lateral abdominal walls with involvement of the right anterior abdominal wall muscles and infiltration of the lower margin of the right lobe of the liver and right lower ribs associated with minimal right-sided pleural effusion and small calcified granuloma in the right lobe of liver possibly due to tuberculosis (Figure 1).

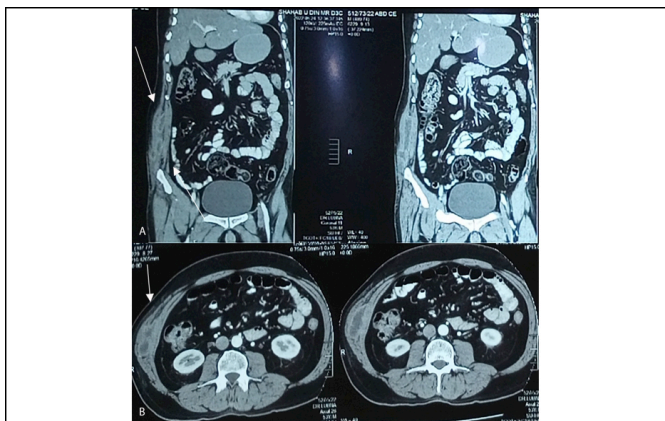


Figure 1: Computed tomography scan showing a loculated abscess (arrows) infiltrating the lower chest wall, anterior and lateral abdominal wall, right lobe of the liver, and adjacent ribs.

Ultrasound-guided aspiration was done where 15 ml of thick brownish fluid was aspirated from the right anterior abdominal wall and was sent for analysis which had lactate dehydrogenase, 2198 U/L; total protein, 4.8 g/dl; total white blood cells, 14500 with 20% lymphocytes and 80% neutrophils and had a coagulum. Gram stain showed pus cells with no organisms. Culture and sensitivity, and acid-fast bacilli smear/ Gene Xpert showed no growth. After the procedure, there was mild relief of symptoms temporarily.

The patient was prepared for incision and drainage under general anaesthesia. The abscess was found below the external oblique aponeurosis with small gallstones. The wound was washed and packed with aseptic dressing. It was kept open and the patient was advised daily dressing along with antibiotics. The final diagnosis was abscess secondary to retained gallstones. The patient was followed up till six months postoperatively and there were no new complaints with complete resolution of symptoms and healing of the wound.

DISCUSSION

According to a recent systematic review carried out by Gravididis *et al.*, abscess formation emerged as the predominant complication in laparoscopic cholecystectomy secondary to spilled gallstones, accounting for 56.5% of cases.⁵ Among these, intraabdominal abscesses were the most frequently observed, followed by the abdominal wall and retroperitoneal abscesses. Other potential complications included subhepatic and subphrenic abscesses, intestinal obstruction or perforation, abdominal or pleural empyema, adhesions, and fistula formation.⁵⁻⁷ Complications related to the biliary tract encompassed biliary obstruction, inflammation, and biliary-cutaneous fistulae.⁷

Several studies have examined the risk factors associated with gallbladder perforation during laparoscopic cholecystectomy. Key factors (some of which are avoidable) include old age, male gender, obesity, the presence of multiple (>15), large (>1.5 cm) or pigmented gallstones, an acutely inflamed gallbladder, the perihepatic location of spilled gallstones, and the presence of adhesions.^{5,8,9} Additionally, iatrogenic causes such as surgeon's expertise, instrument laceration, loss of cystic duct clip, and tearing of the gallbladder during retrieval through port sites can also lead to gallstone spillage.⁹

In cases where an intact gallbladder cannot be safely extracted through an undersized port site, extending the port size is a viable option. However, conversion to open cholecystectomy is not necessary as the complication rate associated with spilled gallstones is less than 1%.¹⁰ Several measures can be taken to minimise spillage including meticulous dissection with accurate identification of anatomical planes, avoiding gallbladder perforation, and promptly closing any perforations using grasp forceps or endoclip and endoloop techniques. Additionally, the use of a grasper or "shuttle" stone collector, a retrieval or suction device, and an endo bag can aid in extracting as much gallbladder content as possible. Copious irrigation is recommended to dilute irritative bile salts and flush the port site with saline, ensuring the dislodgement of any remaining stones.^{7,8,10}

Nonetheless, if gallstones remain unretrieved, their presence should be documented in the operative notes to highlight the potential short and long-term complications.¹⁰ Surprisingly, the majority of surgeons underestimate complications related to gallstone spillage. Merely 20% of surgeons include gallbladder perforation and gallstone spillage as possible complications in their pre-procedure consent form. Even if such complications

do occur, only around 23% of surgeons document those in their operative notes.⁵

Early postoperative complications, including abscess formation, usually come to attention; however, the importance of late complications should not be underestimated, especially when an abscess develops in a patient with a recent or remote history of cholecystectomy. This emphasises the importance of meticulous and prompt removal of any spilled gallstones by surgeons performing cholecystectomy. Thorough investigation, consideration of possible diagnosis related to post-cholecystectomy abscess formation, and timely intervention are key factors in effective management.

PATIENT'S CONSENT:

A written informed consent was obtained from the patient.

COMPETING INTEREST:

The authors declared no competing interest.

AUTHORS' CONTRIBUTION:

RA, AMA, UY, LH: All authors made substantial contributions to the conception and design of the work. They were involved in drafting the work and revising it critically for important intellectual content and final approval of the version to be published. They agree to be accountable for all aspects of the work in ensuring that questions related to the accuracy or integrity of any part of the work are appropriately investigated and resolved.

REFERENCES

1. Mou D, Tesfasilassie T, Hirji S, Ashley SW. Advances in the management of acute cholecystitis. *Ann Gastroenterol Surg* 2019; **3(3)**:247-53. doi: 10.1002/ags3.12240.
2. Salati SA, Alfehaid M, Alsuwaydani S, AlSulaim L. Spilled gallstones after laparoscopic cholecystectomy: A systematic review. *Polish J Surg* 2022; **95(2)**:55-78. doi: 10.5604/01.3001.0015.8571
3. Jabbari Nooghabi A, Hassanpour M, Jangjoo A. Consequences of lost gallstones during laparoscopic cholecystectomy: A review article. *Surg Laparosc Endosc Percutan Tech* 2016; **26(3)**:183-92. doi: 10.1097/SLE.0000000000000274.
4. Faour R, Sultan D, Houry R, Faour M, Ghazal A. Gallstone-related abdominal cystic mass presenting 6 years after laparoscopic cholecystectomy: A case report. *Int J Surg Case Rep* 2017; **32**:70-72. doi: 10.1016/j.ijscr.2017.01.059.
5. Gavriilidis P, Catena F, de'Angelis G, de'Angelis N. Consequences of the spilled gallstones during laparoscopic cholecystectomy: A systematic review. *World J Emerg Surg* 2022; **17(1)**:57. doi: 10.1186/s13017-022-00456-6.
6. Zehetner J, Shamiyeh A, Wayand W. Lost gallstones in laparoscopic cholecystectomy: All possible complications. *Am J Surg* 2007; **193(1)**:73-78. doi: 10.1016/j.amjsurg.2006.05.015.
7. Nadia H, Noor B, Daan M. Osteomyelitis as a rare complication of laparoscopic cholecystectomy: A case report. *World J Med Surg Case Rep* 2019; **8(3)**.
8. Akhtar A, Bukhari MM, Tariq U, Sheikh AB, Siddiqui FS, Sohail MS, Khan A. Spilled gallstones silent for a decade: A case report and review of literature. *Cureus* 2018; **10(7)**: e2921. doi: 10.7759/cureus.2921.
9. Hawasli A. Remote complications of spilled gallstones during laparoscopic cholecystectomy: causes, prevention, and management. *J Laparoendosc Adv Surg Tech* 2002; **12**:123-8. doi: 10.1089/10926420252939664.
10. Christensen AM, Christensen MM. Abdominal wall abscess containing gallstones as a late complication to laparoscopic cholecystectomy performed 17 years earlier. *J Surg Case Rep* 2013; **2013(1)**:rjs038. doi: 10.1093/jscr/rjs038.

.....