

# Urrets-Zavalía Syndrome Following Penetrating Keratoplasty in a Case of Macular Corneal Dystrophy

Muhammad Saad Aziz<sup>1</sup>, Khawaja Khalid Shoaib<sup>1</sup>, Ahsan Mehmood<sup>2</sup> and Muhammad Awaid Abid<sup>3</sup>

<sup>1</sup>Department of Ophthalmology, Mughal Eye Hospital, Lahore, Pakistan

<sup>2</sup>Department of Ophthalmology, Russells Hall Hospital, Dudley, UK

<sup>3</sup>Department of Ophthalmology, Layton Rahmatulla Benevolent Trust (LRBT), Lahore, Pakistan

## ABSTRACT

This article presents a case of Urrets-Zavalía Syndrome (UZS), a rare complication following an uneventful penetrating keratoplasty (PKP) carried out for macular corneal dystrophy (MCD) in a 23-year-old patient in a tertiary care hospital. The patient exhibited peripheral anterior synechiae (PAS) with elevated intraocular pressure (IOP) during his one-week follow-up. Despite the administration of topical and systemic IOP-lowering medications as well as miotic agents, the patient's IOP remained unresponsive. Consequently, we performed a therapeutic synechiolysis to alleviate the elevated IOP. Early surgical intervention proved crucial in preventing the patient from developing glaucomatous damage secondary to elevated IOP. This case highlights the significance of close monitoring with prompt surgical management to prevent sight-threatening complications associated with UZS following PKP.

**Key Words:** Peripheral anterior synechiae, Mydriatic drops, Penetrating keratoplasty, Fixed and dilated pupil, Urrets-Zavalía Syndrome.

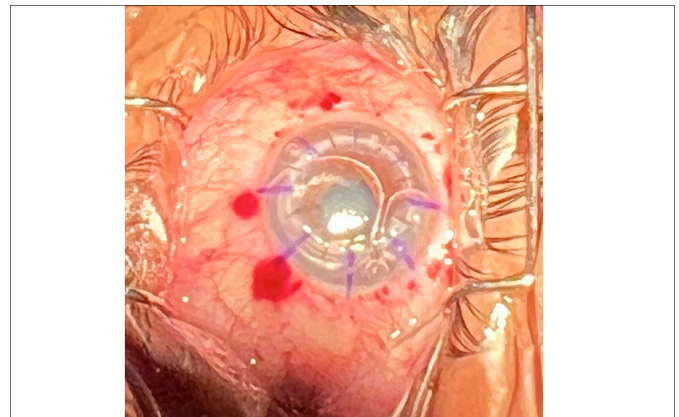
**How to cite this article:** Aziz MS, Shoaib KK, Mehmood A, Abid MA. Urrets-Zavalía Syndrome Following Penetrating Keratoplasty in a Case of Macular Corneal Dystrophy. *JCPSP Case Rep* 2023; **1**:119-121.

## INTRODUCTION

Urrets-Zavalía Syndrome (UZS) is a fixed, dilated pupil occurring after penetrating keratoplasty (PKP) in keratoconus with mydriatic use, first described in 1963.<sup>1</sup> Its exact cause remains uncertain, but it may involve a sudden rise in intraocular pressure (IOP) and iris ischemia.<sup>2</sup> UZS can also follow other eye surgeries like cataract, glaucoma filtration, and vitreoretinal procedures. Risk factors include topical mydriatic use, retained viscoelastic material,<sup>3</sup> surgical trauma, inflammation, and iris innervation changes. In the present case, UZS resulted from intracameral air injection travelling behind the iris and using a topical mydriatic to facilitate air bubble passage to the anterior chamber on the first postoperative day.

## CASE REPORT

A 23-year male presented with bilateral macular corneal dystrophies (MCDs) for which PKP was planned first in the right eye. This patient had no history of glaucoma or any other ocular disease. The surgery was uneventful. At the end of the surgery, intracameral air bubble was injected to keep the anterior chamber (AC) maintained (Figure 1).



**Figure 1:** Immediate postoperative picture shows air bubbles in the anterior chamber. The pupil seems to be round.

On the first postoperative day, the graft was well-centred and secured with interrupted 10-0 nylon sutures. There was mild striate keratopathy on the first postoperative day but the AC details were clear. The AC was well formed but irregular because of the air bubbles that had travelled back into the posterior chamber between the iris and crystalline lens, now pushing the iris forward on one side. The pupil was also round. IOP was 18 mm Hg on applanation tonometry. The patient was laid in a supine position and a drop of 0.5% cyclopentolate was instilled to facilitate the passage of air bubble into the AC. On one-week--follow-up, there was corneal oedema with peripheral anterior synechiae (PAS), the pupil was fixed and dilated, the air had absorbed, and the IOP was 42 mm Hg. Intravenous mannitol 20% was given to lower IOP which brought the IOP down to 35 mm Hg. The patient was then discharged on oral and topical IOP-lowering agents along with a miotic agent. After two-day follow-

Correspondence to: Dr. Muhammad Saad Aziz, Department of Ophthalmology, Mughal Eye Hospital, Lahore, Pakistan

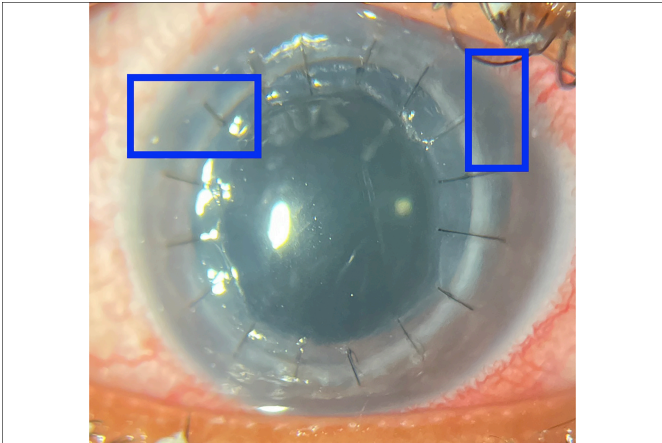
E-mail: saadaziz79@gmail.com

Received: July 17, 2023; Revised: August 31, 2023;

Accepted: October 30, 2023

DOI: <https://doi.org/10.29271/jcpspcr.2023.119>

up, the IOP was still 35 mm Hg and the pupil was still fixed and dilated. Based on these observations, a diagnosis of UZS was made. A therapeutic synechiolysis was performed to reduce IOP. After synechiolysis, the IOP was reduced to 12 mm Hg (Figure 2).



**Figure 2: Blue boxes show removed peripheral anterior synechiae (PAS) after synechiolysis.**

## DISCUSSION

The incidence of UZS after PKP is 2.2-17.7% in the literature.<sup>4</sup> The primary diseases of UZS patients include keratoconus, viral keratitis, fungal corneal ulcers, and corneal degenerations.<sup>4</sup> It is also seen in corneal dystrophies.<sup>5</sup>

The aetiology of UZS remains unclear. Ischemia of the iris along with sudden acute rise in IOP are believed to be commonly accepted mechanisms. Several other mechanisms that are believed to play a role include the use of mydriatics and damage to the pupillary sphincter during surgery. The degree of iris ischemia and atrophy determines the amount of pupillary dilatation and if the likely damage to the iris is reversible or irreversible.

In the present case, PKP was uneventful and there was no use of mydriatics during surgery. On the first postoperative day, the intracameral air injection that had been injected at the end of the surgery had travelled back into the posterior chamber between the iris and the lens which was pushing the iris from one side and causing the AC to become irregular. There was mild striate keratopathy which can be associated with UZS<sup>6</sup> but the AC details were clear. After one week, the patient had developed fixed, dilated pupil with raised IOP which was not responding to pilocarpine 2% eye drops or any IOP-lowering medication. After taking these signs into account, a diagnosis of UZS was made.

A few cases of UZS have been reported following deep anterior lamellar keratoplasty (DALK) which is a type of keratoplasty, following intracameral air injection.<sup>7</sup> This air injection/tampade may be associated with causing pupillary block, raised IOP, iris ischemia, and fixed dilated pupil.<sup>7</sup> Intracameral air is injected commonly in almost all cases of PKP and yet UZS is seen in 2.2-17.7% of cases. We believe that the posterior movement

of the intracameral air bubble caused the iris to push forward coupled with instillation of one drop of topical mydriatic cyclopentolate 0.5% given on the first postoperative day to facilitate the passage of air bubbles into the AC caused UZS.

We performed a therapeutic synechiolysis which significantly reduced the IOP. In one case of glaucoma, argon laser iridoplasty was done to break PAS<sup>8</sup> but we went for surgical synechiolysis instead.

Some reports in the literature have suggested the use of dapiprazole and guanethidine drops, which are sympatholytic agents. They were suggested as a measure to cope with the hypertony of the sympathetic system of the iris and to induce miosis after UZS has occurred.<sup>1</sup>

One report demonstrated that guanethidine in combination with pilocarpine treated iris sympathetic spasm and induced miosis but many other reports showed no benefit of either of them.<sup>1</sup>

In another case report, it was discovered that few preoperative considerations such as minimal intraoperative iris manoeuvring and prophylactic peripheral iridectomy (to prevent pupillary block) could have been the likely contributing manoeuvres towards reversal of UZS in the case of DMEK.<sup>9</sup>

Spadea *et al.* similarly reported regression of pupillary dilatation in a young patient following DALK, but a short course of sympatholytic (dapiprazole 0.5%) and parasympathomimetic (pilocarpine 2%) were required.<sup>10</sup>

In order to improve comfort and glare following UZS, a single-pass four-throw pupilloplasty (SFT) is also an option<sup>11</sup> but our patient denied this procedure as he had no complaints regarding glare, haloes or photophobia since he was using dark glasses during the day and was comfortable with them. SFT is an effective technique to create a pupil and decrease glare and photophobia. Moreover, synechiolysis is a temporary relief for angle closure as PAS can recur. SFT keeps the iris taut so the chances of recurrence of angle closure as also seen in UZS are decreased.<sup>12</sup>

In conclusion, this case highlights the significance of close monitoring with prompt surgical management to prevent sight-threatening complications associated with UZS following PKP.

### PATIENT'S CONSENT:

Informed consent was taken from the patient and his attendant regarding the use of his clinical information and photographs for academic and publication purposes.

### COMPETING INTEREST:

The authors declared no competing interest.

### AUTHORS' CONTRIBUTION:

MSA: Conception, drafting, and data collection of the manuscript.

KKS: Data interpretation and critical revision/analysis of the article.

AM: Data analysis.

MAA: Design of the study.

All authors approved the final version of the manuscript to be published.

## REFERENCES

1. EyeWiki. Urrets-Zavalía Syndrome [Internet]. Available from: [http://eyewiki.aao.org/Urrets-Zavalía\\_Syndrome](http://eyewiki.aao.org/Urrets-Zavalía_Syndrome). (Accessed on 9/30/2023).
2. Wang P, Gao Q, Su G, Wang W, Xu L, Li G. Risk factors of Urrets-Zavalía Syndrome after penetrating keratoplasty. *J Clin Med* 2022; **11(5)**:1175. doi:10.3390/jcm1105117.
3. Uribe LE. Fixed pupil following keratoplasty evaluation of six cases. *Am J Ophthalmol* 1967; **63(6)**:1682-6. doi: 10.1016/0002-9394(67)93647-1.
4. Spierer O, Lazar M. Urrets-Zavalía Syndrome (fixed and dilated pupil following penetrating keratoplasty for keratoconus) and its variants. *Surv Ophthalmol* 2014; **59**:304-10. doi:10.1016/j.survophthal.2013.12.002.
5. Srinivasan M, Patnaik L. Fixed dilated pupil (Urrets-Zavalía Syndrome) in corneal dystrophies. *Cornea* 2004; **23**:81-3. doi:10.1097/00003226-200401000-00014.
6. Singh P, Tripathy K. Keratopathy [Internet]. In: StatPearls. Treasure Island (FL): StatPearls Publishing; 2023 February 22.
7. Foroutan A, Tabatabaei SA, Soleimani M, Nekoozadeh S. Urrets-Zavalía Syndrome in different methods of keratoplasty. *Int J Ophthalmol* 2016; **9**:1358-60. doi:10.18240/ijo.2016.09.22.
8. Shokoohi-Rad S, Gholamhoseinpour-Omran S, Hosseini-khah-Manshadi H, Baghi Yazdi M. Argon laser synechiolysis for irido-corneal adhesion. *Case Rep Ophthalmol Med* 2022; 5289203. doi:10.1155/2022/5289203.
9. Ang M, Sng CCA. Descemet membrane endothelial keratoplasty and glaucoma. *Curr Opin Ophthalmol* 2018; **29(2)**:178-84. doi: 10.1097/ICU.0000000000000454.
10. Spadea L, Viola M, Viola G. Regression of urrets-zavalía syndrome after deep lamellar keratoplasty for keratoconus: A case study. *Open Ophthalmol J* 2008; **2**:130-1. doi: 10.2174/1874364100802010130.
11. Narang P, Agarwal A, Ashok Kumar D. Single-pass four-throw pupilloplasty for Urrets-Zavalía syndrome. *Eur J Ophthalmol* 2018; **28**:552-8. doi:10.1177/1120672117747038.
12. Griffin JS. Single-pass four-throw pupilloplasty: A treatment for angle-closure glaucoma? [Internet]. American Academy of Ophthalmology; Clinical Update; 2019.

