

# Clinicopathological Features of Patients with Anti-NMDA Receptor Encephalitis: Experience from a Tertiary Care Centre in Pakistan

Muhammad Zain Arshad<sup>1</sup>, Dawood Ahmad<sup>1</sup>, Muhammad Hussain<sup>1</sup>, Muhammad Omair Riaz<sup>1</sup> and Ayesha Tanveer<sup>2</sup>

<sup>1</sup>Department of Immunology, Armed Forces Institute of Pathology, Rawalpindi, Pakistan

<sup>2</sup>Department of Radiology, Combined Military Hospital, Rawalpindi, Pakistan

## ABSTRACT

Anti-N-Methyl-D-Aspartate Receptor (NMDAR) antibody encephalitis is a potentially lethal form of autoimmune encephalitis in which auto-antibody production occurs against the NMDAR, NR1 subunit, causing massive dysregulation of neuro-transmission. This syndrome is often paraneoplastic (ovarian teratomas) having a male-to-female ratio of 1:4 and most often manifests with neuropsychiatric signs and symptoms, including hallucinations, memory loss, and diminished consciousness level leading to death. Immunotherapy and surgical removal of the predisposing malignancy often result in prompt relief of symptoms. We hereby present clinicopathological features and management outcomes of three cases of anti-NMDAR encephalitis (2 females and 1 male). All three patients had a prodrome of fever, abnormal psychiatric behaviour, decreased consciousness level, speech dysfunction, and autonomic instability; however, seizures and movement disorders were only present in two patients.

**Key Words:** Anti-NMDAR antibody, Anti-NMDAR encephalitis, Autoimmune encephalitis.

**How to cite this article:** Arshad MZ, Ahmad D, Hussain M, Riaz MO, Tanveer A. Clinicopathological Features of Patients with Anti-NMDA Receptor Encephalitis: Experience from a Tertiary Care Centre in Pakistan. *JCPSP Case Rep* 2023; **1**:50-52.

## INTRODUCTION

Autoimmune diseases of the nervous system are included in the category of organ-specific autoimmune disorders. Anti-N-Methyl-D-Aspartate Receptor (NMDAR) antibody encephalitis is a potentially fatal type of autoimmune encephalitis. It was first described in 2007. The antibody is produced against NMDAR (NR1 subunit) causing profound dysregulation of neurotransmission due to synaptic dysfunction and receptor internalisation leading to complex neuropsychiatric manifestations. To facilitate timely diagnosis, an international consortium suggested diagnostic criteria for autoimmune encephalitis in 2016. This disease is often paraneoplastic (associated with ovarian teratomas) and patients most often present with neuropsychiatric manifestations including confusion, anxiety, mood disturbances, self-harming behaviours, hallucinations, paranoia, memory loss, diminished alertness, mania, and seizures.<sup>1,2</sup>

Anti-NMDAR encephalitis preferably affects children and young adults. Women are disproportionately affected, having a male-to-female ratio of 1:4. On the basis of clinical suspicion, brain magnetic resonance imaging (MRI) and electroencephalogram (EEG) are helpful. Cerebrospinal fluid (CSF) analysis and positivity for autoantibody in the serum or CSF is used to confirm the diagnosis. Surgical resection of the culprit malignancy when indicated and immunotherapy often results in the rapid resolution of signs and symptoms.<sup>2,3</sup>

Anti-NMDAR encephalitis is a very rare diagnosis and scarcely described in the literature with just a few hundred cases reported worldwide. Due to variable initial symptoms and differential diagnoses (viral encephalitis and other causes of autoimmune encephalitis), it is not only underdiagnosed but can also be misdiagnosed. Limited data is available on differences in patient characteristics arising due to socioeconomic, regional, or genetic variations. This study presents clinicopathological features and outcomes of three patients with antibody-proven anti-NMDAR encephalitis in order to facilitate clinicians in timely diagnosis and prompt management of this rare yet curable debilitating illness.

## CASE REPORT

Ethical approval for this descriptive observational study was taken from the Institutional Review Board of the Armed Forces Institute of Pathology (AFIP), Rawalpindi (IRB/21/1591). Written informed consent for gathering pertinent information was taken from the patients and their relatives.

Correspondence to: Dr. Muhammad Zain Arshad, Department of Immunology, Armed Forces Institute of Pathology, Rawalpindi, Pakistan

E-mail: zidanearshad103@gmail.com

Received: February 18, 2023; Revised: June 04, 2023;

Accepted: June 14, 2023

DOI: <https://doi.org/10.29271/jcpspcr.2023.50>

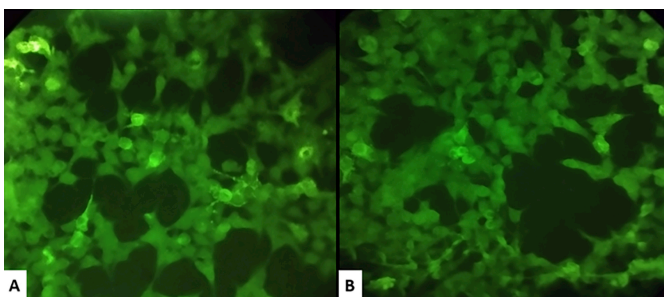
**Table I: Clinicopathological characteristics of patients (n = 3).**

Parameters	Case 1	Case 2	Case 3
Onset of disease	27 years and 6 months	7 years	30 years
Diagnostic delay	6 months	14 days	4 years
Prodromal symptoms	Fever (104°F)	Fever	Fever (100°F) and Headache
Gap after prodrome	Within 1 month	Within 1 month	Within 1 month
Presenting complaint	Speech dysfunction	Decreased level of consciousness	Seizures
Clinical characteristic			
Abnormal (psychiatric) behaviour	Present (Hallucinations)	Present (Confusion)	Present (Mood disturbance)
Speech dysfunction	Present (Slurring)	Present (Slurring)	Present (Slurring)
Seizures	Absent	Present	Present
Movement disorders	Absent	Present (Chorea)	Present (Chorea)
Decreased level of consciousness	Present	Present	Present
Autonomic dysfunction	Present (Labile blood pressure)	Present (Urinary incontinence)	Present (Urinary incontinence)
Total characteristics	4	6	6
MRI findings (CNS)	Hyper-intensity lesions	Hyper-intensity lesions	Unremarkable
Course of disease	Monophasic	Monophasic	Monophasic
Autoimmune diseases	No	No	No
History of ovarian tumour	-	No	No (Normal PET Scan)
Co-morbids	No	No	No
Vaccination status			
EPI	Vaccinated	Vaccinated	Vaccinated
COVID-19	Vaccinated	Vaccinated	Vaccinated
Flu	Unvaccinated	Unvaccinated	Unvaccinated
Current status	Symptomatic	Dead	Symptomatic
Treatment status	Undertreatment	-	Undertreatment

MRI, magnetic resonance imaging; EPI, expanded programme of immunization; COVID-19, novel coronavirus disease 2019.

**Table II: Demographic and immunological characteristics of patients (n = 3).**

Parameters	Case 1	Case 2	Case 3
Age	28 years	7 years	30 years
Gender	Male	Female	Female
Anti-NMDAR antibody			
Time of testing	Attack	Attack	Attack
Specimen	CSF	CSF	Serum
Result	Positive	Positive	Positive
Intensity	(+)	(+)	(+)



**Figure 1: Anti-NMDA Receptor Antibodies on Indirect Immunofluorescence at 200×Magnification using slides with BIOCHIPS having attached Transfected Cell Line expressing the Major Target Antigen (receptor subunit NR1).**

Clinical information was noted by reviewing the patient's medical documents, and laboratory reports and by interviewing patients (after recovery) as mentioned in Tables I and II. Specimens for antibody testing were received in the Department of Immunology, AFIP. The data of patients found positive for autoantibodies was collected from June 2021 to December 2022. Patients with clinical suspicion of autoimmune encephalitis who tested positive for anti-NMDAR antibodies in serum or CSF were included in the study. A total of six cases were found. Among these, three cases are presented here in this report. Three anti-NMDAR antibody-positive patients were not included in the present study because of insufficient history.

All specimens (serum or CSF) were tested for anti-glutamate (NMDAR type) receptor antibodies (IgG) by indirect immunofluorescence (IIF), using transfected cells (EU 90) that were fixed on slides (prepared by Euroimmun Medizinische Labor-diagnostika AG, Lubeck, Germany). Slides were incubated with the patient's specimens (serum diluted at 1:10) or CSF (undiluted) and subsequently stained with fluorescein isothiocyanate (FITC) labelled anti-human IgG antibodies and analysed using a fluorescence microscope, BA-310. Samples were labelled as positive if they produced a typical fine granular cytoplasmic fluorescence with cellular protrusions in the transfected cells similar to positive control sera provided in the kit and also compared to the absence of staining in non-transfected cells (Figure 1). Observations were noted in pre-designed detailed proforma.

Out of 278 patients having clinical suspicion of autoimmune encephalitis within the study period, our data showed a 2.15 % positivity with 6 patients who were found positive for anti-NMDAR IgG antibodies (female-to-male ratio, 1:1). Patients included in the present case series were two females and one male. A wide spectrum of clinical manifestations was observed (Table I). A prodrome of fever, abnormal psychiatric symptoms, speech problems, decreased consciousness level, and autonomic instability were present in all three patients. Seizures and movement disorders were also noted

in two patients. All patients showed a monophasic course and when tested during the attack phase showed (+) intensity of immunofluorescence.

## DISCUSSION

Early recognition, neoplastic workup, and immunotherapy are the main steps of management in anti-NMDAR encephalitis. Delays are dangerous as approximately 1 out of 4 patients end up with severe neuropsychiatric manifestations or death even with relevant management.<sup>1</sup> In the present case report, one patient, a seven-year-old female out of total 6 antibody-proven cases, died within 14 days of onset of symptoms. Anti-NMDAR encephalitis preferably affects young adults and children (from 2 months) with a male-to-female ratio of 1:4.<sup>3</sup> Roughly 50% of females above 18 years and 9% of girls below 14 years have ovarian neoplasms; however, in males association with tumour is rare.<sup>3</sup> Among all six antibody-proven cases in the present study, the male-to-female ratio was 1:1. Sheikh *et al.* in their study found 4% positivity for anti-NMDAR antibodies with 12 patients found positive and the mean age was 15±10.9 years (range: 1 to 28 years).<sup>4</sup> In the present study, positivity for anti-NMDAR antibody (n=6) was 2.15% with the mean age of diagnosis being 27 years (range: 1 to 63 years). Zubair *et al.* in their study presented a case of a 14-year female with complaints of irritability, abnormal movements, altered behaviour, decreased sleep, self-biting, drowsiness, and subsequently immobility.<sup>5</sup> According to the present study, all three patients had a prodrome of fever, abnormal psychiatric behaviour, decreased consciousness level, speech dysfunction, and autonomic instability; however, seizures and movement disorders were only present in two patients. According to Haq *et al.*, the majority of patients (12/17) with anti-NMDAR encephalitis suffered from seizures. Orofacial dyskinesia was observed in 12 patients and 12 patients had autonomic disturbance. Among them, six patients were less than 12 years of age.<sup>6</sup> In the present study, autonomic dysfunction was present in all three cases; however, seizures and movement disorder were present in two cases.

A high index of suspicion should be kept for anti-NMDAR encephalitis in young patients presenting with a prodrome of fever along with neuropsychiatric symptoms. Timely diagnosis based on clinical suspicion along with immunological

workup during the attack phase leading to prompt management is the key to success.

### PATIENTS' CONSENT:

Written informed consent for gathering pertinent information was taken from the patients and their relatives.

### COMPETING INTEREST:

The authors declared no competing interest.

### AUTHORS' CONTRIBUTION:

MZA: Conception of work, analysis and interpretation of data.

DA: Revision and proofreading of the manuscript.

MH, MOR: Drafting of work and critical revision.

AT: Data acquisition and analysis.

All the authors have approved the final version of the manuscript to be published.

## REFERENCES

1. Bhat P, Ahmed A, Jolepalem P, Sittambalam C. A case report: Anti-NMDA receptor encephalitis. *J Community Hosp Intern Med Perspect* 2018; **8(3)**:158-60. doi: 10.1080/20009666.2018.1481326.
2. Ceanga M, Chung H-Y, Geis C. Anti-NMDA receptor encephalitis: Epidemiological differences and common challenges. *Ann Transl Med* 2020; **8(11)**:716. doi: 10.21037/atm.2020.02.34.
3. Steeman A, Andriescu I, Sporcq C, Mathieu D, Meurant V, Mazairac G. Case report of anti-NMDA receptor encephalitis in a 24-year-old female: An uncommon presentation. *Egypt J Neurol Psychiatr Neurosur* 2022; **58(1)**:79. doi: 10.1186/s41983-022-00512-7.
4. Sheikh S, Ahmad A, Ahmed TA. Anti NMDA receptor antibody encephalitis in Pakistan: Clinicopathological features and treatment outcomes. *J Pak Med Assoc* 2019; **69(12)**:1910-4. doi: 10.5455/JPMA.300185.
5. Zubair UB, Majid H. Anti-NMDA receptor encephalitis in a young girl with altered behaviour and abnormal movements. *J Coll Phys Surg Pak* 2018; **28(8)**:643. doi: 10.29271/jcpsp.2018.08.643.
6. Haq AU, Nabi D, Alam M, Ullah SA. The spectrum of movement disorders in anti-n-methyl-d-aspartate receptor (NMDAR) encephalitis both in children and adults: An experience from a single tertiary care centre. *Cureus* 2021; **13(12)**:e20376. doi: 10.7759/cureus.20376.

