

# A Rare Presentation of Omental Cyst as Inguinal Hernia in A 10-Month Boy: A Case Report

Maliha Nadeem, Sajid Iqbal Nayyar, Hamza Malik, Imran Hashim and Nabila Talat

*Department of Paediatric Surgery, The Children Hospital, University of Child Health Sciences, Lahore, Pakistan*

## ABSTRACT

An omental cyst is a benign proliferation of lymphatic tissue. Its wall lacks smooth muscle and lymphatic spaces. It usually arises from the greater or lesser omentum. The classical presentation is partial intestinal obstruction combined with a palpable, freely movable abdominal mass. The omental cyst presenting as bilateral inguinal hernia is a very rare occurrence. It is diagnosed based on history, examination, and imaging. The omental cyst is mobile in both the transverse to craniocaudal directions. The diagnosis of an omental cyst is confirmed on ultrasonography and computerised tomography; these two investigations have eliminated the need for contrast studies. Here, we present a case of a 10-month child who presented with bilateral inguinoscrotal swellings in the outpatient department. The exploration showed a large omental cyst presenting as bilateral indirect inguinal hernia. The cyst was excised, and bilateral herniotomy was performed.

**Key Words:** *Omental cyst, Inguinal hernia, Herniotomy.*

**How to cite this article:** Nadeem M, Nayyar SI, Malik H, Hashim I, Talat N. A Rare Presentation of Omental Cyst as Inguinal Hernia in A 10-Month Boy: A Case Report. *JCPSP Case Rep* 2024; **2**:99-101.

## INTRODUCTION

Omental and mesenteric cysts are rare intra-abdominal pathologies with an incidence of 1 in 20,000 in infants and 1 in 105,000 to 140,000 in adults with hospital admissions. Among these, only 2.2% constitute omental cysts.<sup>1,2</sup> In Japan, omental cysts are more common in males, whereas in the rest of the world, the male-to-female ratio is 1:1.2. These are mostly asymptomatic or present with painless abdominal masses. Larger cysts can also present with acute abdomen due to rupture, haemorrhage, or torsion.<sup>3</sup> It is very rare for mesenteric or omental cysts to present as inguinoscrotal swellings. Gurer *et al.* reported mesenteric cysts as contents in the hernial sac.<sup>4</sup> Similarly, Obaidah *et al.* also found mesenteric cysts in inguinal hernias.<sup>5</sup> Preoperative diagnosis is difficult due to the rarity of the condition. In the index case, the omental cyst presented as bilateral inguinoscrotal swellings.

## CASE REPORT

A 10-month male child presented in the outpatient department with bilateral huge inguinoscrotal swellings. There was no history of vomiting, abdominal pain, abdominal distension, or constipation.

*Correspondence to: Dr. Sajid Iqbal Nayyar, Department of Paediatric Surgery, The Children Hospital, University of Child Health Sciences, Lahore, Pakistan*  
*E-mail: sajidnayyar@gmail.com*

*Received: December 18, 2023; Revised: February 06, 2024;*

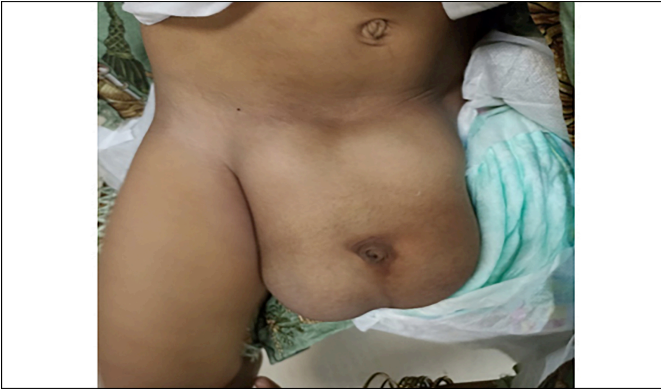*Accepted: March 17, 2024*

*DOI: <https://doi.org/10.29271/jcpspcr.2024.99>*

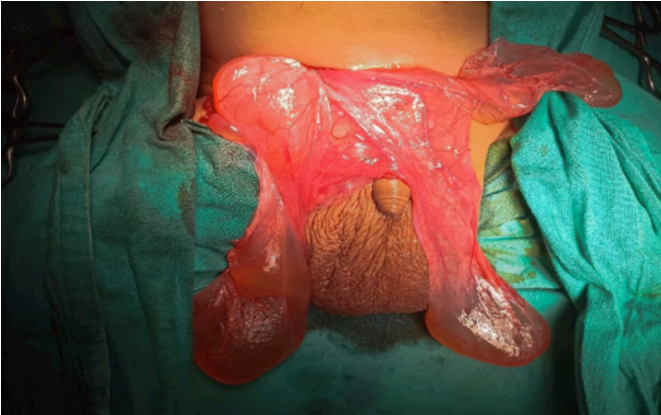On examination, bilateral swellings were soft, non-tender, reducible, and cystic in consistency. The trans-illumination test was positive on both sides (Figure 1). Ultrasonography showed a left-sided multiloculated hydrocele with internal echoes and a right-sided inguinal hernia containing gut loops. The patient was put on the elective list for bilateral herniotomy. A standard right lower abdomen skin crease incision was made, and the inguinal canal was opened. The sac was identified, but the hernial contents were not completely reduced, so the sac was carefully opened. On opening the sac, a huge multiloculated cyst containing clear fluid was encountered (Figure 2). As we were unable to reach the base of the cyst for complete excision, a right infraumbilical transverse incision was made. An irregular cystic lesion of 18x12x12 cm arising from the greater omentum, occupying the whole abdomen and both scrotal sacs, was found (Figure 3). Around 1 liter of serous fluid was drained. After complete excision of the cyst, bilateral herniotomies were done. The patient's postoperative course was uneventful, and he was discharged on the 3<sup>rd</sup> postoperative day. Histopathology showed a fibrous cyst wall and a few dilated vascular channels suggestive of cystic lymphangioma (Figure 4).

## DISCUSSION

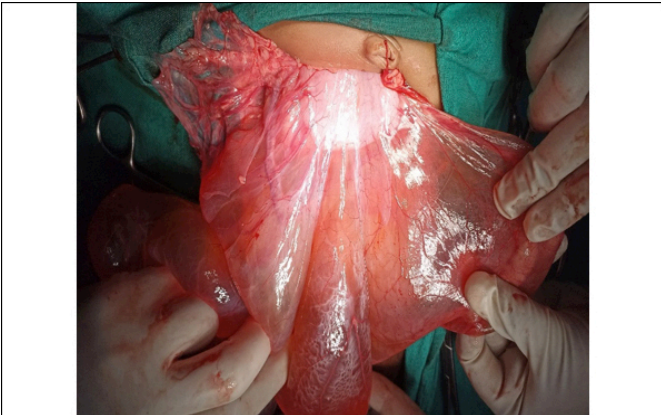Inguinal hernia is a common diagnosis in children. It is more common in males, and most cases (90%) present on the right side. Mostly, the hernial sac is empty or may contain the bowel, omentum, and ovaries. Rarely found contents reported in the literature include the appendix, urinary bladder, and fallopian tubes. However, it is extremely rare to see omental or mesenteric cysts in the inguinal hernia sac. Moreover, the presence of a single cyst in bilateral hernial sacs is even rarer.



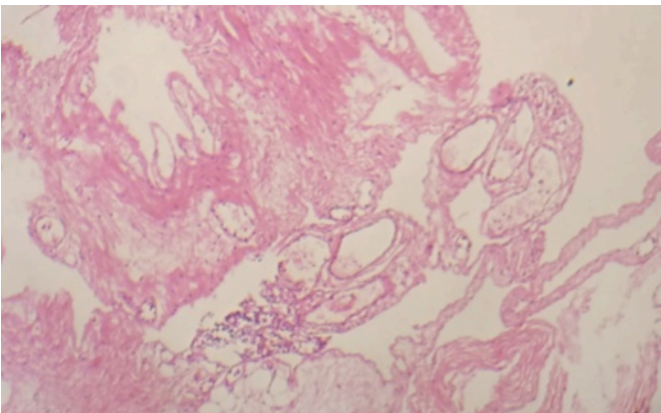
**Figure 1: A 10-month child with bilateral inguinoscrotal swelling.**



**Figure 2: Omental cyst removed from bilateral inguinal sacs.**



**Figure 3: Huge omental cyst arising from the greater omentum.**



**Figure 4: Histopathology showing endothelial lining of the cyst wall.**

Omental cysts may arise from the greater or lesser omentum. They can be single or multiple, unilocular or multilocular, and may contain serous, chylous, haemorrhagic, or infected fluid. On examination, omental cysts are usually freely mobile and compressible. They can have a variable presentation. Smaller cysts are usually asymptomatic; however, larger cysts may present as a painless abdominal mass. A few patients present with acute abdomen due to volvulus, obstruction, rupture, infection, torsion, or haemorrhage in the cyst. Very rarely, omental cysts can present as inguinoscrotal swelling. In the index case, the omental cyst presented with bilateral inguinal hernia, which is an extremely rare presentation.

Very few cases of such occurrence have been reported in the literature. Obaidah *et al.* reported an omental cyst in the left inguinal hernia.<sup>5</sup> Popli *et al.* found retroperitoneal lymphangioma as the content of the right hernial sac.<sup>6</sup>

Mostly the hernial swellings containing abdominal cysts are trans-illuminant. The diagnosis may be confused with hydrocele. Ultrasound is a good modality for diagnosis. CT scan is helpful in determining the type, size, and origin of the cyst. Contrast enhanced CT (CECT) is superior to CT providing more information regarding the extent, location, and nature of the cyst. Correct preoperative diagnosis of omental cyst is only reported in 13-25% of cases.<sup>7</sup>

If the diagnosis is made preoperatively, then complete surgical excision of the cyst along with ligation of the hernial sac is the treatment of choice. For larger cysts extending to the retroperitoneum, marsupialisation, aspiration, and debulking have been tried but the recurrence rate is very high. Excision can be done both by open surgery or laparoscopically.<sup>7</sup> First surgical excision was done by Tillaux in 1880 and marsupialisation was done by Pean.<sup>3</sup> Non-surgical management consists of a reduction in size due to the establishment of new drainage channels but complete resolution never occurs. Once diagnosed, surgical excision should be done to avoid haemorrhage, volvulus, torsion, or rupture of the cyst.

Omental cyst presenting as bilateral inguinal swellings is extremely rare in children. In children with trans-illuminant inguinoscrotal swelling, detailed abdominal examination should be performed to rule out omental or mesenteric cysts in the hernial sac.

**PATIENT'S CONSENT:**

Informed consent was taken from the patient's parents.

**COMPETING INTEREST:**

The authors declared no conflict of interest.

**AUTHORS' CONTRIBUTION:**

MN: Manuscript writing and designing.

SIN: Operating surgeon, manuscript writing and designing.

HM: Manuscript writing and editing.

IH, NT: Manuscript editing, critical analysis, and literature review.

All authors approved the final version of the manuscript to be published.

## REFERENCES

1. Motie MR, Asadi M. Large omental cyst: A case report and review of the literature. *Acta Med Iran* 2011; **49(10)**:690-3.
2. Maranna H, Bains L, Lal P, Bhatia R, Beg MY, Kumar P, Mallya V. Cystic lymphangioma of the greater omentum: A case of partial spontaneous regression and review of the literature. *Case Rep Surg* 2020; **2020**:8932017. doi: 10.1155/2020/8932017.
3. Tripathy PK, Jena PK, Pattnaik K. Management outcomes of mesenteric cysts in paediatric age group. *Afr J Paediatr Surg* 2022; **19(1)**:32-5. doi: 10.4103/ajps.AJPS\_158\_20.
4. Gurer A, Ozdogan M, Ozlem N, Yildirim A, Kulacoglu H, Aydin R. Uncommon content in groin hernia sac. *Hernia* 2006; **10(2)**:152-5. doi: 10.1007/s10029-005-0036-4.
5. Obaidah A, Mane SB, Dhende N, Acharya H, Thakur A, Arlikar J, Reddy S. Mesenteric cyst- an unusual presentation as inguinal hernia. *Indian J Surg* 2012; **74(2)**:184-5. doi: 10.1007/s12262-011-0247-0.
6. Popli MB, Garg DP, Anand R, Jain M, Jain N, Mahajan R. Retroperitoneal lymphangioma presenting as an inguinal hernia. *Indian Pediatr* 1994; **31(12)**:1573-5.
7. Hancock BJ, St-Vil D, Luks FI, Di Lorenzo M, Blanchard H. Complications of lymphangiomas in children. *J Pediatr Surg* 1992; **27(2)**:220-4. doi: 10.1016/0022-3468(92)90316-y.

•••••