

Retraction: Severe Cholestatic Jaundice Associated with Hyperthyroidism Treated with Methimazole

Xiaoqiang Liu, Boming Xu, Yilin Zeng, Peizhong Chen and Yubin Wang

Department of Gastroenterology, First Hospital of Quanzhou Affiliated to Fujian Medical University, Fujian, China

ABSTRACT

We present a case of a 43-year female patient with hyperthyroidism who developed severe jaundice. Although liver dysfunction is frequent in hyperthyroidism, jaundice is typically mild. In this case, the patient presented with severe jaundice, which could be a consequence of cholestasis induced by hyperthyroidism, as other potential causes such as drug-induced or autoimmune liver dysfunction were eliminated. The patient was treated with methimazole, which effectively ameliorated the severe cholestatic jaundice and restored normal thyroid function. However, the specific mechanism of cholestasis as a complication of hyperthyroidism remains unclear, and no particular biochemical markers for cholestasis caused by this hormonal disease could be identified. This case highlights that severe jaundice can be a clinical manifestation of hyperthyroidism. In such cases, antithyroid drug treatment may be an effective strategy for managing severe cholestatic jaundice.

Key Words: Hyperthyroidism, Liver dysfunction, Cholestatic jaundice.

How to cite this article: Liu X, Xu B, Zeng Y, Chen P, Wang Y. Retraction: Severe Cholestatic Jaundice Associated with Hyperthyroidism Treated with Methimazole. *JCPSP Case Rep* 2023; **1**:125-128.

INTRODUCTION

Hyperthyroidism, an endocrine disorder, is characterised by excessive thyroid hormone production, causing symptoms like tachycardia, sweating, weight loss, irritability, and anxiety.¹ Although liver dysfunction is frequent in hyperthyroidism, jaundice is typically mild. However, rare cases of hyperthyroidism accompanied by severe cholestatic jaundice have been reported.² This condition can lead to complications such as infections and malnutrition, significantly reducing the patient's quality of life. Here, we present a case of hyperthyroidism complicated by severe cholestatic jaundice and treated with methimazole (MMI), providing insights for managing similar complex cases.

CASE REPORT

A 43-year female patient was admitted to the Department of Gastroenterology with a history of heat intolerance and excessive sweating for 13 years, along with recent onset of icterus and yellow-coloured urine over the past week. She was diagnosed with hyperthyroidism 13 years back and was treated with MMI, which led to symptoms' improvement. She had irregular follow-up visits and stopped her medication several times (the specific treatment course was unclear).

One month before admission, the patient ceased her medication, subsequently experiencing palpitations and shortness of breath. She would become breathless after general physical activity or walking 100 meters, which could be relieved after rest. She also had oedema in both lower limbs. One week before admission, she developed icteric sclerae accompanied by dark urine, which gradually deepened to the colour of tea, and her appetite decreased.

Physical examination revealed a heart rate of 103 beats per minute, fatigue, protruding eyes, and yellow discolouration of the skin all over the body, but no liver palms, or spider nevi. The sclerae was yellow, the thyroid was Grade II, enlarged, tough in texture, with a smooth surface. No small nodules were palpated, no tenderness, and no vascular murmurs were heard. No rales were heard in the lungs. The heart rhythm was regular, the abdomen was normal on examination, and there was pitting oedema in both lower limbs.

Initial laboratory tests showed free triiodothyronine (FT3) of 19.36 ng/L (normal: 2.14~4.2 ng/L), free thyroxine (FT4), 5.95 ng/dL (normal: 0.59~1.25 ng/dL), thyroid stimulating hormone (TSH), 0.0008 uIU/ml (normal: 0.34~5.6 uIU/ml); anti-TSH receptor antibody (TRAb), 30.85 KIU/L (normal: 0~115 KIU/L), and thyroid peroxidase antibody (TPOAb), 239.5 KIU/L (normal: 0~34 KIU/L). Routine blood tests showed white blood cells of $6.30 \times 10^9/L$ (normal: $3.5 \sim 9.5 \times 10^9/L$), haemoglobin 113 g/L (normal: 115~150 g/L), and platelets, $130 \times 10^9/L$ (normal: $125 \sim 350 \times 10^9/L$). Liver function tests showed albumin, 28.4g/L (normal: 40~55 g/L), total bilirubin (TBil), 333.2 umol/L (normal: ≤ 23 umol/L), direct bilirubin, 181.0 umol/L (normal: ≤ 4 umol/L), indirect bilirubin, 152.2 umol/L (normal: ≤ 23 umol/L), Aspartate Aminotransferase (AST), 81 U/L (normal value 13~35 U/L),

Correspondence to: Dr. Yubin Wang, Department of Gastroenterology, First Hospital of Quanzhou Affiliated to Fujian Medical University, Fujian, China
E-mail: 690995298@qq.com

Received: July 16, 2023; Revised: September 23, 2023;

Accepted: November 02, 2023

DOI: <https://doi.org/10.29271/jcpspcr.2023.125>

Alanine Aminotransferase (ALT), 35 U/L (normal: 7~10 U/L), and Alkaline Phosphatase (ALP), 265 U/L (normal: 35~100U/L). Coagulation function tests showed prothrombin time, 23.5 seconds, international normalised ratio (INR), 2.07, partial thromboplastin time, 36 seconds, and D-dimer levels, 0.57 mg/L. B-type natriuretic peptide level was 968 pg/ml (normal: 0~100 pg/ml). The patient's serology for Hepatitis A, B, C, D, and E was negative, as were the antibodies for autoimmune liver disease. Tumour markers (Alpha-fetoprotein, Carcinoembryonic antigen [CEA], CA199, CA125, CA153) were all negative. EB virus and cytomegalovirus IgM were negative. The serum ceruloplasmin level was 0.5 g/L (normal: 0.2~0.6 g/L). Thyroid ultrasound suggested diffuse thyroid enlargement, and no nodularity. Echocardiogram showed ejection fraction (EF) of 74%, enlargement of the left atrium and right heart, widening of the pulmonary artery, marked tricuspid regurgitation, decreased left ventricular diastolic function (Grade III), and pulmonary hypertension (severe). Abdominal ultrasound suggested increased liver echogenicity and peritoneal effusion.

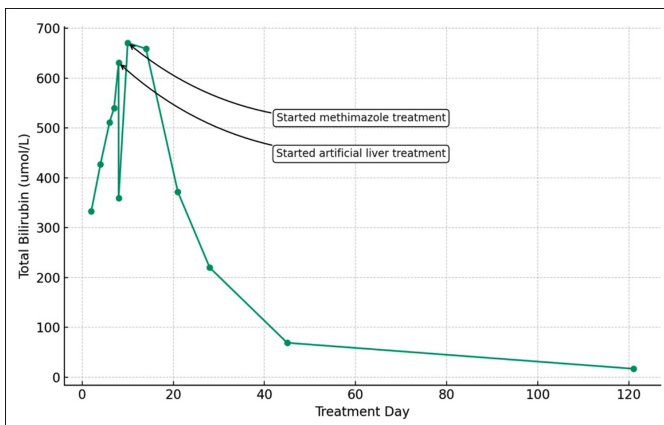


Figure 1: Total bilirubin level over the treatment period.

After excluding viral and drug-induced hepatitis, alcoholic, autoimmune, genetic metabolic, and other liver diseases, the diagnosis was made of (1) hyperthyroidism (2) hyperthyroid liver failure and (3) hyperthyroid heart disease. After admission, the patient was given supportive treatment in the form of transfusion of fresh plasma, albumin, supplementation of vitamins, anti-inflammatory treatment with methylprednisolone, and treatment with compound glycyrrhizic acid, adenosylmethionine for liver protection, jaundice reduction, and furosemide for diuresis. However, the condition did not improve. Her liver failure worsened, and the condition deteriorated (Figure 1). On the 8th day of hospitalisation, we had a full discussion with the patient's family and added artificial liver support treatment. The review of liver function was better than before, showing albumin of 34.5g/L, total bilirubin, 359.6 umol/L, direct bilirubin, 198.0 umol/L, indirect bilirubin, 161.6 umol/L, AST, 38 U/L, ALT, 23U/L, but the patient refused to continue artificial liver treatment due to financial limitations. MMI 10 mg bid was added orally on the 10th day of hospitalisation. The patient's coagulation functions improved significantly, and the review of liver functions on 14th day of hospitalisation was worse than before (Figure 1). The patient refused to continue inpatient

treatment and was discharged. After discharge, the patient continued to take MMI 10 mg bid orally, compound glycyrrhizic acid for liver protection, and anti-inflammatory treatment with methylprednisolone. One week after discharge, the review of liver functions suggested that bilirubin had significantly decreased. Three months after discharge, the patient was in good mental state with regular heart rhythm, normal liver functions, coagulation functions, thyroid functions and other indicators (Figures 1-3).

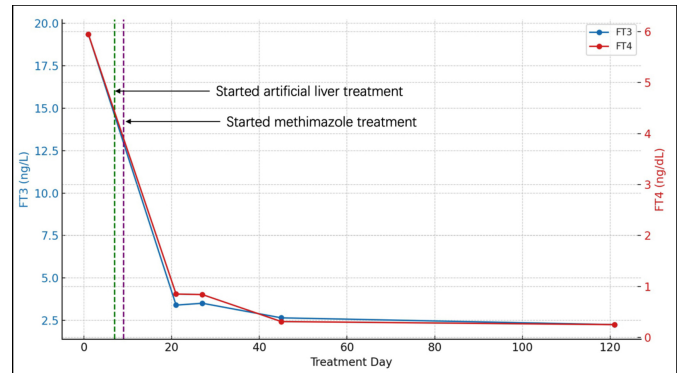


Figure 2: Free T3 (FT3) and free T4 (FT4) levels over the treatment period.

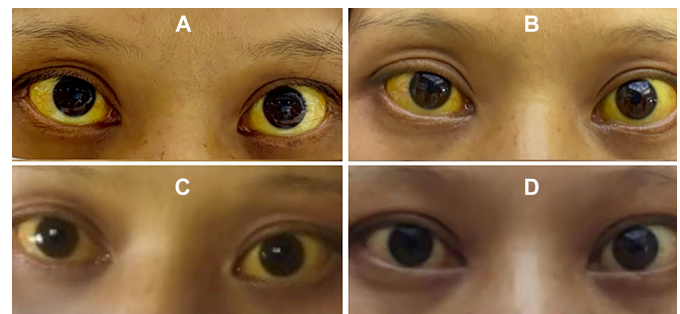


Figure 3: Changes in the scleral icterus during the course of treatment. (A) Illustrates the patient's scleral icterus on the 5th day of hospitalisation. (B) Represents the patient's scleral icterus on the 14th day of hospitalisation. (C) Shows the scleral icterus one week after discharge. (D) Depicts the scleral appearance one month after discharge.

DISCUSSION

Hyperthyroidism is a common endocrine disease, caused by excessive thyroid hormones in the circulation due to various diseases of the thyroid itself or outside the thyroid, leading to increased excitability and metabolism of various systems. Hyperthyroidism-induced liver injury is common in clinical practice. The incidence of hyperthyroid liver injury reported in the literature is 40 to 89%, and it is mostly of mild to moderate degree. Hyperthyroidism associated with severe jaundice is rarely reported.³ The present case focuses on the clinical characteristics and treatment strategy of hyperthyroidism-associated severe jaundice. The mechanism of hyperthyroidism-induced liver injury is not clear. The possible reasons include: (1) During hyperthyroidism, although cardiac output is increased, the blood supply to the liver is not correspondingly increased, which can lead to the liver being in a relatively ischemic and hypoxic state, causing liver injury; (2) Severe hyperthyroidism may cause right heart failure, which further exacerbates liver ischemia, hypoxia, and liver injury; (3) During the treatment of hyperthyroidism, the

use of antithyroid drugs (ATDs) may cause drug-induced liver injury (DILI), but the incidence is low. The literature reported that the incidence of ATD-induced liver injury is less than 0.5%, and most occur within the first 3 months of medication.³ This patient had a history of intermittent oral MMI for 13 years and had stopped the medication for more than one month, so DILI was not implicated.⁴ Some studies had shown that hyperthyroid liver injury may be related to the presence of high-titer TRABs and other autoantibodies in the body, and a strong autoimmune response.⁴ In general, hyperthyroidism can cause liver injury through multiple pathways, but the exact mechanism is not yet clear.

Early identification of hyperthyroid high-risk groups that may be complicated by liver injury is of great significance, which can reduce the risk of severe jaundice, liver failure, and death. Zhang *et al.* monitored the levels of phosphorus and Cysteine S-Glutathione Transferase (CSHI) in serum, liver, and kidney, and found that the levels of phosphate and CSHI in serum were negatively correlated with the degree of hyperthyroidism-induced liver injury, and the changes in phosphate and CSHI levels in liver and kidney tissues were positively correlated with the degree of hyperthyroidism-induced liver injury. They proposed that early detection of phosphate and CSHI levels in serum can effectively evaluate hyperthyroidism-induced liver injury.⁵ But using thyroid function, thyroid antibody levels and other indicators to identify high-risk groups of hyperthyroidism-induced liver injury are more feasible for clinicians. The literature showed that FT4 >75 pmol/L and TRAb >15 IU/L are independent predictors of hyperthyroidism-induced liver injury,⁶ reminding clinicians to pay attention to the possibility of liver injury in this group of hyperthyroidism. Another study found that age >45 years, heart rate >90 beats/minute, thyroid mass >35 g, duration of hyperthyroidism >3 years, FT4 \geq 70.5 pmol/L, TPOAb >360 IU/ml, and TRAb >15 IU/L are all risk factors for hyperthyroidism-induced liver injury.⁷

The clinical manifestations of hyperthyroidism-induced liver injury are varied. The three most common types are cholestasis, hepatocellular injury, and liver synthetic dysfunction. The liver injury is mostly mild to moderate, while severe liver injury is rare. Wafa *et al.* summarised the clinical data of 17 newly diagnosed and untreated patients with hyperthyroidism combined with liver injury, and found that the types of liver injury included cholestasis (88.2%), hepatocellular injury (41.2%) and synthetic dysfunction (29.4%). The incidence of severe liver injury was 11.8%, and the incidence of mild to moderate injury was 88.2%.⁸ Wang *et al.* observed 2385 cases of Graves' disease-related hyperthyroidism and found that the incidence of cholestasis type liver injury was 32.4%, while the incidence of severe liver injury was only 6.6%, among which severe liver injury was defined as: ALT or AST \geq 20 \times Upper Limit of Normal (ULN), Gamma-Glutamyl Transferase (GGT) \geq 10 \times ULN, Alkaline Phosphatase (ALP) \geq 5 \times ULN, and/or TBil \geq 5 \times ULN.⁹ At present, there are few comparative studies on severe liver injury and mild-to-moderate liver injury. The present patient also mainly manifested as cholestasis-type liver injury.

For the treatment of hyperthyroidism combined with severe jaundice, early and active control of hyperthyroidism is crucial to improve jaundice. However, treatment of such cases present great challenges. The treatment plan for hyperthyroidism often includes ATD,¹³¹Iodine treatment, and surgery. ATD itself has the risk of inducing DILI. Research found that propylthiouracil (PTU)-induced liver injury is mainly characterised by varying degrees of hepatocyte necrosis, while MMI is more likely to show intrahepatic cholestasis, both of which can manifest as increased bilirubin or transaminases, but the incidence of ATD-related DILI is low, ranging from 0.1 to 0.2%.¹⁰ At present, the risk factors for ATD-related DILI are not clear, and some literature reports that old age and larger drug doses may be risk factors for ATD-related DILI.⁸ Therefore, the clinicians often face the risk of aggravating liver injury in patients with hyperthyroidism and severe jaundice. Although the above considerations made us reluctant to use MMI to treat this patient, we believed that the severe cholestasis in this patient was caused by hyperthyroidism, and not DILI caused by MMI. Hence, we used MMI to treat the patient and she responded well to it.

The incidence of hyperthyroidism associated with severe jaundice and liver failure is low, and the treatment of such patients is difficult, challenging, and complex. In such cases, ATD treatment may be an effective strategy for managing both conditions.

COMPETING INTEREST:

The authors declared no competing interest.

PATIENT'S CONSENT:

The patient gave an explicit consent to publish the case.

AUTHORS' CONTRIBUTION:

XL: Writing the manuscript.

BX: Providing the case study.

YZ: Providing the patient's images.

PC: Creating figures and tables.

YW: Guiding the writing of the manuscript.

All authors approved the final version of the manuscript to be published.

REFERENCES

1. Wiersinga WM, Poppe KG, Effraimidis G. Hyperthyroidism: Aetiology, pathogenesis, diagnosis, management, complications, and prognosis. *Lancet Diabetes Endocrinol* 2023; **11(4)**:282-98. doi: 10.1016/S2213-8587(23)00005-0.
2. Lane LC, Wood CL, Cheetham T. Graves' disease: Moving forwards. *Arch Dis Child* 2023; **108(4)**:276-81. doi:10.1136/archdischild-2022-323905.
3. Piantanida E, Ippolito S, Gallo D. The interplay between thyroid and liver: Implications for clinical practice. *J Endocrinological Investigation* 2020; **43(7)**: 885-99.
4. He K, Hu Y, Xu X-H. Hepatic dysfunction related to thyrotropin receptor antibody in patients with graves' disease. *Experimental Clin Endocrinol Diabetes* 2014; **122(06)**: 368-72.

5. Zhang W, Wang X, Li P. Evaluating hyperthyroidism-induced liver injury based on *in situ* fluorescence imaging of glutathione and phosphate via nano-mofs sensor. *Analytical Chemistry* 2020; **92(13)**:8952-8.
6. Zhang R, Tian X, Qin L. Factors predicting abnormal liver function tests induced by graves' disease alone. *Medicine* 2015; **94(19)**: e839.
7. Li C, Tan J, Zhang G. Risk factors of hyperthyroidism with hepatic function injury: A 4-year retrospective study. *Hormone Metabolic Res* 2015; **47(03)**: 209-13.
8. Wafa B, Faten H, Mouna E. Hyperthyroidism and hepatic dysfunction: Report of 17 cases. *JGH Open* 2020; **4(5)**: 876-9. doi: 10.1002/jgh3.12337.
9. Wang R, Tan J, Zhang G. Risk factors of hepatic dysfunction in patients with Graves' hyperthyroidism and the efficacy of 131iodine treatment. *Med* 2017; **96(5)**:e6035.
10. Yang J, Li L, Xu Q. Analysis of 90 cases of antithyroid drug-induced severe hepatotoxicity over 13 years in China. *Thyroid* 2015; **25(3)**:278-83. doi: 10.1089/thy.2014.0350.

