

Child with Colonic Lithobezoar: A Rare Case Report from Pakistan

Mustajab Alam, Muhammad Zain Arshad, Muhammad Hussain, Muhammad Aftab Hassan and Maryam Bibi

Department of Immunology, Armed Forces Institute of Pathology (AFIP), Rawalpindi, Pakistan

ABSTRACT

Colonic lithobezoars, an uncommon subset of gastrointestinal foreign body impactions characterised by the accumulation of indigestible materials within the colon, typically present with symptoms of obstruction but are rarely reported in the medical literature. Diagnostic imaging modalities, such as x-rays and CT scans, play a crucial role in confirming the diagnosis. Initial treatment involves conservative measures like laxatives and hydration for uncomplicated (non-obstructed) cases with surgical intervention as ultimate option for dire circumstances. In this report, we present the incidental diagnosis of a colonic lithobezoar in a 5-year male child, highlighting the condition's extreme rarity and underscoring the need for heightened awareness and vigilance among the healthcare practitioners. The aim is to contribute to the limited knowledge regarding colonic lithobezoars, emphasising the importance of considering this diagnosis in patients with relevant clinical symptoms and risk factors, particularly in paediatric cases, where early recognition and management can significantly impact outcomes and prevent the potential complications.

Key Words: *Asymptomatic colonic bezoar, Colonic bezoar, Lithobezoar.*

How to cite this article: Alam M, Arshad MZ, Hussain M, Hassan MA, Bibi M. Child with Colonic Lithobezoar: A Rare Case Report from Pakistan. *JCPSP Case Rep* 2024; **2**:11-13.

INTRODUCTION

Colonic lithobezoar is an uncommon condition where non-food items, such as pebbles or stones, accumulate in the colon, often linked to behaviours like pica. It is a rare occurrence, with only a dozen cases documented in the medical literature.¹ Symptoms include abdominal pain, constipation, and possible bowel obstructions, and are typically diagnosed through x-rays or CT scans. The main cause is compulsive ingestion of non-food items. A prompt intervention is crucial to prevent complications like bowel perforation.² The treatment options range from medical approaches with laxatives and fluids to endoscopic or surgical removal. Early diagnosis and appropriate treatment generally lead to favourable outcomes, although underlying psychiatric conditions may influence long-term prognosis.³

CASE REPORT

A 5-year male child, the first born of unrelated parents, with a complete vaccination history and typical developmental milestones with no family history of psychiatric issues, presented at the emergency room with symptoms of vomiting, constipation, painful bowel movements, straining during defecation, and abdominal pain.

To investigate the cause of the abdominal pain, a plain abdominal x-ray and initial laboratory tests (Table I) were performed. The x-ray revealed numerous radiopaque irregular shadows resembling the characteristic "corn on the cob" appearance, from small intestine till rectum (Figure 1A). The laboratory investigations also unveiled a microcytic hypochromic blood profile, with reduced serum iron and ferritin level, coupled with raised total iron binding capacity. Upon comprehensive history taking from the caregivers, it was revealed that the child had been observed consuming stones (pica) on multiple occasions over the past couple of years, and no medical attention had been sought till the presentation.

On general physical examination, a pale child with a neutral facial expression exhibited normal vital signs. An abdominal assessment revealed slight tenderness upon deep palpation and a mild increase in bowel sounds. Upon conducting a digital rectal examination, stones were detected in the rectum. The diagnosis of colonic lithobezoar was established based on the relevant history, physical examination, and initial investigations.

The patient was admitted for conservative treatment, commencing with the administration of laxatives and parenteral fluids. This regimen facilitated the daily passage of stones in the patient's stools (Figure 1B). Within a few days, there was notable improvement in his condition, leading to his discharge on the fourth day of admission. He left the hospital with prescriptions for laxatives, multivitamins, iron supplements, and a follow-up plan that included daily appointments and serial x-rays over the next several days. Moreover, psychiatric evaluation was also advised. Subsequent follow-up visits showed significant clinical and radiological improvement (Figure 1, C and D).

Correspondence to: Dr. Muhammad Zain Arshad, Department of Immunology, Armed Forces Institute of Pathology (AFIP), Rawalpindi, Pakistan

E-mail: zidanearshad103@gmail.com

Received: September 30, 2023; Revised: December 22, 2023;

Accepted: December 30, 2023

DOI: <https://doi.org/10.29271/jcpspcr.2024.11>

Table I: Results of laboratory investigations including stone analysis.

Parameters	Result	Normal Range
Haemoglobin (Hb)	10.0 g/dl	13-17.0
Haematocrit (Hct)	35.5 %	36-54
Mean corpuscular volume (MCV)	58.6 fl	76-96
Mean corpuscular haemoglobin (MCH)	18 pg	27-33
Mean corpuscular haemoglobin concentration (MCHC)	30.7 g/dl	33-35
Red cell distribution width (RDW)	9.81%	11.5-33.5
Total leukocyte count (TLC)	10.6 × 10 ⁹ /l	4-11
Platelets	223 × 10 ⁹ /L	150-450
Serum iron	4.6 umol/l	8.5-28.9
Total iron-binding capacity (TIBC)	85 umol/l	43-80
Transferrin (Saturation)	39.2 %	19.7-36
Serum ferritin	6 ng/ml	7-140
Serum phosphate	1.3 mmol/l	0.9-1.5
Serum magnesium	2.1 mg/dl	1.7-2.55
Serum calcium	2.12 mmol/l	2.1-2.57
Results of stone analysis		
Calcium oxalate	50%	
Calcium phosphate	20%	
Magnesium ammonium sulphate	15%	
Uric acid	15%	

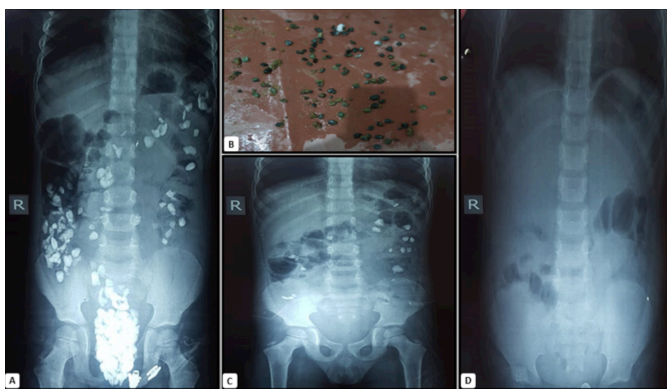


Figure 1: (A) Initial plain abdominal x-ray anteroposterior view showing numerous radiopaque densities in colon (lithobezoar) (B) Spontaneously passed lithobezoars (C) Follow-up plain abdominal x-rays anteroposterior view after a week showing significant improvement as compared to previous x-ray (D) Follow-up plain abdominal x-ray anteroposterior view after three weeks.

DISCUSSION

Bezoars exist in various forms and are categorised by their composition. These include trichobezoars (comprised of hair), phytobezoars (comprising fruit and vegetable particles), lactobezoars (accumulations of curd and milk), and rarer variations like metal bezoars (composed of metallic objects) or lithobezoars (consisting of stones). Numerous contributing factors lead to bezoar development, encompassing conditions like pica, behavioural issues in children, psychiatric disorders, intellectual disabilities, low socioeconomic status, parental neglect, and limited educational opportunities.⁴ Pica involves the consumption of non-nutritive materials and is associated with conditions like pregnancy, iron deficiency, and infancy.⁵ Typically, these materials accumulate in the stomach, resulting in symptoms such as feeding difficulties, fullness, vomiting, and abdominal discomfort. However, on rare occasions, these substances amass in the colon, giving rise to colonic bezoars charac-

terised by symptoms like constipation, painful bowel movements, straining during defecation, abdominal pain, and vomiting.

Clinical evaluation may uncover indications of abdominal obstruction, including tenderness, abdominal distension, palpable hard masses, and the distinctive “colonic crunch sign” during digital rectal examination.⁶ Colonic lithobezoar is exceedingly uncommon, with only a handful of documented cases in the medical literature, often presenting with obstructive symptoms. In this patient's case, the presence of the bezoar was discovered incidentally. Most reported cases show association with pica and frequently coincided with iron deficiency anaemia. Treatment usually entails the digital removal of stones under general anaesthesia (GA) to alleviate acute obstruction. However, the present case was managed conservatively, utilising fluids and laxatives, as immediate obstruction was not a concern. Many surgeons prefer the former approach due to its safety, speed, and minimal discomfort. Nevertheless, for stable and cooperative patients, a conservative strategy like laxatives and colonic lavage can be considered. Surgery should only be considered as a last resort for problematic cases when laxatives, manual, and colonoscopic decompression prove ineffective. In acute obstruction, surgery should be performed urgently to prevent a closed-loop obstruction. Additionally, iron deficiency, if present, should be addressed with oral and parenteral supplements.⁷

Colonic lithobezoar is a peculiar yet noteworthy condition, underscoring the necessity for a comprehensive approach involving gastroenterologists, surgeons, radiologists, pathologists, and mental health experts for effective diagnosis, treatment, and prevention. This condition should be considered in the evaluation of young children displaying pain abdomen or indications of bowel obstruction. Furthermore, primary care providers should assess mentally disabled children for pica

and bezoars during the routine care. Further exploration of the behavioural and psychological aspects of this condition is warranted to enhance patient outcomes.

PATIENT'S CONSENT:

Written, informed consent was taken from the parents of the patient to publish this case report.

COMPETING INTEREST:

The authors declared no conflict of interest.

AUTHORS' CONTRIBUTION:

MA: Conception and drafting of the work and interpretation of data.

MZA: Drafting of work, critically revision it and final approval.

MAH, MB, MH: Drafting of work and critical revision.

All authors approved the final version of the manuscript to be published.

REFERENCES

1. Alizai Q, Ullah F, Alam J, Aiman U, Ahmad T. A rare case of asymptomatic massive colonic lithobezoar in a young child. *Cureus* 2022; **14(9)**:e29538. doi: 10.7759/cureus.29538.

2. Chowksey S, Deshmukh S, Kalbande S. Lithobezoar: A case report. *Int Surg J* 2019; **7**:284. doi:10.18203/2349-2902.isj20195986.

3. Park SE, Ahn JY, Jung HY, Na S, Park SJ, Lim H, et al. Clinical outcomes associated with treatment modalities for gastrointestinal bezoars. *Gut liver* 2014; **8(4)**:400-7. doi: 10.5009/gnl.2014.8.4.400.

4. Iwamuro M, Okada H, Matsueda K, Inaba T, Kusumoto C, Imagawa A, et al. Review of the diagnosis and management of gastrointestinal bezoars. *World J Gastrointest Endosc* 2015; **7(4)**:336-45. doi: 10.4253/wjge.v7.i4.336.

5. Lesinskienė S, Stonkutė G, Sambaras R. Pica in childhood: Prevalence and developmental comorbidity. *Front Child and Adolescent Psychiatry* 2023; **2**. doi:10.3389/frcha.2023.1099527.

6. Aihole J. Colonic lithobezoar: Our experience in children. *J Paediatr Child Health* 2018; **54(9)**:1042-4. doi: 10.1111/jpc.14091.

7. Ibrahim OR, Lugga AS, Ibrahim N, Ibrahim LM, Suleiman BM. Iron-deficiency anemia with lithobezoar (pica): A rare cause of intestinal obstruction in a 5-year-old Nigerian child. *Int Med Case Rep J* 2018; **11**:225-8. doi: 10.2147/IMCRJ.S175653.

