

# Uncommon Presentation of Coffin-Siris Syndrome with Epilepsy Carrying *SMARCC2* Nonsense Mutation

Xiufeng Wang<sup>1</sup>, Lin Fu<sup>2</sup>, Yanling Zhang<sup>1</sup>, Ruixue Sun<sup>1</sup>, Yi-ling Liu<sup>3</sup> and Weixiao Liu<sup>1</sup>

<sup>1</sup>Department of Paediatrics, Xingtai People's Hospital, Hebei, China

<sup>2</sup>Department of Pathology, Xingtai People's Hospital, Hebei, China

<sup>3</sup>Department of Paediatrics, Renze District People's Hospital, Xingtai, Hebei, China

## ABSTRACT

Coffin-Siris syndrome (CSS) is a rare genetic disease. At present, there are no relevant guidelines or consensus reports on the diagnostic criteria for CSS. Due to its rarity, there is a high probability of underdiagnosis or misdiagnosis. Genetic testing based on next-generation sequencing (NGS) is of great help in assisting the diagnosis of CSS. Genes known to be associated with CSS include: *ARID1A*, *ARID1B*, *ARID2*, *DPF2*, *SMARCA4*, *SMARCB1*, *SMARCC2*, *SMARCE1*, *SOX11*, and *SOX4*. A 5-year child is reported here with CSS, epilepsy, unique facial features, no developmental and cognitive retardation, and generally normal language development. Whole exome sequencing revealed that the proband carried a *de novo* nonsense mutation in the *SMARCC2* gene (NM\_003075.5: exon5: c.415C>T, p.Arg139\*). On the basis of clinical features and NGS results, the child was finally diagnosed with CSS.

**Key Words:** Next-generation sequencing, Coffin-Siris syndrome, Epilepsy.

**How to cite this article:** Wang X, Fu L, Zhang Y, Sun R, Liu YL, Liu W. Uncommon Presentation of Coffin-Siris Syndrome with Epilepsy Carrying *SMARCC2* Nonsense Mutation. *JCPSP Case Rep* 2023; **1**:92-95.

## INTRODUCTION

Coffin-Siris syndrome (CSS) is a rare genetic disorder that is inherited in an autosomal dominant manner with no difference in the incidence in males and females.<sup>1</sup> CSS was first reported in 1970, and the typical clinical manifestations included varying degrees of growth retardation, mental retardation, hypotonia, hypoplasia of the fifth finger/toe, and typical characteristics in facial features (rough face, low front hairline, thick eyebrows, long eyelashes, flat nose bridge, wide nose tip, large mouth, thin upper lip, and thick lower lip). Some patients exhibit hirsutism or sparse hair, in addition to cardiac, gastrointestinal, genitourinary and/or central nervous system malformations, and may have feeding difficulties, ophthalmological diseases, hearing impairment, abnormal behaviour, and other symptoms.<sup>2</sup>

This case reports a child with epileptic seizures with unique facial features. Whole exome sequencing detected a new nonsense mutation in the *SMARCC2* gene (NM\_003075.5: exon5: c.415C>T, p.Arg139\*) on chromosome 12, which caused a truncation of the *SARCC2* translation protein, meeting the criteria for an American College of Medical Genetics and Genomics (ACMG) pathogenic variation.

## CASE REPORT

A 5 years and 11 months old boy was admitted to the hospital due to intermittent seizures. The seizures manifested in three forms: (1) Focal; (2) Generalised; and (3) Unknown onset. On oral administration of sodium valproate (maximum dose of about 36 mg/kg/d), the convulsions were not controlled. So lamotrigine was added, which reduced the amount of convulsions.

The child was a full-term baby at birth with a birth weight of 3.45 kg, unknown Apgar score, and no history of asphyxia and hypoxia. The mother was healthy during pregnancy. There was no poor feeding, jaundice, bleeding, etc. in the neonatal period. He achieved developmental milestones within normal time-frame. The language development was the same as normal children of the same age. From the age of 1 year to 5 years and 7 months, he had a history of 6 febrile convulsions with body temperature >38.5°C. These were generalised tonic-clonic seizures that lasted for 5-10 minutes and were relieved with medications. Family members complained that the child usually lacked concentration, had excessive activity, did not listen to instructions from the parents and teachers, and was prone to impulsivity. His mother had a history of febrile convulsions in early childhood.

Physical examination on admission revealed height of 120 cm (75<sup>th</sup> centile of normal height), weight of 21 kg (50<sup>th</sup> centile of normal weight), head circumference of 50 cm; slightly high eyebrow arches, thick eyebrows, hairy forehead, flat nose bridge, wide nose tip, thin upper lip, thick lower lip, and irregular dentition (Figure 1). No abnormalities in hearing and

Correspondence to: Dr. Xiufeng Wang, Department of Paediatrics, Xingtai People's Hospital, Hebei, China  
E-mail: wangxiufenglun@163.com

Received: February 28, 2023; Revised: August 09, 2023;

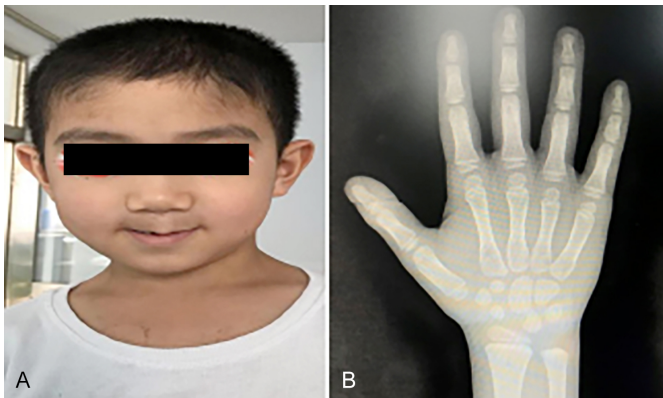
Accepted: August 22, 2023

DOI: <https://doi.org/10.29271/jcpspcr.2023.92>

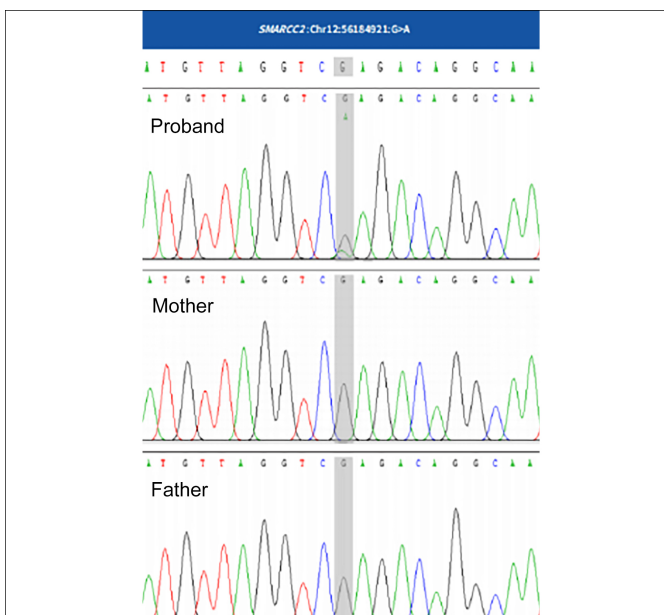vision, and no abnormalities in heart, lung, and abdominal examinations were noted. No positive signs were found in the nervous system examination. No deformity of the fifth finger/toe or spine was found. No pigmentation or depigmentation spots were found on the whole body skin.

According to the Chinese "Gesell Developmental Behaviour Assessment Scale for Children Aged 0-6" (a modified version of the Gesell Developmental Diagnosis Scale), the developmental age of the child was estimated to be approximately 69.6 months (actual age, 71 months), with developmental quotient/index of 89 for motor and fine motor development, an adaptive ability score of 97, language score of 110, and social behaviour score of 106. The video EEG results showed spike and spike slow wave discharges in the left central area and middle temporal area during the sleep period.

No abnormalities were found in the laboratory tests. The 24-hour Holter monitor was normal. Magnetic resonance imaging (MRI) of the head showed no abnormality.



**Figure 1: (A) The patient with a special face: rough face, low front hairline, thick eyebrows, long eyelashes, flat nose bridge, wide nose tip, large mouth, thin upper lip, and thick lower lip. (B) X-ray of hand. No deformity of the fifth finger is seen.**



**Figure 2: Sanger sequencing variation of the SMARCC2 gene mutation:**

**the c.415C>T (which presented another strand G>A).**

The whole exon group was sequenced due to the family history of epilepsy, unique facial features and convulsions in the child to clarify the aetiology of the disease. After the medical ethics review and the informed consent of the parents of the child, the peripheral blood of the child and his parents were collected and sent for whole-exome sequencing (Cipher Gene Ltd. Suzhou, China). The results showed that there was a *de novo* mutation in the SMARCC2 gene (NM\_003075.5: exon5: c.415C>T. p.Arg139\*) on chromosome 12, which had not been reported earlier (Figure 2). The mutation led to the stoppage of protein translation and affected the function of the protein. It was a low-frequency mutation in the normal population database.

The variation was analysed according to the "ACMG Classification Standards and Guidelines for Genetic Variations", and it was consistent with the "pathogenic Imposex": PVS1+PS2\_Moderate+PM2 Supporting. According to the rating rules of ACMG guidelines, the variation of c. 415C>T, p.Arg139\* of SMARCC2 gene was rated as "pathogenic Imposex that can explain the patient's phenotype" (PVS1+PS2+PM2). The phenotype of the parents of the child was normal, and the first generation sequencing of the parents' peripheral blood did not find the gene variation. It was thought that the new heterozygous Imposex was pathogenic. Based on the clinical manifestations, the child was finally diagnosed with CSS.

## DISCUSSION

At present, more than 200 cases of CSS have been diagnosed worldwide.<sup>3</sup> The syndrome is caused by mutations in several genes encoding components of the BRG1 and BRM-associated factor (BAF) complex (originally called the SWI/SNF-like complex). Studies have found that CSS is associated with abnormal changes in the SWI/SNF complex. The variations of genes encoding subunits of the BAF complex can cause CSS.<sup>4</sup> The genes related to the pathogenesis of CSS include ARID1A, ARID1B, ARID2, SMARCA4, SMARCB1, SMARCE1, DPF2, and their downstream regulatory genes SOX11 and PHF6. The frequency of ARID1B mutations is highest in CSS, accounting for 68-83%.<sup>5</sup> Several cases of CSS patients caused by this gene mutation have been reported in China, and most of them have developmental disabilities, impaired intellectual and motor development, feeding difficulties, and multiple organ malformations, but there are no reports of epileptic seizures.

The protein encoded by the SMARCC2 gene is a member of the SWI/SNF protein family, members of which have helicase and ATPase activities and are thought to regulate the transcription of certain genes by altering the chromatin structure surrounding those genes. This gene (NM-0003075.5) contains 28 exons, encoding 1214 amino acids. There have been international reports that this gene causes CSS with epilepsy, but there are no reports in China on CSS caused by this gene.<sup>6</sup>

There is heterogeneity in the clinical phenotype of children with CSS, and there are differences at different stages of growth. The clinical phenotype of children becomes more and more

obvious with age. It is not obvious in infancy, but there may be some congenital abnormal appearances, including distal fifth toe and/or nail hypoplasia, and special facial features. In addition, problems that may be first noticed in infancy include feeding difficulty (90%), slow growth (90%), hypokalaemia (75%), seizures (50%), hearing impairment (45%), visual impairment (40%), congenital heart disease (35%), and urogenital malformations (35%).<sup>7</sup> The clinical manifestations in childhood become more obvious, and there may be different degrees of developmental and cognitive delays, among which the language expression disorder is more prominent. Studies have shown that children with CSS typically have moderate to severe mental retardation (IQ between 40 and 69), but children with CSS with IQs as high as 97 have also been reported.<sup>8</sup> About 1/3 of CSS patients gradually develop short stature ( $\leq 2$  SD) after birth, the bone age usually lags behind the age by 2-3 years, and there is growth hormone deficiency.<sup>9</sup> Hearing impairment can also occur in a small number of patients, mostly sensorineural, and can be conductive in a few children. Seizures in CSS patients can occur from birth to adolescence, mainly as tonic or myoclonic seizures, while others have abnormal EEG but no clinical seizures.

Some CSS patients are complicated with urinary, reproductive, and cardiac diseases, such as hydronephrosis, cryptorchidism, atrial septal defect, ventricular septal defect, hernia, pectus excavatum, etc.,<sup>10</sup> and few patients may have endocrine abnormalities such as thyroid function depression, diabetes, etc.

This child had no developmental and cognitive retardation, and his language development was generally normal. He had a special face only. Except for more frequent epileptic seizures, there were no other systemic symptoms. With frequent epileptic seizures, cognitive dysfunction appeared, which is the direction to focus on in the future clinical work.

Currently, there is no specific treatment for CSS. Children with feeding difficulties or poor body mass growth need to be assessed by gastroenterology and nutrition teams. Those with extreme feeding difficulties can be fed with a nasogastric tube or supplemented with nutrition. People with short stature need regular monitoring of growth hormone and bone age, and subcutaneous injection of growth hormone, if necessary. Patients with congenital heart disease or genitourinary malformation may need surgery as appropriate. Antiepileptic drugs should be added to patients with seizures, and video EEG should be reviewed regularly. Individuals with intellectual motor retardation can receive rehabilitation treatment. For children with a tendency towards loneliness spectrum disorder, relevant scales can be used for evaluation to achieve early identification and intervention. Patients with ocular lesions should undergo annual ophthalmological examinations, including fundus examinations, and visual acuity tests and corrections as needed. Hearing impaired individuals should wear hearing-aids. The parents of children with CSS require genetic counselling when they reproduce because it cannot be ruled out that the parents are germline mosaic carriers.

In conclusion, the possibility of CSS should be considered clinically for children with mental retardation, hirsutism, unique facial features, hypotonia, and phalangeal/nail hypoplasia. The *SMARCC2* mutation in the CSS child in this case not only enriches the gene mutation spectrum but also complements other gene mutation types of the CSS. The child only had epileptic seizures and a special face, and other clinical phenotypes were not classical. Whether the clinical phenotype of this gene variation is different from other CSS gene variants remains to be determined.

#### PATIENT'S CONSENT:

Written informed consent was obtained from the patient's parent.

#### COMPETING INTEREST:

The authors declared no competing interest.

#### AUTHORS' CONTRIBUTION:

XW, LF: Carried out the studies, participated in collecting data, drafted the manuscript and are responsible and accountable for the accuracy or integrity of the work.

YZ, RS: Performed the statistical analysis and participated in its design.

YL, WL: Participated in acquisition, analysis, or interpretation of data and drafted the manuscript.

All authors approved the final manuscript.

## REFERENCES

- Schrier Vergano S, Santen G, Wiczorek D, Wollnik B, Matsumoto N, Deardorff MA. Coffin-Siris Syndrome. In: Adam MP, Everman DB, Mirzaa GM, et al., Eds. GeneReviews®. Seattle (WA); University of Washington, 2013.
- Curcio MR, Ferranti S, Lotti F, Grosso S. Coffin-Siris syndrome and epilepsy. *Neurol Sci* 2021; **42(2)**:727-9. doi:10.1007/s10072-020-04782-y.
- Sekiguchi F, Tsurusaki Y, Okamoto N, Teik KW, Mizuno S, Suzumura H, et al. Genetic abnormalities in a large cohort of Coffin-Siris syndrome patients. *J Hum Genet* 2019; **64(12)**:1173-86. doi:10.1038/s10038-019-0667-4.
- Tsurusaki Y, Okamoto N, Ohashi H, Kosho T, Imai Y, Hibi-Ko Y, et al. Mutations affecting components of the SWI/SNF complex cause Coffin-Siris syndrome. *Nat Genet* 2012; **44(4)**:376-8. doi:10.1038/ng.2219.
- Santen GW, Aten E, Vulto-van Silfhout AT, Pottinger C, van Bon BW, van Minderhout IJ, et al. Coffin-Siris syndrome and the BAF complex: Genotype-phenotype study in 63 patients. *Hum Mutat* 2013; **34(11)**:1519-28. doi:10.1002/humu.22394.
- Li D, Downes H, Hou C, Hakonarson H, Zackai EH, Schrier Vergano SA, et al. Further supporting *SMARCC2*-related neurodevelopmental disorder through exome analysis and reanalysis in two patients. *Am J Med Genet A* 2022; **188(3)**:878-82. doi:10.1002/ajmg.a.62597.
- Tsurusaki Y, Koshimizu E, Ohashi H, Phadke S, Kou I, Shiina

- M, *et al.* *De novo* *SOX11* mutations cause Coffin-Siris syndrome. *Nat Commun* 2014; **5**:4011. doi:10.1038/ncomms5011.
8. Santen GW, Aten E, Sun Y, Almomani R, Gilissen C, Nielsen M, *et al.* Mutations in SWI/SNF chromatin remodeling complex gene *ARID1B* cause Coffin-Siris syndrome. *Nat Genet* 2012; **44**(4):379-80. doi:10.1038/ng.2217.
9. Yu Y, Yao R, Wang L, Fan Y, Huang X, Hirschhorn J, *et al.* *De novo* mutations in *ARID1B* associated with both syndromic and non-syndromic short stature. *BMC Genomics* 2015; **16**(1):701. doi:10.1186/s12864-015-1898-1.
10. van der Sluijs PJ, Jansen S, Vergano SA, Adachi-Fukuda M, Alanay Y, AlKindy A, *et al.* The *ARID1B* spectrum in 143 patients: From nonsyndromic intellectual disability to Coffin-Siris syndrome [updated 2019 Jan 29]. *Genet Med* 2019; **21**(6):1295-307. doi:10.1038/s41436-018-0330-z.

•••••