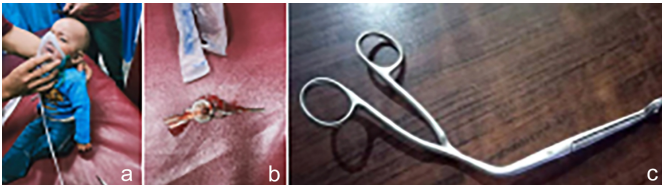


# Ingestion of Multiple Keys in a 12-Month-Old Infant: Management of Oropharyngeal Foreign Body

Sir,

Ingestion of foreign bodies is a common problem in paediatric patients, particularly in infants and young children.<sup>1</sup> although most ingested foreign bodies pass spontaneously without complications, some may become lodged in the gastrointestinal tract or respiratory tract, leading to serious complications. However, no case report on the ingestion of multiple keys with a key chain is found in the literature. This case report highlighted the importance of prompt recognition and management of the oropharyngeal foreign body in infants. These are essential to prevent complications and minimise morbidity and mortality.



**Figure 1:** (a) The infant at the time of presentation in the emergency department. (b) The removed keys and key chain. (c) The Magill forceps used to remove the keys.

A 12-month-old male infant was presented to the emergency department with a history of ingestion of multiple keys in the oropharynx. The patient was initially asymptomatic, with no evidence of respiratory distress or gastrointestinal symptoms (Figure 1a). A plain radiograph of the neck and chest showed the presence of multiple radiopaque foreign bodies in the oropharynx. A laryngoscope was used to visualise the foreign bodies, which were grasped and removed using Magill forceps (Figure 1b and c). The procedure was successful, and the patient was discharged home with no complications.

Ingestion of foreign bodies is a common problem in paediatric patients, but ingestion of multiple keys along with a key chain may present a particular challenge due to the risk of airway obstruction and local injury. Using a laryngoscope and Magill forceps can be a safe and effective method for removing oropharyngeal foreign bodies in infants. Oropharyngeal foreign body impaction is a potentially life-threatening condition in infants and young children.<sup>1,2</sup>

This case highlighted the importance of keeping an eye on kids to prevent ingestion of keys and key chains as these are common household items kept in easily accessible areas.

## COMPETING INTEREST:

The authors declared no competing interest.

## AUTHORS' CONTRIBUTION:

MMS: Drafted the manuscript.

HS: Critical review of the manuscript.

All authors approved the final version of the manuscript to be published.

## REFERENCES

1. Gmeiner D, von Rahden BH, Meco C, Hutter J, Thiede A. Endoscopic foreign body removal in the esophagus and stomach: An analysis of 848 cases in a 10-year period. *Surg Endosc* 2007; **21(4)**:626-31. doi: 10.1007/s00464-006-9011-6.
2. Arana A, Hauser B, Hachimi-Idrissi S, Vandenplas Y. Management of ingested foreign bodies in childhood and review of the literature. *Eur J Pediatr* 2001; **160(8)**:468-72. doi: 10.1007/s004310100779.

Muhammad Mohsin Sajjad and Hamid Shahzad

Department of Emergency Medicine, Lady Reading Hospital, Peshawar, Pakistan

Correspondence to: Dr. Muhammad Mohsin Sajjad, Department of Emergency Medicine, Lady Reading Hospital, Peshawar, Pakistan

E-mail: drmohsin345@gmail.com

Received: March 08, 2023; Revised: April 18, 2023;

Accepted: May 05, 2023

DOI: <https://doi.org/10.29271/jcpspcr.2023.1212>

.....