

# Unusual Presentation of Colonic Carcinoma as a Psoas Abscess

Ubaid Ullah and Syed Majid Ali Shah

Department of Surgery, Khyber Teaching Hospital, Peshawar, Pakistan

## ABSTRACT

A psoas abscess, also known as an iliopsoas abscess (IPA), is a collection of pus in the iliopsoas muscle compartment of the pelvis. It can present with vague clinical symptoms, which results in a delay in its diagnosis. The aetiology depends on demographic areas, but the most common cause is tuberculosis in the developing countries. IPA rarely occurs due to colonic cancer in the developing countries. Here are two case reports of middle-aged, immunocompetent males who had symptoms of pain in right flank and right iliac fossa associated with fever. CT scans of the abdomen and pelvis confirmed the clinical suspicion of IPA. The abscesses were drained surgically; peri-operatively, gelatinous material along with granulation tissue was noted. The histopathology indicated mucinous adenocarcinoma. Therefore, all patients who present with a psoas abscess should have a complete evaluation.

**Key Words:** Colonic carcinoma, Psoas abscess, Surgical drainage.

**How to cite this article:** Ullah U, Shah SMA. Unusual Presentation of Colonic Carcinoma as a Psoas Abscess. *JCPSP Case Rep* 2023; 1:83-85.

## INTRODUCTION

The iliopsoas abscess (IPA) is a collection of pus in the iliopsoas muscle compartment. The incidence of IPA is low, ranging from 0.5 cases per 10,000 hospital admissions in the years 1993-2004, to 6.5 cases per 10,000 hospital admissions in the years 2005-2007 at an urban, tertiary care centre.<sup>1</sup> Primary IPA results from the haematogenous dissemination of an infectious process from an occult source within the body. Among secondary IPA, Crohn's disease is the most common cause, along with other causes like diverticulitis, appendicitis, colorectal cancer or female genital tract malignancies.<sup>2,3</sup> The likelihood of having an IPA is also increased by other disorders such as genitourinary, musculoskeletal, and vascular diseases, as well as by procedures in the groin, lumbar, or hip regions.<sup>2</sup> Organisms causing IPA predominantly include *Escherichia coli* and *Bacteroides* species.<sup>4,5</sup> Originally, the classical triad of back pain, limp, and fever was described, but subsequent studies have shown that only 30% of patients experience this triad.<sup>6</sup> Patients typically exhibit vague symptoms at first, such as malaise and low-grade pyrexia, which may develop into more specific symptoms, including abdominal/flank discomfort, an externally rotated hip, and pain with the movements of the hip.<sup>6</sup>

Herein, two case reports are given of middle-aged immunocompetent males who had symptoms of pain in right flank and right iliac fossa associated with fever. They were initially diagnosed clinically as IPAs but later on, were found to have colonic adenocarcinomas.

## CASE 1

A 45-year male had a fall that resulted in a wound in his right flank. The wound healed with time, but his pain did not subside. The pain aggravated with lying down and movement of his right leg and was associated with anorexia, nausea, and fever. He went to a medical facility, which performed investigations, and upon assessment, diagnosed him with IPA. Consequently, he underwent incision and drainage (I/D) for the IPA.

He presented to the authors with a discharging wound in his right flank that was associated with pain in his right iliac fossa that radiated to his right thigh. He had been febrile for the previous five days. He had no other symptoms of weight loss or a change in bowel habits.

On examination, he had a tender right flank and right iliac fossa, along with a positive psoas sign. All baseline investigations were performed along with CT of the abdomen and pelvis with oral contrast (Figure 1), which showed IPA with a collection of around 186 ml in volume. His other laboratory investigations showed a total leucocyte count of  $12.9 \times 10^3/\mu\text{l}$ , a neutrophilic count of 84%, and haemoglobin of 10.7 g/dl. His sputum was negative for acid-fast bacilli.

As IPA was recurrent, it was drained with open surgery. Perioperatively, around 50 ml of gelatinous material along with granulation tissue were noted in the psoas cavity. The pus was sent for

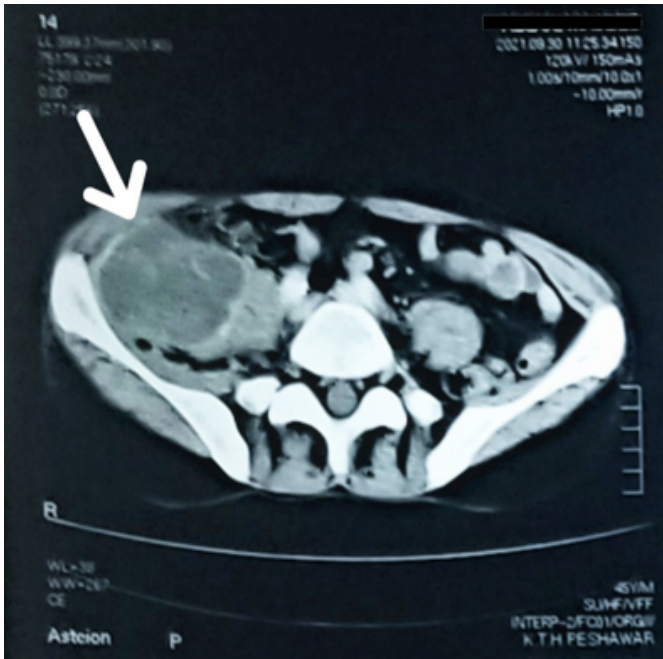
Correspondence to: Dr. Ubaid Ullah, Department of Surgery, Khyber Teaching Hospital, Peshawar, Pakistan  
E-mail: ubaidyousafzai39@gmail.com

Received: February 20, 2023; Revised: June 21, 2023;

Accepted: July 27, 2023

DOI: <https://doi.org/10.29271/jcpspcr.2023.83>

culture and sensitivity, and the tissue was sent for histopathology. The histopathological examination of the tissue reported mucinous adenocarcinoma with positive pancytokeratin (AE1/AE3).



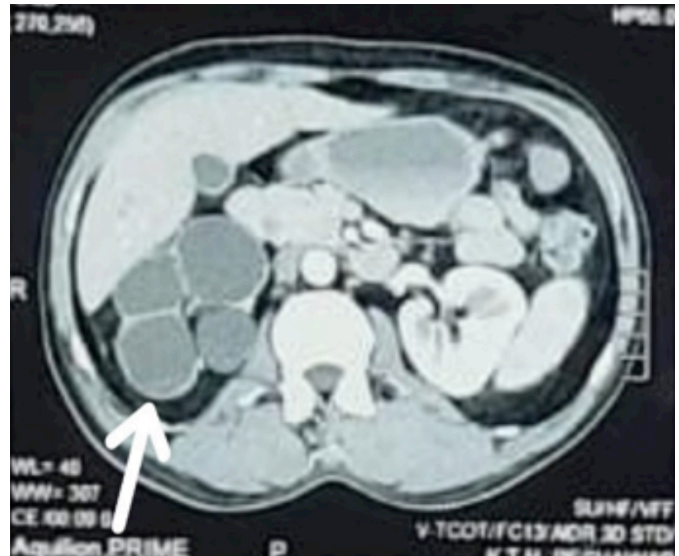
**Figure 1:** CT scan of abdomen and pelvis with oral and intravenous contrast. The arrow points towards the multiloculated, marginally enhancing collection in the right iliopsoas muscle bulging into the right iliac fossa.

### CASE 2

A 52-year male developed a painful lump in the right iliac fossa. He was assessed and diagnosed with IPA, for which he underwent I/D in a tertiary care hospital.

He presented to the authors with symptoms of lower abdominal pain, constipation, and swelling of the right side of the abdomen associated with fever. The CT abdomen and pelvis showed a right psoas abscess along with right-sided pelvi-ureteric junction (PUJ) obstruction causing gross hydronephrosis. Consequently, he underwent I/D by draining 130 ml of pus with a drain placement, and a biopsy was taken from the walls of the cavity for histopathology.

The histopathology revealed mucinous adenocarcinoma with Ki-67 >20%. Further investigations, including a CT of the chest, abdomen, and pelvis, were carried out to determine the extent of the disease (Figure 2). It showed heterogeneously enhancing cystic collection involving the lower segment of the iliopsoas muscle with a tubular, blind-ending tube extending from the cecum. The multidisciplinary team labelled it as mucinous adenocarcinoma of the appendix, for which he underwent a right hemicolectomy; perioperatively, the patient was found to have a hard mass arising from the base of the appendix.



**Figure 2:** CT scan of abdomen and pelvis with oral and intravenous contrast. The arrow points towards a heterogeneously enhancing, multiloculated cystic collection involving the lower segment of the right iliopsoas muscle.

### DISCUSSION

IPA is a relatively uncommon diagnosis. In recent years, a primary IPA due to haematogenous spread from an occult source has become more common, especially in immunocompromised individuals. The main causes of secondary IPA are Crohn’s disease, diverticulitis, appendicitis, and very rarely, colonic cancer. Around 30% of individuals have the traditional presentation of back pain, a limp, and a fever.<sup>5</sup> Therefore, IPA can be a diagnostic challenge for patients presenting with vague symptoms. Blood cultures and other laboratory investigations such as complete blood count, C-reactive protein, and erythrocyte sedimentation rate can help confirm the diagnosis of an inflammatory mass. However, formal imaging methods, such as MRI, CT, and ultrasonography, are needed to confirm the diagnosis and to plan any additional treatment.<sup>6</sup> A broad-spectrum antibiotic is generally the accepted first-line treatment. Historically, surgical drainage was the preferred course of treatment, and some authors noted that patients recover more quickly after open drainage. Image-guided percutaneous drainage has since been proven to be a very safe and effective alternative.<sup>6</sup> Patients presenting with unexplained IPA having no apparent primary or secondary cause should be suspected of having colonic carcinoma.<sup>7</sup> Although the incidence of perforation in colon cancer varies between 3 and 10%, the incidence of these perforations leading to IPA is only 0.3 to 4%.<sup>8</sup> Colonic carcinoma presents with a number of symptoms, including weight loss, bleeding per rectum, anaemia, and a palpable mass per abdomen. Colonoscopy, CT scan, and other imaging tests may be used in full evaluation to determine the location and extent of colonic cancer, depending on the site of the disease. There are drawbacks to draining the IPA, including a narrow field of exposure, the presence of inflammation, and thicker colonic walls that could isolate the colonic mass. The approach to drainage depends on clinical features like primary or recurrent disease, presence of loculations, and the number of sites.<sup>9</sup>

Therefore, a thorough assessment of the patient presenting with IPA is necessary to determine the exact cause of the abscess before any surgical intervention is carried out.

**PATIENTS' CONSENT:**

Informed consents were obtained from the patients to publish the case.

**COMPETING INTEREST:**

The authors declared no competing interest.

**AUTHORS' CONTRIBUTION:**

UU: Data collection, drafting the work and finalising it for submission.

SMAS: Data collection and writing the initial draft of the manuscript.

**REFERENCES**

1. Alonso CD, Barclay S, Tao X, Auwaerter PG. Increasing incidence of iliopsoas abscesses with MRSA as a predominant pathogen. *J Infect* 2011; **63(1)**:1-7. doi: 10.1016/j.jinf.2011.05.008.
2. Mallick IH, Thoufeeq MH, Rajendran TP. Iliopsoas abscesses. *Postgrad Med J* 2004; **80(946)**:459-62. doi: 10.1136/pgmj.2003.017665.
3. Takamatsu S, Murakami K, Takaya H, Tobiume T, Nakai H, Suzuki A, et al. Malignant psoas syndrome associated with gynecological malignancy: Three case reports and a review of the literature. *Mol Clin Oncol* 2018; **9(1)**:82-6. doi: 10.3892/mco.2018.1635.
4. Ricci MA, Rose FB, Meyer KK. Pyogenic psoas abscess: Worldwide variations in aetiology. *World J Surg* 1986; **10(5)**:834-43. doi: 10.1007/BF01655254.
5. López VN, Ramos JM, Meseguer V, Pérez Arellano JL, Serrano R, Ordóñez MAG, et al. Microbiology and outcome of iliopsoas abscess in 124 patients. *Medicine (Baltimore)* 2009; **88(2)**:120-30. doi: 10.1097/MD.0b013e31819d2748.
6. Shields D, Robinson P, Crowley TP. Iliopsoas abscess-a review and update on the literature. *Int J Surg* 2012; **10(9)**:466-9. doi: 10.1016/j.ijisu.2012.08.016.
7. Maglinte DD, Pollack HM. Retroperitoneal abscess: A presentation of colon carcinoma. *Gastrointest Radiol* 1983; **8(2)**:177-81. doi: 10.1007/BF01948116.
8. Mandava N, Kumar S, Pizzi WF, Aprile IJ. Perforated colorectal carcinomas. *Am J Surg* 1996; **172(3)**:236-8. doi: 10.1016/s0002-9610(96)00164-x.
9. Townsend CM Jr, Beauchamp RD, Evers BM, Mattox KL. Sabiston textbook of surgery: The biological basis of modern surgical practice. ed 20<sup>th</sup>, Philadelphia, PA; 2016.

