

Management of Complications after Levator Resection for Ptosis

Khawaja Khalid Shoaib, Muhammad Awaid Abid, Saad Aziz, Fiza Azhar, Muhammad Sohail Shehzad and Sheikh Muhammad Shahbaz Ali

Mughal Eye Hospital Trust, Lahore, Pakistan

ABSTRACT

Objective: To analyse the complications after external levator resection (ELR) for ptosis, and their management.

Study Design: Observational Study.

Place and Duration of the Study: Mughal Eye Hospital Trust, Lahore, from June 2018 to December 2022.

Methodology: A total of 256 eyes were operated for ptosis cases having good levator function who were treated by ELR. The exclusion criteria was any history of operation of lids or orbits or poor levator function, Marcus Gunn jaw-winking phenomenon, and neurogenic ptosis. The frequency of complications and their management was documented.

Results: Age ranged from 6 to 65 years. The follow-up ranged from 8 weeks to 3 years. Eleven (4.3%) cases developed complications. Two cases had mild undercorrection and did not require any treatment. In moderate overcorrection encountered in one eye, pulling the lid down for a few times daily improved lid level in four weeks. Four eyes had severe overcorrection, 2 patients required one operation and the other two patients required two operations each. These included hang-back sutures in two eyes (with 5/0 Ethibond in one eye and 6/0 Vicryl sutures in another eye) and simple incision in the levator (disinserting it partially from the tarsal plate) in two eyes. Lagophthalmos in two eyes improved with conservative treatment. Notching in two eyes improved with partial disinsertion of levator by cutting one Vicryl suture attaching levator to the tarsal plate and leaving 2 Vicryl sutures connecting levator to the tarsal plate.

Conclusion: Ptosis correction by ELR is a low-complication procedure with good corrective results.

Key Words: *Ptosis, Good levator function, Overcorrection after ptosis operation, Hang-back sutures, Partial levator disinsertion.*

How to cite this article: Shoaib KK, Abid MA, Aziz S, Azhar F, Shehzad MS, Ali SMS. Management of Complications after Levator Resection for Ptosis. *J Coll Physicians Surg Pak* 2023; **33(12)**:1410-1413.

INTRODUCTION

Ptosis (drooping of upper eyelid) patients having fair or good levator function (5 mm or more) are best treated with external levator resection (ELR) or advancement (ELA). In myogenic ptosis, levator is dystrophic and fibrotic, so it can neither contract properly nor relax. Levator function decrease in such patients. Aponeurotic ptosis cases usually have good levator function. The amount of levator resection required is decided by degree of ptosis and levator function. As a rough guide, if levator function is 8 mm, final lid position at the end of levator resection for ptosis should be where one wants the lid to remain postoperatively (normally 2 mm below the limbus). If levator function is more than 8 mm, lid level at the end of the operation should be 2 mm below the desired lid position. If levator function is less than 8 mm, postoperative lid level should be at the limbus (Berke's intraoperative determination of lid level).^{1,2}

Degree of ptosis is also an important consideration. Mild ptosis requires 10 mm of levator resection while in severe cases, maximum of 30 mm of resection is done (Beards' preoperative determination of lid level).³ Levator function was found to increase by 1.5 mm after levator resection in both myogenic and aponeurotic ptosis.⁴ Intraoperative lagophthalmos had been used to guide amount of levator resection required.^{5,6} Muller muscle conjunctiva resection (MMCR) had been found to be better than levator advancement surgery as far as overcorrection and reoperation rates are concerned.⁷ MMCR had been used to correct residual ptosis after levator resection.^{8,9} With careful preoperative measurement of amount of levator resection, intraoperative suture adjustments will not be required.¹⁰ Success rate of levator resection had been found to be 82%.¹¹ Putterman ptosis clamp had been found to improve the levator resection.¹² A few studies observed good results after maximum levator resection for ptosis with poor levator resection.¹³

Complications after ELR may include overcorrection, undercorrection, notching or abnormal lid contour, lagophthalmos, and lash ptosis. Lagophthalmos is the inability to close the eyes especially while sleeping. Marked under correction requires reoperation. Overcorrection can be dealt in different ways,

*Correspondence to: Dr. Khawaja Khalid Shoaib, Mughal Eye Hospital Trust, Lahore, Pakistan
E-mail: kkshoaib@gmail.com*

*Received: May 31, 2023; Revised: August 29, 2023;
Accepted: November 27, 2023
DOI: <https://doi.org/10.29271/jcpsp.2023.12.1410>*

however, there is limited literature on that aspect. The objective of this study was to analyse the complications after external levator resection (ELR) for ptosis, and their management.

METHODOLOGY

A total of 256 eyes were operated on in Mughal Eye Hospital Trust, Lahore, from 2018 to 2022. All the ptosis cases having fair or good levator function were treated by ELR under general anaesthesia through external approach (skin incision). The inclusion criteria was ptosis cases having levator function of 5 mm or more. The exclusion criteria was any history of operation of lids or orbits, poor levator function (levator function of less than 5 mm), Marcus Gunn jaw-winking phenomenon, and neurogenic ptosis. This study adhered to the tenets of the Declaration of Helsinki and its later amendments and was approved by the Institutional Review Board of Mughal Eye Hospital Trust. Since it was a retrospective, observational study and did not involve any intervention or experiment, IRB approval was taken after the study.

Levator palpebrae superioris was approached through lid crease incision (8 – 10 mm from anterior lid margin). Orbicularis was dissected a few millimeters from orbital septum. Septum was incised to expose preaponeurotic fat pad. Levator posterior to preaponeurotic fat pad was exposed. Levator attachment to tarsal plate was cut and levator/ muller muscles were separated from conjunctiva. Tarsal plates were exposed by excising overlying orbicularis. Three 6/0 Vicryl sutures were passed through partial thickness tarsal plate and then through levator at desired height (10 – 30 mm) depending on amount of ptosis and levator function. Lid crease was reformed by interrupted skin sutures engaging levator in the bite. Frost suture at the end of every ptosis operation was applied to cover the cornea by the lower lid for 24 hours. In case of an operation for overcorrection, traction suture applied at the centre of upper eyelid and taped to the cheek, maintained traction of upper eyelid for 24 hours. Frequent lubricating eye drops were advised for four weeks after the operation to prevent dryness of cornea and development of exposure keratopathy.

RESULTS

The age ranged from 6 to 65 years. The follow-up ranged from 8 weeks to 3 years.

Eleven eyes (4.3%) developed complications. Two undercorrection cases were treated conservatively. In one eye with moderate overcorrection, pulling the lid down for a few times daily improved lid level in four weeks (Figure 1 and 2).

Four eyes had severe overcorrection. All were cases with good levator function (levator function of more than 15 mm). Satisfactory correction of ptosis was achieved in two eyes on the first postoperative day. After the first operation for overcorrection, two eyes of the two patients required a second operation. Operations done for four severe overcorrection eyes were hang-back sutures in two eyes (with 5/0 Ethibond in one eye and 6/0 Vicryl sutures in one eye) and simple incision in the levator (disinserting it partially from the tarsal plate) in two eyes (without hang-back sutures).

Notching in two eyes improved with partial disinsertion of levator by cutting one Vicryl suture attaching levator to the tarsal plate and leaving two Vicryl sutures connecting levator to the tarsal plate. Lagophthalmos in two eyes improved with the conservative treatment (Table I).

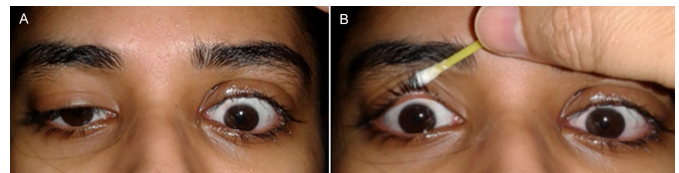


Figure 1: (A) Left overcorrection after levator resection for ptosis with good levator function; (B) Mechanically lifting right eyelid decreases left overcorrection (revealing exact amount of overcorrection).

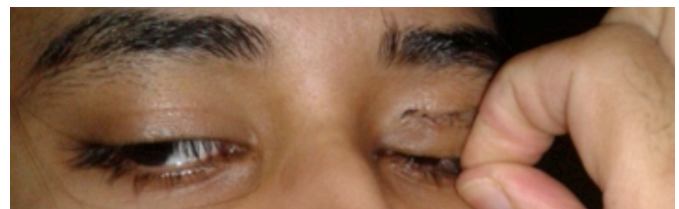

Figure 2: Pulling eyelid and eyelashes down with index finger and thumb.

Table I: Complications after levator resection for ptosis (total eyes = 256).

| Complications (No.) Total=11 | Severity | No. of operations | Treatment / Operation |
|---------------------------------|--------------|--|---|
| Undercorrection = 2 | | Nil | Nil |
| Overcorrection = 5 | Moderate = 1 | Nil | Pulling the lid down daily for four weeks |
| | Severe = 4 | Corrected after 1 st Op = 2 | Hang-back sutures = 1 Cutting central half of the levator = 1 |
| | | Corrected after 2 nd Op = 2 | Hang-back sutures = 1 Cutting central half of the levator = 1 |
| Notching = 2 | | One op in each eye | Partial disinsertion of levator by cutting one vicryl suture attaching levator to the tarsal plate at the point of notching and leaving 2 vicryl sutures connecting levator to the tarsal plate |
| Lagophthalmos = 2 | | Nil | Conservative treatment |

DISCUSSION

Ptosis correction with levator resection *via* external (skin) approach is a rewarding surgery with good results in the vast majority of cases. Large levator resections can be made as well as blepharoplasty can be done at the same time in case of excessive lid skin (dermatochalasis). Ideally, levator resection should be done under local anaesthesia so that lid level can be checked at the end of the operation while the patient is at the table and readjustment can be done at the spot. Levator resection under local anaesthesia was performed first in two cases but patients were not comfortable during the surgery so the rest of operations were done under general anaesthesia. Lid level achieved at the end of the operation was Berke's and Beard's recommendations, mentioned in the introduction above. However, good levator function in a few cases resulted in overcorrection after a few days. Lagophthalmos was a concern in the patients, but it gradually improved in one month in these patients. The attachment between Whitnall's ligament and levator was released in one study which reported an improvement in levator function and post-operative lagophthalmos.¹⁴

Ptosis repair can be done both by anterior or external (skin) approach and *via* posterior or conjunctival approach. A few studies found better results with MMCR than ELR.¹⁵ Others are of the opinion that MMCR should be reserved only for mild/moderate ptosis with good levator function while cases having severe ptosis or less levator function should be treated with ELR.¹⁶ MMCR had been found to produce better symmetry of the lids and less requirement for reoperation as compared to ELA. Both can be learnt/taught with equal difficulty/ease. ELA can take more operative time and is associated with more complications than MMCR.¹⁷ Early postoperative swelling after ELR did not affect the outcome of ptosis surgery.¹⁸ While levator function and amount of ptosis were two important considerations while deciding the amount of levator resection, these two factors were poorly related to each other.¹⁹ Postoperative lid height was found to be stable after one month.²⁰ Complications after ELR were reported to be rare.²¹⁻²³ Lid retraction following ELR can improve with levator lengthening using pretarsal tissue.²⁴ Eyelid stretching exercises had been recommended to correct lid retraction.²⁵

In this series, undercorrections occurred in myogenic ptosis while overcorrections occurred in aponeurotic cases having good levator function, in spite of the fact that minimum levator resection (about 10 mm) was done. In literature, use of spacers (temporalis fascial graft) had been recommended to lengthen the levator. Others had recommended a transconjunctival incision (after lid everted over Desmarres retractor and conjunctiva exposed) dissecting central levator from tarsal plate. However, the authors tried to manage the overcorrections by hang-back sutures, which is the routine in muscle recessions in squint surgery, in the initial two cases. It turned out to be an effective measure to counter lid retraction. In one eye, the first operation was sufficient but in

another case, second operation was required. In hang-back sutures for lid retraction, 5/0 Ethibond suture was used for one eye and 6/0 Vicryl suture was used in the second eye. In the next two overcorrections, the initial skin incision was opened and incision was made at the central part of levator attachment with the tarsal plate. Thus, partial disinsertion of the levator was sufficient in one eye in the first operation. However, one eye required second operation with greater disinsertion of the levator. A satisfactory lid level was achieved in all the cases. The rationale was to document beneficial effects of hang-back sutures and extensive resection of levator during operations for overcorrections after ELR. The strength of this study was the large number of ELR cases. The limitation of this study was a small number of overcorrection cases.

CONCLUSION

Ptosis correction by ELR was an effective procedure with good results in the vast majority of cases. Only a few percentage of cases developed undercorrection, overcorrection, lagophthalmos or notching. Overcorrection or notching can be corrected by conservative manipulation or reoperation. Lagophthalmos usually improved in one month. In severe overcorrection, hang back suturing technique (with 5/0 Ethibond or 6/0 Vicryl sutures) or simple partial disinsertion of levator can be sufficient to attain normal lid position without requiring scleral patch or any other spacer.

ETHICAL APPROVAL:

An approval was acquired from IRB Mughal Eye Hospital Trust (IRB MEHT6 dated 20.5.23), Lahore, Pakistan.

PATIENTS' CONSENT:

Informed consent was obtained from the patients to publish the data.

COMPETING INTEREST:

The authors declared no conflict of interest.

AUTHORS' CONTRIBUTION:

KKS: Did operations, collected data, wrote and revised the manuscript, and approved the final manuscript.

SMSA, MSS, FA, SA, MAA: Wrote, revised, and approved the manuscript.

All authors approved the final version of the manuscript to be published.

REFERENCES

1. Berke RN. Resection of the levator palpebrae for ptosis with anatomic studies. *Trans Am Ophthalmol Soc* 1944; **42**:411-35.
2. Berke RN. Resection of the levator muscle through the external approach for congenital ptosis. *Trans Pac Coast Oto-ophthalmol Soc Annu Meet* 1964; **45**:207-14.
3. Beard C, Sullivan JH. Ptosis-current concepts. *Int Ophthalmol Clin* 1978; **18**(3):53-73. doi: 10.1097/00004397-197801830-00005.

4. Kashkoui MB, Abdolalizadeh P, Amirsardari A, Esmailkhanian H, Ghazizadeh M, Moradpasandi F. Postoperative levator function change in patients with unilateral myogenic versus aponeurotic blepharoptosis. *J Plast Reconstr Aesthet Surg* 2019; **72(10)**:1675-81. doi: 10.1016/j.bjps.2019.06.005.
5. Kang S, Seo JW, Ahn CJ, Esmaeli B, Sa HS. Intraoperative lagophthalmos formula for levator resection in congenital ptosis. *Br J Ophthalmol* 2019; **103(6)**:802-4. doi: 10.1136/bjophthalmol-2018-311945.
6. Rakha TM, El Saadani AEKI, Awara AM, Mandour SS. Evaluation of intraoperative lagophthalmos formula for levator resection in congenital ptosis in Egyptian patients. *Eur J Ophthalmol* 2021; **31(5)**:2755-58. doi: 10.1177/1120672120951760.
7. Karam M, Alsaif A, Abul A, Alkhabbaz A, Alotaibi A, Shareef E, Behbehani R. Muller's muscle conjunctival resection versus external levator advancement for ptosis repair: systematic review and meta-analysis. *Int Ophthalmol* 2023; **43(7)**:2563-73. doi: 10.1007/s10792-023-02633-1.
8. Ozturk Karabulut G, Fazil K, Karaagac Gunaydin Z, Serefoglu Cabuk K, Onmez FE, Taskapili M. Müller muscle conjunctiva resection for revision of residual ptosis after external levator advancement surgery. *Ophthalmic Plast Reconstr Surg* 2020; **36(5)**:458-462. doi: 10.1097/IOP.0000000000001594.
9. Mangan MS, Cakir A, Ercalik NY, Tekcan H, Balci S, Ozcelik Kose A, Imamoglu S, Turan Vural E. Efficacy of the Müller muscle-conjunctival resection for the correction of unilateral ptosis following external levator operations in patients with bilateral involutional ptosis. *Plast Reconstr Surg* 2021; **148(2)**:195e-199e. doi: 10.1097/PRS.00000000000008190.
10. Radke PM, Rubinstein TJ, Repp DJ, Sires BS. External levator resection for involutional ptosis: Is intraoperative suture adjustment necessary for good outcomes? *Orbit* 2021; **40(1)**:24-9. doi: 10.1080/01676830.2020.1725064.
11. Nabie R, Manouchehri V, Aminmozaffari S, Sakha H, Heidari N. Levator muscle resection for simple congenital ptosis: Its impact on preoperative levator function and dose-response ratio. *Can J Ophthalmol* 2023; **58(3)**:235-8. doi: 10.1016/j.jcjo.2022.01.008.
12. Yang JW, Yeung L, Chu YC, Lin YH, Chen CT. Efficacy of modified levator-muscle resection using Putterman ptosis clamp versus traditional levator-muscle resection for aponeurotic ptosis: A retrospective analysis. *Asian J Surg* 2022; **45(8)**:1535-41. doi: 10.1016/j.asjsur.2021.09.022.
13. Wuthisiri W, Peou C, Lekskul A, Chokthaweesak W. Maximal levator resection beyond Whitnall's ligament in severe simple congenital ptosis with poor levator function. *Clin Ophthalmol* 2022; **16**:441-52. doi: 10.2147/OPHTH.S340781.
14. Al-Faky YH, Abu El-Eneen MA, Selim KM, Ali HA. A Modified levator resection to improve postoperative lagophthalmos and eyelid lag. *Ophthalmic Plast Reconstr Surg* 2020; **36(1)**:38-44. doi: 10.1097/IOP.0000000000001454.
15. Sweeney AR, Dermarkarian CR, Williams KJ, Allen RC, Yen MT. Outcomes after Müller muscle conjunctival resection versus external levator advancement in severe involutional blepharoptosis. *Am J Ophthalmol* 2020; **217**:182-8. doi: 10.1016/j.ajo.2020.04.039.
16. Cohen LM, Rootman DB. Blepharoptosis Repair: External versus posterior approach surgery: Why I select one over the other. *Facial Plast Surg Clin North Am* 2021; **29(2)**:195-208. doi: 10.1016/j.fsc.2021.01.002.
17. Mangan MS, Cakir A, Imamoglu S. Cumulative sum analysis of the learning curve of ptosis surgery: External levator advancement versus Müller muscle-conjunctival resection. *Korean J Ophthalmol* 2021; **35(5)**:383-90. doi: 10.3341/kjo.2021.0058.
18. Cohen LM, Katsev B, Esfandiari M, Rootman DB. The Effect of early postoperative swelling on change in upper eyelid position after external levator resection and blepharoplasty. *Ophthalmic Plast Reconstr Surg* 2021; **37(4)**:320-3. doi: 10.1097/IOP.0000000000001740.
19. Nguyen CT, Hardy TG. Levator resection for congenital ptosis: Does pre-operative levator function or degree of ptosis affect successful outcome? *Orbit* 2017; **36(5)**:325-30. doi: 10.1080/01676830.2017.1337179.
20. Kim CY, Lee SY. Determination of the amount of ptosis correction in levator resection surgery for pediatric congenital ptosis. *Aesthetic Plast Surg* 2018; **42(1)**:201-7. doi: 10.1007/s00266-017-0982-0.
21. Buttanni IB, Serin D. Levator resection in the management of myopathic ptosis. *Korean J Ophthalmol* 2014; **28(6)**:431-5. doi: 10.3341/kjo.2014.28.6.431.
22. Hakimbashi M, Kikkawa DO, Korn BS. Complications of Ptosis Repair: Prevention and Management. In: Cohen A, Weinberg D, Eds. Evaluation and Management of Blepharoptosis. New York; Springer; 2011. Available from: http://doi.org/10.1007/978-0-387-92855-5_30.
23. Porteous AM, Haridas AS, Collin JRO, Verity DH. Upper lid ptosis surgery: What is the optimal interval for the postoperative review? A retrospective review of 300 cases. *Eye (Lond)* 2018; **32(4)**:757-62. doi: 10.1038/eye.2017.294.
24. Cho IC, Kang JH, Kim KK. Correcting upper eyelid retraction by means of pretarsal levator lengthening for complications following ptosis surgery. *Plast Reconstr Surg* 2012; **130(1)**:73-81. doi: 10.1097/PRS.0b013e3182547f7a.
25. Moon KY, You IC, Ahn M. Eyelid stretching exercise performed in overcorrection after levator resection in congenital ptosis. *J Korean Ophthalmol Soc* 2015; **56(10)**:1635-9. doi: 10.3341/jkos.2015.56.10.1635.

