

# Topical Tacrolimus Ointment Alone *versus* in Combination with Microneedling for Refractory Stable Vitiligo

Afshan Kiran, Seemab Khan, Najia Ahmed and Maira Ali

Department of Dermatology, P.N.S Shifa Hospital, Karachi, Pakistan

## ABSTRACT

**Objective:** To assess the efficacy of microneedling in combination with topical tacrolimus ointment 0.1% *versus* topical tacrolimus ointment 0.1% for treatment of refractory stable vitiligo.

**Study Design:** Comparative cross-sectional study.

**Place and Duration of the Study:** Department of Dermatology, PNS Shifa, Karachi, Pakistan, from December 2022 to May 2023.

**Methodology:** The study included 30 clinically diagnosed individuals of either gender who had refractory symptoms and aged between 20 and 60 years. For every patient, two comparable lesions on two comparable limb regions were selected. Group A (right side) received treatment with both topical tacrolimus ointment 0.1% twice daily in addition to microneedling every two weeks, whereas, Group B (left side) was treated with topical tacrolimus ointment 0.1% only. Every lesion was investigated as a separate entity. Both groups were subsequently observed for a further six months.

**Results:** When topical tacrolimus ointment 0.1% was combined with microneedling, the total re-pigmentation rate was substantially higher than the usage of tacrolimus ointment 0.1% alone. Fifty-three percent of lesions treated with topical tacrolimus ointment 0.1% alone and 76.7% of lesions treated with microneedling in conjunction with it showed a good-to-excellent response. No adverse negative effects were noted. During the follow-up period, no problems or recurrences were noted.

**Conclusion:** Tacrolimus ointment combined with microneedling is a successful treatment for refractory stable vitiligo.

**Key Words:** *Dermapen, Depigmentation, Microneedling, Tacrolimus ointment, Vitiligo.*

**How to cite this article:** Kiran A, Khan S, Ahmed N, Ali M. Topical Tacrolimus Ointment Alone *versus* in Combination with Microneedling for Refractory Stable Vitiligo. *J Coll Physicians Surg Pak* 2024; **34(05)**:514-517.

## INTRODUCTION

Vitiligo is a type of acquired, progressive melanocytopenia with an unclear aetiology. It affects both genders equally and manifests as ivory/chalky white macules of varying sizes and shapes. Although it can happen at any age, the highest incidence is observed among individuals aged between 10-30 years. This condition has no racial restrictions. Those with autoimmune diseases, such as diabetes mellitus, thyroid disorders, etc., have an incidence of 8-20%, which is lower than that of the general population (1-2%).<sup>1</sup> Although vitiligo is a benign and asymptomatic condition, it can occasionally lead to serious psychological issues in darker-skinned individuals. Patients with vitiligo experience social humiliation in society due to extensive stigmas, taboos, a lack of scientific appraisal, and misinformation surrounding the condition.<sup>2</sup>

Since melanocyte elimination is the cause of vitiligo, the goal of treatment should be to increase the melanocyte population.

When traditional medical interventions fail to provide any results, the hair bulb's melanocyte reserve is empty.<sup>3</sup> In this case, it is not possible to repopulate the vitiliginous area with melanocytes unless a fresh source of pigment cells is surgically implanted into depigmented lesions. The term stable vitiligo refers to situations in which the disease is dormant and no new patches have appeared in the previous year.<sup>4</sup>

Despite the abundance of therapeutic options available, dermatologists have encountered vitiligo patients since the beginning of time. There are two types of treatment for managing vitiligo: Medicinal and surgical. The medical treatment consists of topical calcineurin inhibitors, topical vitamin D analogues, topical 5-FU, phototherapy, oral and topical corticosteroids, antioxidants, levamisole, and immuno-suppressants while therapeutic wounds, lasers, and tissue and cell transplants are examples of surgical treatment.<sup>5,6</sup>

Through the creation of micropores that penetrate the epidermis and reach the papillary dermis, microneedling is a revolutionary procedure that induces repigmentation. It improves medication absorption, promotes repigmentation, and causes inflammation that causes melanocyte migration. It can be combined with various medications and used as monotherapy. It has been demonstrated to be helpful in combination therapy.<sup>7</sup> Tacrolimus ointment alone has not shown the same results as tacrolimus ointment with microneedling.<sup>8,9</sup>

Correspondence to: Dr. Afshan Kiran, Department of Dermatology, P.N.S Shifa Hospital, Karachi, Pakistan  
E-mail: afshankiran30@gmail.com

Received: November 26, 2023; Revised: March 26, 2024;

Accepted: April 16, 2024

DOI: <https://doi.org/10.29271/jcpsp.2024.05.514>

Topical 5-FU needling has also been tested, and the results showed an improved response.<sup>10</sup> The analysis of the literature reveals a dearth of studies comparing topical tacrolimus ointment 0.1% to microneedling in management of stable, resistant vitiligo. This study aimed to assess the effectiveness of topical tacrolimus ointment 0.1% against microneedling in combination for management of refractory stable vitiligo, since no treatment approach has been shown to be optimal.

## METHODOLOGY

This comparative cross-sectional study was conducted in the Dermatology Department of PNS Shifa, hospital Karachi, Pakistan, from December 2022 to May 2023. Since vitiligo has a very low prevalence in the population, therefore, 30 patients were collected. Using a non-probability consecutive sampling technique, 30 patients between the ages of 20 and 60 years who had been clinically diagnosed with refractory stable vitiligo for > 1 year and were willing to participate in routine follow-up were added in this research. Exclusion criteria were: Pregnancy or lactation, keloid or hypertrophic scarring history, current infection, bleeding or coagulation issues, and individuals who have had vitiligo treatment within the last six months. The split body approach was applied; each patient had two comparable lesions on two similar limb regions, with the right side of the body designated as A and the left side as B. Group A (right side) received treatment with both topical tacrolimus ointment 0.1% twice daily in combination with microneedling every two weeks, whereas, Group-B (left side) was treated with topical tacrolimus ointment 0.1% only. Every lesion was investigated as a separate entity. Both groups were subsequently observed for a further six months.

Topical tacrolimus ointment 0.1% and microneedling were applied concurrently to lesions A and B, respectively, and tacrolimus ointment 0.1% cream was used twice daily for a duration of three months. A patch measuring no more than 5 to 15 cm<sup>2</sup> of skin was chosen, and an alcohol swab was used to clean the region. Eutectic mixture of local anaesthetics (EMLA) cream 5% was applied for thirty to forty minutes. The chosen electronic dermapen<sup>®</sup> utilised varying needle sizes, ranging from 1.5 to 2 mm, based on the thickness of the skin at the targeted area. One hand was used to hold the dermapen<sup>®</sup> perpendicularly, and it was dragged over the treated areas in various directions until consistent pin-point bleeding appeared. The direction of migration was towards the depigmented centre from the perilesional portions. After applying topical tacrolimus ointment 0.1% to the treated areas under occlusion for approximately 6 hours and topical tacrolimus ointment 0.1% cream twice daily, the lesion was compressed with saline-soaked gauze to halt the bleeding.

The sessions were repeated every two weeks for a maximum of six times (3 months) or until repigmentation on the whole patch was attained. The follow-up period was 3 months after the final sessions (total course of the study was 6 months). As a noninvasive aesthetic procedure, microneedling is thought to have a low incidence of side effects. However, there may be reports of skin irritation, moderate erythema, oedema, dryness, and

flaking.<sup>11</sup> Additionally, itching, burning, stinging, and swelling are thought to be the most typical tacrolimus ointment 0.1% adverse effects. Therefore, the patients were told to report any negative effects that they experienced.<sup>12</sup>

Treatment evaluation was done using standardised worldwide photography, patients were photographed as the initial stage. Every picture was captured by the same photographer using the same digital camera (cannon IXUS 185) in the identical space, with identical lighting circumstances in terms of background, angle, and separation from the light source. The baseline and post-treatment pictures were examined by two neutral dermatologists who were blind to the study. Following repigmentation, the following qualitative reactions were noted: Mild improvement (<25%), moderate improvement (25-50%), good improvement (50-75%), great improvement (75-100%), and follicular repigmentation are the four categories.<sup>13</sup> Data analysis was done with SPSS version 26. Mean + SD was used to report quantitative data, whereas percentages and frequency were computed for qualitative data. The Chi-square test and t-test were used to compare the treatment response between the two groups. A p-value of less than 0.05 was deemed significant.

## RESULTS

This study comprised thirty participants with clinically verified refractory stable vitiligo. There were 28 females and 2 males presented. The demographic information is displayed in Table I.

**Table I: Demographic and clinical data of the patients (n = 30).**

Characteristics	Mean ± SD / n (%)
Age	
≤30 years	24 (80%)
>30 years	06 (20%)
Duration of disease	
≤5 years	16 (53.3%)
>5 years	14 (46.6%)
Gender	
Male	2 (6.6%)
Female	28 (93.3%)
Family history	
Yes	3 (10%)
No	27 (90%)
Type of skin	
III	20 (67%)
IV	10 (33%)

**Table II: Comparison between topical tacrolimus ointment 0.1% therapy and combination therapy according to degree of repigmentation.**

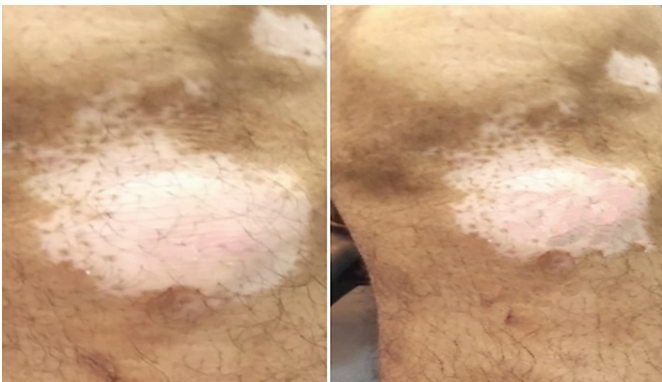
Type of response	Group-A n (%)	Group-B n (%)	p-value
Excellent >75%	14 (46.7%)	02 (6.7%)	0.003*
Good 50-75%	09 (30%)	14 (46.7%)	
Fair 25-50%	5 (16.7%)	9 (30%)	
Poor <25%	02 (6.7%)	05 (16.7%)	
Patterns of repigmentation			>0.99*
Marginal	24 (80%)	20 (66.7%)	
Perifollicular	06 (20%)	05 (16.7%)	
Diffuse	0 (0%)	5 (16.7%)	
Number of Sessions (mean ± SD)	6 ± 3.94	10 ± 2.09	<0.001**

\* Chi-square test, \*\* t-test

An excellent response was observed in 47% of the lesions treated with combined therapy, compared to 6% of the lesions treated with tacrolimus ointment 0.1% alone. Of the lesions in Group A and B, good response was observed in 30% and 46.7%, respectively. There was a significant difference between the two Groups. The combined treatment required fewer total sittings for response than tacrolimus ointment 0.1% alone. A marginal type repigmentation pattern, which accounted for 80% of Group A and 66.7% of Group B, predominated in both Groups. A perifollicular pattern was present in 20% of Group A and 16.7% of Group B. After just one session, repigmentation began as erythema and pigments. With combination therapy, an excellent response was seen in four weeks, compared to six weeks with tacrolimus ointment 0.1% alone as shown in Table II. The before and after photos of the vitiliginous patches in Group A (combination therapy) are displayed in Figure 1, while Figure 2 displays the vitiliginous patches in Group B (tacrolimus ointment alone) before and after photos.



**Figure 1: The before and after pictures of vitiliginous patches in Group A (combination treatment).**



**Figure 2: The before and after pictures of vitiliginous patches in Group B (tacrolimus ointment alone).**

## DISCUSSION

A common autoimmune illness called vitiligo causes the melanocytes to be destroyed and shows up as depigmented macules on different parts of the skin.<sup>6</sup> There is still no cure for this illness, despite a wealth of research and treatment options.<sup>7-14</sup> The treatment plan should be unique to each patient, taking into account their age, race, vitiligo subtype, afflicted skin region, and level of disease stability as stated in a study conducted by Khater *et al.*<sup>15</sup>

Topical calcineurin inhibitors (TCIs), such as tacrolimus ointment and pimecrolimus cream, are widely used in vitiligo treatment.<sup>5</sup> However, prior studies showed that microneedling may be an effective treatment for vitiligo.<sup>8</sup> Numerous dermatological problems have been treated with microneedling, a less invasive treatment. Research has indicated that microneedling is a secure and successful alternative for vitiligo. When combined with other approaches such as topical tacrolimus ointment, topical calcipotriol, and 5-fluorouracil, the effectiveness of the treatment has been proven to improve.<sup>8</sup> In the present research, the authors assessed and contrasted the effectiveness of treating patients with refractory vitiligo with topical tacrolimus ointment 0.1% alone, and with a combination of topical tacrolimus ointment 0.1% and microneedling.

After the first session, erythema or mild pigmentation was observed as the start of repigmentation; with a maximum of four sessions, good repigmentation was achieved in 47% of cases. Ebrahim *et al.*, however, found faster results when they compared tacrolimus ointment 0.1% plus microneedling with tacrolimus monotherapy, noting the start of repigmentation after three to four sessions.<sup>16</sup> The present study showed similar results to the study conducted by Ebrahim *et al.* where good to excellent response was seen in 70.8% cases. This is explained by the different processes used in the present study, which involved applying tacrolimus ointment before microneedling. This guarantees the medicine's deeper and more consistent entry. When tacrolimus ointment 0.03% was used in conjunction with microneedling, repigmentation started to occur within six weeks, according to research by Mina *et al.*<sup>17</sup> and 5% of the cases, the response was good to excellent. Passerson *et al.* saw excellent repigmentation in 70% of the lesions, When tacrolimus ointment and a 308 nm excimer laser were used.<sup>18</sup> Fifty percent of patients had an excellent response when tacrolimus ointment and excimer laser were combined, according to Attwa *et al.*<sup>19</sup>

This research found no significant negative impacts in this study. One patient complained of pain, but it subsided over a few hours. Although erythema, slight pain, and itching were observed by a few authors, the surgery was usually regarded as well tolerated.<sup>17</sup>

Although this study found a favourable response in refractory vitiligo, these results call for bigger sample sizes in future research. Dermatologists may find this method to be a useful treatment for vitiligo lesions that are resistant to other methods. Further studies with a larger sample size are recommended to better evaluate the efficacy of this method. Side effects of the treatment options may also be assessed to evaluate the safety of the drug.

## CONCLUSION

Tacrolimus ointment combined with microneedling is a successful treatment for resistant vitiligo. Patients may have less psychological stress associated with the disorder's stigma due to the procedure's simplicity and the outcomes that follow. To assess the long-term stability of repigmentation, comorbidities, and responsiveness in refractory vitiligo, more research should be done.

**ETHICAL APPROVAL:**

The study was approved by the Research Ethics Committee of PNS Shifa Hospital with approval no: ERC/2023/DERM/20, Dated 29-08-2023.

**PATIENTS' CONSENT:**

Informed consent was taken from all patients prior to the initiation of the study.

**COMPETING INTEREST:**

The authors declared no conflict of interest.

**AUTHORS' CONTRIBUTION:**

AK: Concept and design of the study, data collection and interpretation, and drafting.

SK: Concept of the study, data collection, and critical analysis.

NA: Data collection, critical analysis, and manuscript review.

MA: Data collection and drafting.

All authors approved the final version of the manuscript to be published.

**REFERENCES**

1. Iraj F, Asilian A, Talebzadeh Z, Saber M, Mokhtari F, Siadat A, et al. Microneedling in combination with topical pimecrolimus 1% versus topical pimecrolimus 1% for the treatment of refractory stable vitiligo: A randomized clinical trial. *Dermatol Res Pract* 2021; **2021**:5652140. doi: 10.1155/2021/5652140.
2. Tabassum S, Rahman A, Ghafoor R, Khan Q, Ahmed N, Amber T, et al. Quality of life index in patients with vitiligo. *J Coll Physicians Surg Pak* 2023; **3(5)**:521-6. doi: 10.29271/jcpcsp.2023.05.521.
3. Farajzadeh S, Esfandiarpour I, Khandani EP, Ekhlasi A, Safari S, Gorji SH, et al. Efficacy of combination therapy of pimecrolimus 1% cream and mometasone cream with either agent alone in the treatment of childhood vitiligo. *J Pak Assoc of Dermatol* 2019; **28(4)**:507-13. Available from: <http://jpad.com.pk/index.php/jpad/article/view/1315>.
4. Ibrahim ZA, Hassan GF, Elgendy HY, Al-Shenawy HA. Evaluation of the efficacy of transdermal drug delivery of calcipotriol plus betamethasone versus tacrolimus in the treatment of vitiligo. *J Cosmet Dermatol* 2019; **18(2)**:581-8. doi: 10.1111/jocd.12704.
5. Chhabra S, Chahar YS, Singh A. A comparative study of microneedling combined with topical 5-fluorouracil versus microneedling alone in treatment of localized stable vitiligo. *Indian J Dermatol* 2021; **66(5)**:574. doi: 10.4103/ijd.ijd\_130\_21.
6. Antonini A, Leta V, Teo J, Chaudhuri KR. Outcome of parkinson's disease patients affected by COVID-19. *Mov Disord* 2020; **35(6)**:905-8. doi: 10.1002/mds.28104.
7. Mokhtari F, Bostakian A, Shahmoradi Z, Jafari-Koshki T, Iraj F, Faghihi G, et al. Potential emerging treatment in vitiligo using Er: YAG in combination with 5FU and clobetasol. *J Cosmet Dermatol* 2018; **17(2)**:165-70. doi: 10.1111/jocd.12373.

8. Salloum A, Bazzi N, Maalouf D, Habre M. Microneedling in vitiligo: A systematic review. *Dermatol Ther* 2020; **33(6)**:e14297. doi: 10.1111/dth.14297.
9. Lee JH, Kwon HS, Jung HM, Lee H, Kim GM, Yim HW, et al. Treatment outcomes of topical calcineurin inhibitor therapy for patients with vitiligo: A systematic review and meta-analysis. *JAMA Dermatol* 2019; **155(8)**:929-38. doi: 10.1001/jamadermatol.2019.0696.
10. Sharma S, Matharoo P, Bassi R. Evaluation of combination of microneedling with tacrolimus in the treatment of stable vitiligo. *Port Soc Dermatol Venereol* 2021; **79(3)**:227-31. doi:10.29021/spdv.79.3.1336.
11. Alster TS, Graham PM. Microneedling: A review and practical guide. *Dermatol Surg* 2018; **44(3)**:397-404. doi: 10.1097/DSS.0000000000001248.
12. Alatabani M, Ghobara Y, Alissa A. Vitiligo-like depigmentation following treatment with imiquimod 5% cream for condylomata acuminata. *Case Rep Dermatol* 2021; **13(1)**:36-41. doi: 10.1159/000510736.
13. Shashikiran AR, Gandhi S, Murugesh SB, Kusagur M; Sugareddy. Efficacy of topical 5% fluorouracil needling in vitiligo. *Indian J Dermatol Venereol Leprol* 2018; **84(2)**:203-5. doi: 10.4103/ijdv.IJDVL\_386\_16.
14. Elshafy Khashaba SA, Elkot RA, Ibrahim AM. Efficacy of NB-UVB, microneedling with triamcinolone acetonide, and a combination of both modalities in the treatment of vitiligo: A comparative study. *J Am Acad Dermatol* 2018; **79(2)**:365-7.
15. Khater M, Nasr M, Salah S, Khattab FM. Clinical evaluation of the efficacy of trichloroacetic acid 70% after microneedling vs. intradermal injection of 5-fluorouracil in the treatment of nonsegmental vitiligo; a prospective comparative study. *Dermatol Ther* 2020; **33**:e13532. doi: 10.1016/j.jaad.2017.12.054.
16. Ebrahim HM, Elkot R, Albalate W. Combined microneedling with tacrolimus vs tacrolimus monotherapy for vitiligo treatment. *J Dermatolog Treat* 2020; **10**:1-6. doi: 10.1080/09546634.2020.1716930.
17. Mina M, Elgarhy L, Al-Saeid H, Ibrahim Z. Comparison between the efficacy of microneedling combined with 5-fluorouracil vs. microneedling with tacrolimus in the treatment of vitiligo. *J Cosmet Dermatol* 2018; **17(5)**:744-51. doi: 10.1111/jocd.12440.
18. Passeron T, Ostovari N, Zakaria W, Fontas E, Larrouy JC, Lacour JP, et al. Topical tacrolimus and the 308-nm excimer laser: A synergistic combination for the treatment of vitiligo. *Arch Dermatol* 2004; **140(9)**:1065-9. doi: 10.1001/archderm.140.9.1065.
19. Attwa EM, Khashaba SA, Ezzat NA. Evaluation of the additional effect of topical 5-fluorouracil to needling in the treatment of localized vitiligo. *J Cosmet Dermatol* 2020; **19(6)**:1473-8. doi: 10.1111/jocd.13152.

