

Massive Ovarian Edema Mimicking Malignancy

Sir,

Massive ovarian edema (MOE) is a rare clinical tumour-like condition, which affects young women. It was first described by Kalstone in 1969.¹ It can involve one or both ovaries.² It can present in pregnancy as well.³ The underlying etiology is impedance of venous or lymphatic flow due to partial or complete torsion of mesovarium, but arterial supply remains intact. This leads to luteinisation of stromal cells in the edematous ovary due to ovarian torsion and ischemic changes.² Differential diagnosis of MOE includes fibroma, sclerosing stromal tumour, krukensberg tumour, luteinised thecoma and ovarian myxoma.

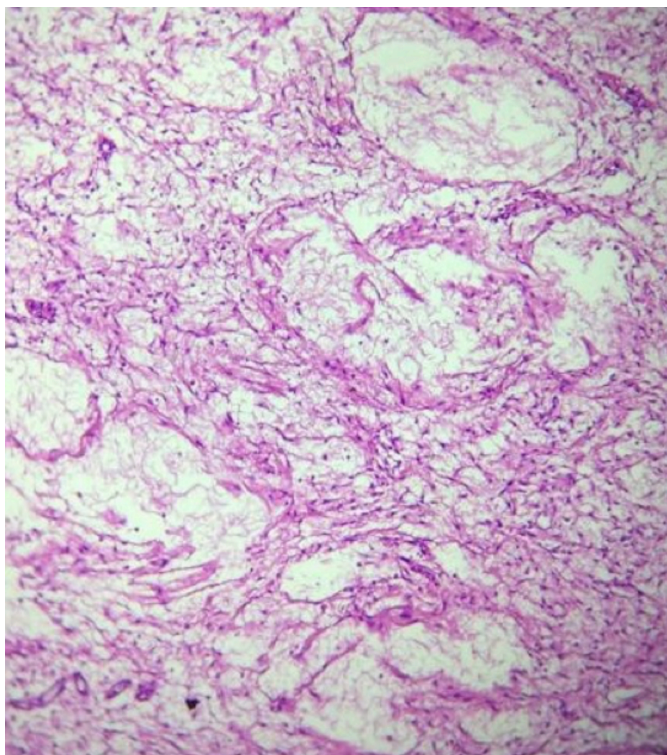


Figure 1: High-power photomicrograph showing massive ovarian edema (HE, X400).

MOE resembles ovarian neoplasms in its presentation and radiologic features leading to overtreatment in young girls who lose their hormonal function and fertility.⁴ A 24-year, unmarried girl presented with the complaints of oligomenorrhea for 1 year, abdominal distension for 6 months, and pain in left iliac fossa for one week. Abdominal examination revealed a 24-week size, mobile, soft, mildly tender mass in lower abdomen. CA-125 was 6.5 U/ml. Ultrasound showed an oval shaped, well encapsulated solid looking mass with central heterogeneity and hypoechoic areas in midline of pelvis measuring 16×6.1×11cm with no blood flow on color Doppler. Right ovary was normal. CT scan

showed a 159×71×129 mm well defined oval mass in lower abdominopelvic region showing minimal enhancement on post-contrast scan. No definitive solid component and septations were seen. On clinical and radiological findings, there was suspicion of ovarian neoplasm. She underwent exploratory laparotomy. Intraoperatively, 15×10 cm gelatinous, edematous left ovary with partial torsion was found. Both tubes and right ovary were normal looking. Decision to remove the affected ovary was taken and left ovary was removed.

Histopathology report showed MOE. On gross examination, an encapsulated soft tissue mass measuring 15×10×4 cm was seen with smooth and glistening serosal surface. On microscopy, sections showed markedly edematous ovarian stroma with rare luteinised cells at places and proliferating blood vessels (Figure 1). Peripheral rim of normal ovarian tissue was seen with no evidence of tumor.

In the past, accurate diagnosis of this clinical entity was difficult. But in recent times, provision of MRI and ultrasound provides better preoperative diagnosis. On literature review, ultrasound and MRI have been reported to show multiple ovarian follicles at the peripheral cortex and edematous ovarian stroma.⁵

Preservation of fertility is mainstay of treatment in these young girls. First choice of treatment should be conservative therapy, if patient is asymptomatic and ovarian blood flow is maintained on ultrasound by provision of analgesia. Surgical management is reserved for patients with worsening symptoms and compromised ovarian blood supply on ultrasound. Laparoscopy or laparotomy can be done depending upon the expertise. When preoperative diagnosis is not confirmed, frozen section can be done to prevent overtreatment in the form of oophorectomy.

CONFLICT OF INTEREST:

Authors declared no conflict of interest.

AUTHORS' CONTRIBUTION:

ST, RM: Synthesis, writing introduction and case report and discussion writing.

MH: Final proofreading.

REFERENCES

1. Kalstone CE, Jaffe RB, Abell MR. Massive edema of the ovary simulating fibroma. *Obstet Gynecol* 1969; **34(4)**: 564-71.
2. Parveen R, Pallavi VR, Rajashekar K, Usha A, Umadevi K, et al. A clinical update on massive ovarian edema, a pseudo tumour. *E cancer Medical science* 2013; **7**:318.
3. Amit V, Preeti RC, Garima G, Priyanka K. Massive ovarian edema: A case report presenting as a diagnostic dilemma. *J Family Med Prim Care* 2016; **5(1)**:172-4.
4. Nidhi R, Kavita M, Akshay R, Pooja C. Massive ovarian edema masquerading as fibroma. *Clin Cancer Investig J* 2016; **5(2)**:181-3.
5. Shahine GH, Heinrich H, Eliane MS, Guylaine L, Paraskevi AV. Bilateral massive ovarian edema due to chronic torsion

treated with conservative laparoscopic approach. *J Gynecologic Surg* 2018; **34(36)**:327-30.

Shazia Tazion, Maimoona Hafeez and Rukhsana Manzoor
.....
Department of Gynaecology / Obstetrics, Sharif Medical & Dental College, Lahore, Pakistan
.....

Correspondence to: Dr. Shazia Tazion, Department of Gynaecology / Obstetrics, Sharif Medical & Dental College, Lahore, Pakistan
E-mail: drtazion@yahoo.com

.....
Received: October 09, 2019; Revised: December 17, 2019;
Accepted: December 20, 2019
DOI: <https://doi.org/10.29271/jcpsp.2020.10.1111>

