

Morgagni's Hernia and Duodenal Stenosis Found to Co-Exist in Children with Down's Syndrome: A Case Report

Sir,

Morgagni's hernia is a congenital diaphragmatic hernia that is rare in children. The association between Down's syndrome and Morgagni's hernia in children is also rare.¹ According to reports, 70% of Morgagni hernia patients are female in terms of gender ratio, and 90% of hernias are right-sided hernias in terms of common occurrence sites. In clinical practice, this type of hernia is very rare, accounting for 3% of all surgical treatments for diaphragmatic hernias.² Duodenal stenosis and duodenal atresia are common gastrointestinal abnormalities seen in individuals with Down's syndrome. While duodenal atresia typically presents early with immediate vomiting in newborns, the symptoms of duodenal stenosis can be much more subtle, which may lead to a delayed diagnosis.³ This article presents the case of a child with Down's syndrome who has both Morgagni's hernia and duodenal stenosis.

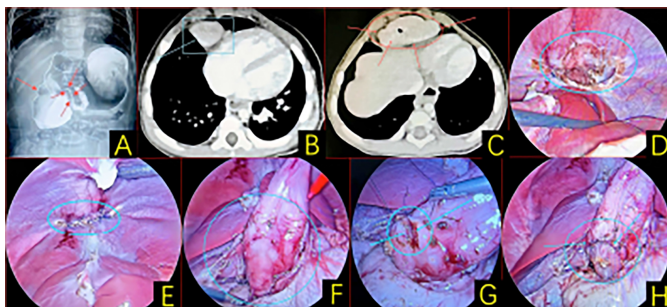


Figure 1: (A) Abdominal x-ray and contrast: Abdominal 'double bubble' sign, dilatation of duodenum bulb, narrowing of duodenum descending section, and low passage of contrast. (B, C) Abdominal CT: Liver and part of adipose tissue embedded in the thoracic cavity. (D) Morgagni's foramen defect was detected, and the left hepatic lobe and adipose tissue were herniated out. (E) The hernia contents were repositioned into the abdominal cavity, and the defect was closed using interrupted sutures. (F) Blunt separation of the descending and horizontal segments of the duodenum and a stenotic segment were found. (G, H) Resection of the stenotic segment and continuous suturing of the duodenal wall.

A one-year child with Down's syndrome was hospitalised several times since birth for recurrent respiratory infections and intermittent vomiting, which improved with an anti-infective treatment. Congenital pyloric stenosis and circumferential pancreas were suspected on gastrointestinal imaging and chest CT at the local hospital. Six days before admission, the child was presented with recurrent pneumonia, intermittent nausea, and vomiting and was diagnosed with severe pneumonia. At the time of admission, the family reported that the child had normal eating, sleeping, and bowel habits. Abdom-

inal x-rays and imaging showed a 'double bubble' sign, dilated duodenum in the bulbous part, narrowing in the descending part, and low passage of contrast medium (Figure 1A). Abdominal CT showed that the liver and part of the fatty tissue were embedded in the thoracic cavity (Figure 1B, C).

On admission, laparoscopic exploratory surgery was performed under general anaesthesia, which revealed a defect in the foramen of Morgagni and herniation of the left hepatic lobe and fatty tissue (Figure 1D). The contents of the hernia were repositioned into the abdominal cavity, and the defect was closed with separate interrupted sutures (Figure 1E). The descending and horizontal segments of the duodenum were bluntly separated, and a stenotic segment was found (Figure 1F), the stenotic segment was resected, and the duodenal wall was closed with continuous suture (Figure 1G, H). There was no recurrence of the disease after four months of postoperative follow-up. The child is now in good spirits and is eating and sleeping well.

It is rare for a child with Down's syndrome to have both a Morgagni hernia and a duodenal stenosis. Surgery is the only effective treatment. In children with Down's syndrome, the diagnosis may be hampered by their unique clinical features. In some cases, diagnostic ambiguity is due to limited clinical indications, outdated diagnostic tools and lack of physician awareness. Delays in diagnosis and treatment should be minimised.

COMPETING INTEREST:

The authors declared no conflict of interest.

AUTHORS' CONTRIBUTION:

YZ: Drafted, revised, and edited the manuscript.

QL: Conducted the questionnaire survey, collected and analysed the data, and interpreted the results.

RL: Conducted the questionnaire survey and collected the data.

All authors approved the final version of the manuscript to be published.

REFERENCES

1. Nanjundaswamy NH, Marulasiddappa V. Anaesthesia for a rare case of Down's syndrome with morgagni's hernia undergoing laparoscopic repair. *J Clin Diagn Res* 2015; **9(5)**:UD01-2. doi: 10.7860/JCDR/2015/13199.5869.
2. Arikan S, Dogan MB, Kocakusak A, Ersoz F, Sari S, Duzkoğlu Y, et al. Morgagni's hernia: Analysis of 21 patients with our clinical experience in diagnosis and treatment. *Indian J Surg* 2018; **80(3)**:239-44. doi: 10.1007/s12262-016-1580-0.
3. Nicholson MR, Acra SA, Chung DH, Rosen MJ. Endoscopic diagnosis of duodenal stenosis in a 5-month-old male infant. *Clin Endosc* 2014; **47(6)**:568-70. doi: 10.5946/ce.2014.47.6.568.

Yixin Zhang¹, Qian Liu¹ and Ruimin Liu²
.....

¹Department of Paediatric Surgery, The First Clinical Medical
College of Gansu, University of Chinese Medicine, Lanzhou,
China

²Department of Oral and Maxillofacial Surgery, Gansu Provin-
cial Hospital, Lanzhou, China
.....

Correspondence to: Dr. Ruimin Liu, Department of Oral and
Maxillofacial Surgery, Gansu Provincial Hospital, Gansu
Province, Lanzhou, China
E-mail: 15939955169@163.com
.....

Received: October 16, 2024; Revised: November 30, 2024;
Accepted: December 01, 2024

DOI: <https://doi.org/10.29271/jcpsp.2025.03.399>

.....