

A Large Hydatid Cyst in the Brain of a 10-year Child

Muhammad Ashraf¹, Shakeel Ahmed¹, Shahryar Ahmad² and Ashar Ahmad³

¹Department of Pediatric Neurosurgery, Children's Hospital and Institute of Child Health, Multan, Pakistan

²Department of Pediatric Surgery, Children's Hospital and Institute of Child Health, Multan, Pakistan

³Department of General Surgery, Nishtar Medical University, Multan, Pakistan

ABSTRACT

Hydatid cyst is the larval form of the parasite, *echinococcus granulosus*. We operated upon a case of a giant hydatid cyst in the left cerebral hemisphere of a 10-year male child. The patient presented to us with a history of headache, vomiting, vertigo and difficulty in walking. On the examination, there was hemiparesis on the right side and left-sided papilledema. The CT scan showed a large extra-axial cystic lesion in the left frontotemporoparietal area. Craniotomy and excision of the cyst by hydro-dissection was performed. The patient recovered uneventfully and was discharged. Albendazole was given postoperatively for a period of one month. The follow-up CT scan, performed after three months, showed complete resolution of the disease.

Key Words: Hydatid cyst, *Echinococcus granulosus*, Brain, Children.

How to cite this article: Ashraf M, Ahmed S, Ahmad S, Ahmad A. A Large Hydatid Cyst in the Brain of a 10-year Child. *J Coll Physicians Surg Pak* 2022; **32(04)**:538-540.

INTRODUCTION

Hydatid disease is caused by infestation of a parasite, *taenia echinococcus*.¹ Different wild carnivorous animals like dogs are the definitive host. These animals are infected by eating the involved organ of intermediate hosts like sheep and goats. Definitive host harbours the worms in its intestine. The ovas of the parasite are excreted with feces of the definitive host and contaminate vegetables and grass etc. Intermediate hosts like human beings, sheep, goats, and cattle are infested by eating these contaminated vegetables, grass and milk. Embryos are released from these eggs in the stomach of infected intermediate host and pass through the gut wall into the portal system and are entrapped in various organs like liver and lungs. Embryos may pass through capillaries of lungs and enter into systemic circulation and be entrapped in brain. These entrapped embryos develop into the larval stage, which is the cystic form of the disease. Symptoms of the disease develop according to the organ involved. In the case of involvement of brain, headache, fits, vomiting, focal neurological deficits, vertigo, walking difficulty, and vision deterioration are common symptoms.¹ Excision in toto without rupture is the goal of the successful surgical treatment.² Rupture of cyst before or during surgery may lead to anaphylaxis and recurrence of disease. Medical treatment with albendazole for one month after surgery is recommended.¹

We, herein, present a case of a 10-year male child with a large hydatid cyst in the brain that was removed in toto by hydro-dissection without any complications.

CASE REPORT

A 10-year shepherd child presented in the Outpatient Department with complaints of headache, vomiting, vertigo, and difficulty in walking due to right-sided weakness. The patient was admitted in the Pediatric Neurosurgical Department. History was taken and clinical examination, including general physical and systemic examination, was performed. On examination, power status was 5/5 on the left side and 3/5 on the right side. On fundoscopy, papilledema of grade 1 was noted on the left side. Necessary investigations like complete blood count (CBC), random blood sugar, and CT scan brain plain and with IV contrast were carried out. CT findings were in favour of hydatid cyst (Figure 1). Antibodies against *echinococcus* by immunoassay and MRI brain plain and with IV contrast were obtained to confirm the diagnosis. On laboratory investigation, total leucocyte count (TLC) was 9800/mm³ with eosinophils being 9%. CT and MRI scans showed well-circumscribed cystic lesion. Extra-axially placed in left frontotemporoparietal region with significant mass effect without ring enhancement and perifocal edema. On the basis of history, clinical examination, positive enzyme-linked immunosorbent assay (ELISA), and CT and MRI scans, the diagnosis of hydatid cyst was confirmed. Surgery was planned for craniotomy and excision of the cyst. The patient was examined by the anesthetist for fitness for the general anesthesia. Operation theatre and intensive care staff were informed one day before the surgery. Precautionary measures, such as hypertonic saline preparation, and hydrocortisone injection availability were assured. General anesthesia was given; and we proceeded for surgery in supine position with head tilt on

Correspondence to: Dr. Shakeel Ahmed, Department of Pediatric Neurosurgery, Children's Hospital and Institute of Child Health, Multan, Pakistan
E-mail: neuromashori@gmail.com

Received: January 22, 2020; Revised: April 20, 2020;

Accepted: June 21, 2020

DOI: <https://doi.org/10.29271/jcpsp.2022.04.538>

the right side. Left-sided frontotemporoparietal craniotomy was performed with the help of craniotome. U-shaped dural flap was raised, and the cyst was visualised as glistening yellowish-white structure. Dowling's technique of hydro-dissection was used to enucleate the cyst. Foley's catheter was gently placed in-between the cyst wall and brain parenchyma. Hypertonic normal saline was pushed gently with the help of bladder wash syringe. Head-side of the table was tilted down and Foley's catheter was advanced gradually; and the process of hydro-dissection was continued. The cyst was brought out slowly in toto and put into the bowl already placed for it (Figure 2). The patient was recovered from anesthesia and shifted to intensive care unit for three days; and later discharged after one week on albendazole, 10 mg/kg, twice daily, for one month. Follow-up CT scan was done after three months. The lesion was completely resolved.

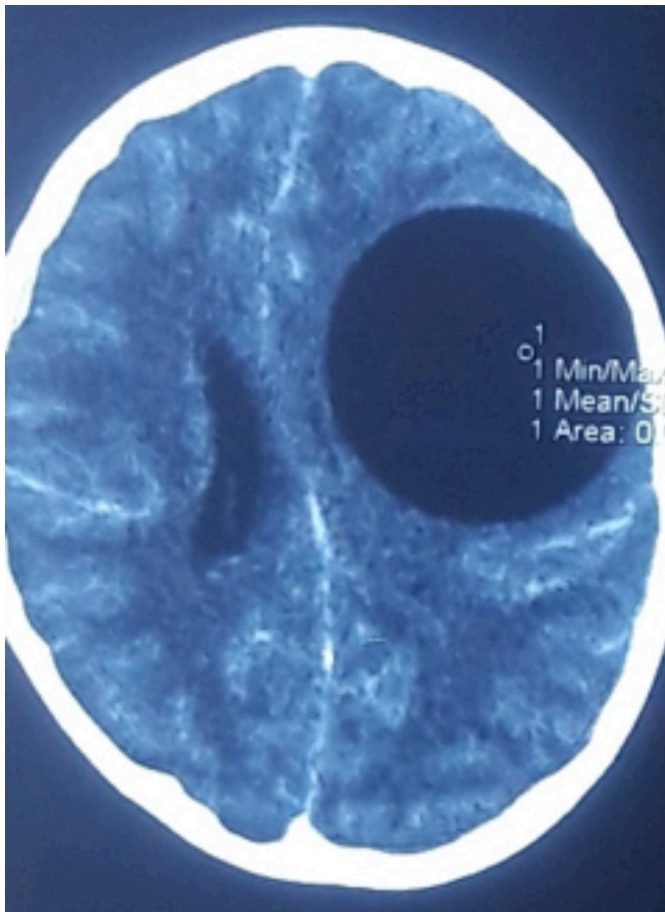


Figure 1: CT scan after intravenous contrast showing large, well-circumscribed cystic lesion in the left frontotemporoparietal region, suggestive of hydatid cyst.

DISCUSSION

Our patient was a 10-year shepherd by occupation, belonging to a cattle farming area. Hydatid disease is reported from all over the world but the main foci are sheep and goat farming areas of the subcontinent, Mediterranean regions, Australia, America and Africa. According to literature, this disease is more common in the pediatric age group in endemic areas, especially in those having contact with sheep and goats.¹

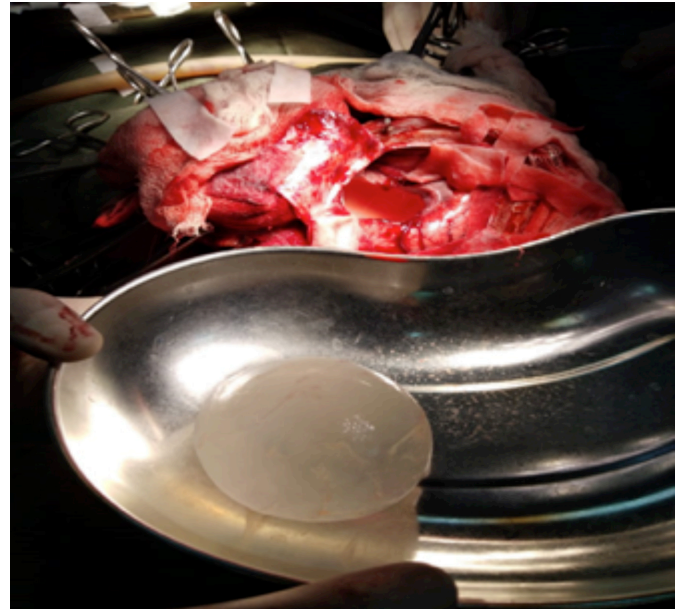

Figure 2: Intact hydatid cyst removed by hydro-dissection.

Children suffering from hydatid disease in other areas of the body like liver and lung were managed in this hospital; but it was the first case of hydatid cyst in brain, which is a rare location for this disease as compared to other areas of the body.³ Cyst was located in left fronto-parietotemporal region in our patient. Parietal lobe is involved more frequently as compared to other areas of the brain, as reported in the literature.⁴ Single cyst is more common but multiple cysts may also be present.⁵ Hydatid cyst grows slowly at a rate of 1-5 cm per year. Symptoms appear gradually, and aggravate when it attains a larger size.⁶ In our patient, there was a history of headaches for two years. Vomiting started four months later, followed by right-sided weakness and gait disturbance for the seven months. All the features of raised intracranial pressure including headache, vomiting, vertigo, fits, visual disturbances, focal neurological deficits, and papilledema are reported to be present in the patients with intracranial hydatid cyst.¹ Probable diagnosis was made on CT scan findings of well-circumscribed cystic lesion extra-axially placed in left frontotemporoparietal region with significant mass effect without perifocal edema and ring enhancement. All these findings are reported to be diagnostic of hydatid cyst in brain. MRI scan showed similar findings. Magnetic resonant spectroscopy and diffusion-weighted imaging help in diagnosis of intracranial hydatid cyst.⁷

Different surgical techniques, used for removal of hydatid cyst, are mentioned. One technique is direct puncture and aspiration of the cyst fluid through a small hole in the cyst wall and expulsion of the cyst through a small cortical incision over cyst. The other one is Dowling's technique of hydro-dissection, in which normal saline is irrigated gently between the cyst wall and brain parenchyma to deliver the cyst intact.²

We used the technique of hydro-dissection. Rupture of the cyst results in spillage of fluid and scoleces that may result in severe anaphylaxis immediately and recurrence of disease later on.²

Hypertonic saline or formalin can be injected into the cyst to kill scoleces but the leakage of fluid from the puncture site may take place, and vigilance is required.⁸ Albendazole is a broad-spectrum oral antihelminthic drug used in high doses (10 mg/kg twice daily) for at least one month.¹ We also used this drug in the same dose and duration. A follow-up CT scan may be performed any time after surgery. We performed a CT scan after three months of surgery and it showed complete resolution of the lesion.

In conclusion, this case illustrates that hydatid cyst should be included in the differential diagnosis of children living, in or coming from an endemic country, who present with an intracerebral cyst.

PATIENT'S CONSENT:

The informed consent was obtained from the patient to publish the data concerning this case.

CONFLICT OF INTEREST:

There is no conflict of interest.

AUTHORS' CONTRIBUTION:

MA: Supervised the research project including proofreading and formed the research methodology.

SA: Performed the surgery, conducted literature review and wrote up the paper.

SA, AA: Involved in the treatment and surgery of the patient, taking pictures, data collection, analysis, and reference formatting of the paper.

REFERENCES

1. Philip RF, Miguel MC, Clinton AW. *Echinococcosis*: Nelson text book of pediatrics 20th edition 2016 volume 1 (ii) 1753-56.
2. Yusuf I, Yusuf T, Halil I. Cerebral hydatid cysts: Technique and pitfalls of surgical management. *Sece, Engin Gonul, Neurosurg Focus* 2008; **24(6)**:E15. doi: 10.3171/FOC/2008/24/6/E15.
3. Dipika S, Bina B, Veena S. A case of intracranial hydated cyst in a 10 year old child. *Sri Lanka J Child Health* 2016; **45(1)**:50-1.
4. Ali M, Mahmood K, Khan P. Hydatid cystsof the brain. *J Ayub Med College Abbottabad* 2009; **21(3)**:152-4.
5. Uma H, Rakesh G, Alka G, Seema W, Mridula P. Anesthetic concerns for large intracranial cyst excision: Expect the unexpected. *Clin Pract* 2012; **2(2)**:e50.
6. Duishanbai S, Jiafu D, Guo H, Liu C, Liu B, Aishalong M, et al. Intracranial hydatid cyst in children: Report of 30 cases. *Childs Nerv Syst* 2010; **26(6)**:821-7. doi: 10.1007/s00381-009-1008-2.
7. Andronikou S, Welmanan CJ, Kader E. Classic and unusual appearance of hydatid cyst in children. *Paediatric Radiol* 2002; **32(11)**:817-28. doi: 10.1007/s00247-002-0785-5.
8. Tuzun Y. Solmaz I, Sengul G, IZCI Y. The complications of cerebral hydatid cyst surgery in children. *Childs Nerv Syst* 2010; **26(1)**:47-51. doi: 10.1007/s00381-009-0970-z.

