

Prognostic Value of Different Imaging Scores Based on CTA in Endovascular Treatment of Acute Basilar Artery Occlusion

Yongkang Wang, Tianlong Pei, Wenjie Wu, Xijun Gong and Longsheng Wang

Department of Radiology, The Second Affiliated Hospital of Anhui Medical University, Hefei, China

ABSTRACT

Objective: To investigate the prognostic factors of intravascular therapy for acute basilar artery occlusion (aABO), and to evaluate the prognostic value of various imaging scores based on CTA.

Study Design: Observational study.

Place and Duration of Study: Department of Radiology, The Second Affiliated Hospital of Anhui Medical University, China, from January 2018 to January 2022.

Methodology: Clinical data of 120 patients who underwent intravascular therapy for aABO were analysed retrospectively. The patients were divided into the poor prognosis group (n=54) and the good prognosis group (n=66) according to the score of the modified rankin scale (mRS) 90 days after the intervention. General clinical parameters of patients and the results of three imaging scores based on CTA *i.e.* basilar artery CT angiography (BATMAN) score, posterior circulation collateral circulation score (pc-CS), and posterior circulation CT angiography (pc-CTA) score, were taken as independent variables. Prognosis was taken as dependent variable. Univariate and unconditional binary logistic regression analyses were carried out respectively.

Results: Multivariate logistic regression analysis showed that preoperative National Institutes of Health Stroke Scale (NIHSS) score (OR=1.063, 95%CI: 1.014~1.114, p=0.011), pc-CTA score (OR=17.183, 95%CI: 13.515~84.010, p<0.001), BATMAN score (OR=0.393, 95%CI: 0.229~0.675, p=0.001), and pc-CS score (OR=0.374, 95%CI: 0.206~0.682, p=0.001) were independent factors affecting the short-term prognosis of patients with aABO. ROC curve analysis showed that the area under the curve (AUC) of the Batman score, pc-CS score and pc-CTA score were 0.900, 0.864 and 0.842 respectively, and the cut-off values were 4.5, 4.5 and 1.5 respectively.

Conclusion: Preoperative high NIHSS score and high pc-CTA score were independent risk factors for poor prognosis of patients with aABO after intravascular therapy, while high BATMAN score and high pc-CS score were protective factors for prognosis.

Key Words: Acute basilar artery occlusion, Intravascular therapy, Basilar artery CT angiography score, Posterior circulation collateral circulation score, Posterior circulation CT angiography.

How to cite this article: Wang Y, Pei T, Wu W, Gong X, Wang L. Prognostic Value of Different Imaging Scores Based on CTA in Endovascular Treatment of Acute Basilar Artery Occlusion. *J Coll Physicians Surg Pak* 2022; **32(11)**:1392-1397.

INTRODUCTION

Acute basilar artery occlusion (aABO) is an acute cerebrovascular occlusive disease. Although it accounts for only about 5% of all strokes,¹ if early effective intervention is not available, its disability rate and mortality rate are as high as about 90%.² For aABO, the treatment methods mainly include intravenous thrombolysis and intravascular therapy (mechanical thrombectomy, arterial thrombolysis, and bridging therapy).^{3,4} Recent studies have shown that intravenous thrombolysis often cannot effectively recanalize the occluded vessels, while the research on intravascular therapy mainly focuses on anterior circulation occlusive diseases.⁵

The clinical symptoms of aBAO are complex and diverse, and imaging findings are the main diagnostic basis, of which DSA is the gold standard for its diagnosis. Considering the invasiveness of DSA, three CTA-based imaging scoring systems represented by BATMAN, pc-CS and pc-CTA have been gradually applied in the diagnosis and prognostic evaluation of aBAO in recent years. The value of evaluating the short-term efficacy of endovascular therapy in patients has not been validated effectively. The aim of this study was to analyse the influencing factors of short-term efficacy of endovascular therapy in patients with aBAO, and the predictive value of three imaging scores for efficacy.

METHODOLOGY

The subjects were patients hospitalised for aABO in the Second Affiliated Hospital of Anhui Medical University from January 2018 to January 2022. Inclusion criteria were age ≥ 18 years old, isolated aBAO confirmed by intraoperative DSA, time from the onset of clinical symptoms of aABO to the beginning of intravascular treatment being less than 24 hours, with complete clinical

Correspondence to: Dr. Longsheng Wang, Department of Radiology, The Second Affiliated Hospital of Anhui Medical University, Hefei, China
E-mail: wlshfay@163.com

Received: June 22, 2022; Revised: August 29, 2022;

Accepted: September 27, 2022

DOI: <https://doi.org/10.29271/jcpsp.2022.11.1392>

data and standardised follow-up available after the operations. Exclusion criteria were patients with cerebral haemorrhage or brain tumour confirmed by CT or MRI, active bleeding or severe heart, liver, lung, and other organ failure who could not undergo endovascular treatment, history of neurological dysfunction in the past, and a history of severe iodine allergy in the past.

The patient was placed supine on the DSA examination bed. After general anaesthesia, the right femoral artery was successfully punctured by the modified Seldinger method, and angiography of the aortic arch and supraarch was performed to determine the location of basilar artery occlusion. The microcatheter was used to superselect the cannula to cross the stenotic segment, and the Solitaire FR self-expanding stent (4mm × 20mm or 6mm × 30mm) was slowly placed along the microcatheter. Finally, the blood flow was reviewed by angiography. For patients with a large amount of thrombus indicated by intraoperative angiography, negative pressure suction can be used to remove the thrombus. The 5F Navien catheter is placed at the vascular occlusion, and the end of the catheter is connected to a 20ml syringe for negative pressure suction. After mechanical thrombectomy, the angiographic review was performed again. If the degree of vascular stenosis was greater than 70%, balloon dilation was performed. If stenosis or dissection was still formed after dilation, the above self-expanding intravascular stent was further placed. Tirofiban 5~10ml was injected through a microcatheter during the operation. The patients were treated with dual antiplatelet therapy within three months after operation and changed to oral aspirin 100 mg/d single antiplatelet therapy after three months.

Three CTA-based imaging scores were used. BATMAN score,⁶ it is a 10 -point semiquantitative scoring system based on CTA, including collateral quality and thrombus burden. It assigns 1 point to each unobstructed segment of any intracranial vertebral artery, each segment of the basilar artery (the proximal segment, the middle segment and the distal segment), and each P1 segment of the posterior cerebral artery. Two points were given for each patent posterior communicating artery (PCoM). If the retrograde blood flow can reach the distal basilar artery through the P1 segment, score one point for the dysplastic PCoM (diameter less than 1mm), or three points for each fetal PCoM. The total score is 10 points, and the higher the score, the better the circulation filling. The pc-CS score allocates collaterals a maximum of 10 points; 1 point for each patent posterior inferior cerebellar artery, anterior inferior cerebellar artery, and superior cerebellar artery, 1 point for each patent PCoM smaller than the ipsilateral P1 segment of the posterior cerebral artery, and 2 points for each PCoM with a calibre equal or larger than the ipsilateral P1 segment.⁷ The higher the score, the better the posterior circulation compensation. The pc-CTA score, which mainly evaluates the volume of posterior circulation thrombus by semi-quantitative score, with a total score of 6 points, 0 points for vascular patency, and 6 points for complete posterior circulation occlusion.⁸ The higher score indicates a larger thrombus volume and a more severe posterior circulation occlusion.

The relevant clinical data of the patients were accessed through the electronic case system, Data of the patients including gender, age, BMI, laboratory tests, (blood glucose, blood lipids, platelet count, D-dimer), stroke-related risk factors hypertension history, diabetes history, smoking history, and atrial fibrillation; preoperative NIHSS score, BATMAN score, pc-CS score and pc-CTA score, and other results were entered into Excel form and double-entered for error correction. During the outpatient follow-up within 90 days after the operation, the neurological function of the patients was evaluated by the mRS score. The mRS score ≤ 2 indicated a good prognosis, and a mRS score ≥ 3 indicated a poor prognosis. Using modified thrombolytic therapy for cerebral infarction (mTICI) blood flow grading criteria to evaluate the recanalisation of responsible vessels after endovascular therapy, in which grades 0-2a are poor recanalisation, and grades 2b/3 are recanalisation.⁹ The differences of related indicators between the two groups were compared, and those with statistically significant differences were further subjected to unconditional binary logistic regression analysis.

Data analysis was performed using IBM-SPSS 26.0 software package, Kolmogorov-Smirnov method, and Shapiro-Wilk method are used to test the normality. If $p \geq 0.05$, the data is considered to conform to the normal distribution. Measurement data were represented by ($\bar{x} \pm s$) and statistically analysed using the Student's-t test of two independent samples. The count data were described by frequency and percentage and analysed by χ^2 test. Non-normally distributed data were expressed by Median (IQR), and analysed by Mann-Whitney U test. Unconditional binary logistic regression analysis was used for multivariate analysis. The diagnostic value of BATMAN score, pc-CS score and pc-CTA score was analysed by ROC curve. A value of $p < 0.05$ is considered statistically significant for all tests.

RESULTS

A total of 120 patients with aABO were included in this study. The age ranged from 35 to 86 years, with an average of 65.5 ± 10.3 years. There were 91(75.83%) males and 29(24.16%) females. The time from the onset of symptoms to the beginning of intravascular therapy (OPT) was 1.5h ~22.5h, with an average of (8.6 ± 2.3) h. According to the mRS score within 90 days after the operation, 66 patients in the group with good prognosis, accounting for 55%. There were 54 cases in the poor prognosis group, accounting for 45%. The preoperative NIHSS, BATMAN, pc-CS, and pc-CTA scores were 20.5 , 5.95 ± 2.25 , 5.45 ± 2.15 , and 2.05 ± 1.15 , respectively. Postoperative mTICI blood flow classification showed 110 (91.67%) cases of grade 2b/3, 4 (3.33%) cases of symptomatic cerebral haemorrhage, and 6(5%) cases of death.

The differences in gender, age, BMI, blood sugar, blood lipid, D-dimer, history of hypertension, history of diabetes, smoking history, atrial fibrillation, OPT, occlusion, thrombolysis, preoperative NIHSS, BATMAN, pc-CS, and pc-CTA were compared between the two groups. The results showed that there were significant differences in age, preoperative NIHSS score, BATMAN score, pc-CS score, and pc-CTA score ($p < 0.05$, Table I).

Table I: Univariate analysis of poor prognosis of patients with aABO after intravascular therapy [(x±s), n (%), M (p₂₅, p₇₅)].

Parameter	Good prognosis group (n=66)	Poor prognosis group (n=54)	t/Z/χ ² value	p-value
Age (years)	55.88±8.388	64.57±9.58	5.298	<0.001
Gender (male / female)	53 (80.30%) / 13 (19.70%)	38 (70.37%) / 16 (29.63%)	1.599	0.206
BMI (Kg/m ²)	25.26±2.97	24.70±3.21	0.986	0.326
PLT (10 ⁹ /L)	215.36±32.46	217.43±29.80	0.359	0.720
D-dimer (μg/L)	104.88±18.33	103.74±18.86	0.335	0.738
Blood sugar (mmol/L)	6.55±1.92	6.11±1.95	1.223	0.224
TC (mmol/L)	4.01±0.76	4.33±1.39	1.601	0.133
TG (mmol/L)	1.46±0.40	1.35±0.27	1.672	0.086
History of hypertension	51 (77.27%)	43 (79.63%)	0.097	0.755
Diabetes history	20 (30.30%)	21 (38.89%)	0.973	0.324
Smoking history	39 (59.09%)	35 (64.81%)	0.412	0.521
aABO location			0.757	0.685
Proximal section	28 (42.42%)	22 (40.74%)		
Middle section	14 (21.21%)	15 (27.78%)		
Distal section	24 (36.36%)	17 (31.48%)		
Intravenous thrombolysis	4 (6.06%)	9 (16.67%)	3.459	0.063
OPT (h)	8.09±2.78	9.08±2.96	1.879	0.063
Preoperative NIHSS score	18.50 (5.00,25.00)	25.50 (8.00,30.00)	-2.347	0.019
BATMAN score	7.17±1.80	4.39±1.30	9.494	<0.001
pc-CS score	6.35±1.09	4.37±1.89	7.186	<0.001
pc-CTA score	1.48±0.50	2.67±0.93	8.861	<0.001
Postoperative mTICI blood flow			-	>0.99
Grade 0-2a	6 (9.09%)	4 (7.41%)		
Grade 2b/3	60 (90.91%)	50 (92.59%)		

P: Mann-Whitney U test was used for preoperative NIHSS score; χ² test was used for gender, risk factors of cerebral infarction, and aABO position; Fisher's exact test was used for postoperative mTICI blood flow; t-test was used for other parameters.

Table II: Multivariate analysis of prognosis of patients with aABO after intravascular therapy.

Independent variable	B value	SE	waldχ ²	p-value	OR value	95% CI
Preoperative NIHSS score	0.061	0.024	6.460	0.011	1.063	1.014 ~ 1.114
BATMAN score	-0.934	0.276	11.455	0.001	0.393	0.229 ~ 0.675
pc-CS score	-0.982	0.306	10.318	0.001	0.374	0.206 ~ 0.682
pc-CTA score	2.844	0.819	12.336	<0.001	17.183	3.515 ~ 84.010

Table III: Analysis of the diagnostic efficacy of three CTA-based imaging scores for prognosis.

Variable	AUC	p-value	95%CI	Cut-off value	Sensitivity (%)	Specificity (%)
BATMAN score	0.900	<0.001	0.839 ~ 0.960	4.5	87.9	92.6
pc-CS score	0.864	<0.001	0.788 ~ 0.940	4.5	78.8	87.0
pc-CTA score	0.842	<0.001	0.771 ~ 0.913	1.5	92.6	51.5

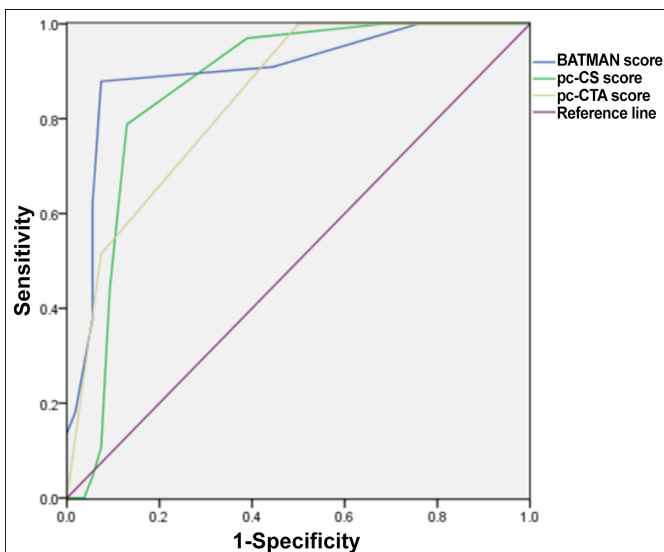


Figure 1: ROC curves of three imaging scores for prognosis prediction.

The above-mentioned univariate analysis meaningful variables [age, preoperative NIHSS score, BATMAN score, pc-CS score, and pc-CTA score] were used as independent variables, and postoperative conditions (1 for poor prognosis and 0 for good prognosis) were used as dependent variables. As the dependent variable, unconditional binary logistic regression analysis was performed, and the stepwise backward method was used to fit the optimal model for analysis. The results showed that the preoperative NIHSS score (OR=1.063, 95% CI: 1.014~1.114, p=0.011), pc-CTA score (OR=17.183, 95% CI: 3.515~84.010, p <0.001) were the most important factors in the vascularity of aABO patients. Independent risk factors for poor prognosis after internal therapy (all OR >1, all p<0.05), while BATMAN score (OR=0.393, 95% CI: 0.229-0.675, p=0.001), pc-CS score (OR=0.374, 95% CI: 0.206-0.682, p=0.001) was a protective factor for prognosis (all OR <1, all p<0.05, Table II).

The ROC curves of three imaging scores to predict the poor prognosis of aABO patients after endovascular treatment

were drawn respectively. At this time, the area under the curve (AUC) was 0.900, 0.864, and 0.842, respectively; the sensitivity was 87.9%, 78.8% and 92.6%, and the specificity was 92.6%, 87.0%, and 51.5%, respectively (Table III, Figure 1).

DISCUSSION

Acute basilar artery occlusion (aABO) is an uncommon neurological disease that seriously affects the health of patients. Previous BASICS clinical trials have reported that the fatality rate of patients with severe aABO is as high as 54.4% using traditional antithrombotic therapy such as intravenous thrombolysis alone, while only those with good prognosis are accounting for 6.3%.¹⁰ The posterior circulation has a special physiological structure. On the one hand, the occlusion of the main basilar artery reduces the perfusion pressure at the confluence of the posterior cerebral arteries, which often leads to the reverse filling of the posterior communicating artery, which makes the branches of the superior cerebellar artery and the perforating arteries unobstructed, thereby maintaining blood flow to the upper cerebellum, midbrain, and thalamus supply. On the other hand, the anterior spinal artery supplies blood to the posterior inferior cerebellar artery as another collateral circulation pathway. Considering the abundant collateral circulation in the posterior circulation and the good compensatory ability of ischemic stroke, early and aggressive endovascular therapy to restore blood supply in patients with aABO may greatly benefit the patients. In recent years, studies have shown that early endovascular treatment for complete vascular recanalisation in aABO patients can effectively save the brain tissue of the ischemic penumbra, significantly reduce the mortality and morbidity rate, and greatly improve the patient's good prognosis rate.^{11,12} Important complications such as ischemia-reperfusion injury bleeding are lower. In this study, all patients with aABO completed intravascular treatment within 24 hours, with a good prognosis accounting for 55.0%, while symptomatic intracerebral haemorrhage and mortality accounted for only 4.17% and 5.00% respectively.

At present, there is still a lack of research on the related factors of the prognosis of patients with aABO endovascular treatment, especially the ability of CTA-based imaging quantitative score to affect the prognosis of patients with aABO is still uncertain. CTA is a rapid and non-invasive imaging examination method, which can effectively evaluate the cerebral blood vessels of patients, especially the collateral circulation at the lesion site. Therefore, the evaluation of vascular lesions in aABO patients based on CTA imaging score has the characteristics of simplicity and systematicness and may be widely used in the decision-making of aABO treatment. The BATMAN score was developed by Alemseged to assess its predictive value for

clinical outcomes in patients with aABO. The BATMAN score includes collateral circulation and thrombus burden. Alemseged found that the BATMAN score was significantly correlated with clinical outcomes, and ROC curve analysis showed that AUC=0.81, and BATMAN <7 points were associated with poor clinical outcomes.¹³ According to the research of Yang *et al.*, the ROC analysis showed that the AUC was 0.722, and the optimal cut-off point was 3 points.¹⁴ Multivariate logistic regression analysis showed that BATMAN score higher than 3 was associated with good clinical prognosis. In this study, the BATMAN score was also shown to be significantly associated with clinical outcomes. The ROC curve analysis AUC was 0.900 with a cut-off value of 4.5 points. This is not the same as the results reported in the above-mentioned studies. There may be two reasons for this difference. First, in this study, patients with aABO received endovascular therapy earlier, on an average of 8.6 ± 2.3 hours, and patients were more likely to benefit from this early endovascular therapy. Second, different studies define good outcomes differently. In Alemseged's study, an mRS score of 0-3 was considered a good prognosis, whereas, in this study, an mRS score of 0-2 was considered a good prognosis.

The pc-CS score is another protective factor for the clinical prognosis of patients with aABO, and as the pc-CS score increases, the likelihood of a patient's clinical prognosis increases. Dias' study showed that endovascular therapy is a very effective treatment for aABO, the area under the ROC curve of pc-CS score for good clinical prognosis was 0.80, and pc-CS score was considered to be the only independent predictor.¹⁵ In this study, multivariate Logistic regression analysis showed that the pc-CS score was an independent protective factor for the prognosis of patients with aABO after endovascular treatment. The area under the ROC curve was 0.864, the best cut-off value was 4.5 points, and the sensitivity and specificity were 78.8% and 87.0%, respectively, which were basically consistent with previous studies.^{16,17} The pc-CTA score was originally developed by Ros *et al.*, as a scoring tool for evaluating prognosis after mechanical thrombectomy in 15 aABO patients clinical outcomes.⁸ The results of this study showed that, different from the BATMAN score and the pc-CS score, the pc-CTA score was an independent risk factor for poor prognosis. The higher the pc-CTA score, the worse the prognosis. In this study, when the pc-CTA score was less than or equal to 1.5, the area under the ROC curve for diagnosing poor prognosis was 0.842, and its sensitivity was as high as 92.6%. In addition, this study also showed that the preoperative NIHSS score was another independent risk factor affecting the poor prognosis of patients with aABO after endovascular therapy, which was consistent with the study of Cao *et al.*¹⁸ The study by Kong *et al.* also showed that active endovascular therapy was associated with a good prognosis of patients.¹⁹ Baseline NIHSS score is an independent factor for postoperative

outcomes, and a lower NIHSS score predicts a better prognosis for patients.^{20,21}

This study has some limitations. On the one hand, as a single-centre study, the sample size is relatively small. On the other hand, various scoring standards are mainly based on subjective evaluation. Although the research method of comprehensive evaluation and averaging by multiple researchers is adopted, the possibility of individual errors cannot be completely ruled out.

CONCLUSION

In conclusion, preoperative NIHSS score, BATMAN score, pc-CS score and pc-CTA score are independent influencing factors of aABO patients after endovascular treatment. The three imaging scores based on CTA have good predictive performance for the prognosis of aABO patients and should be actively promoted and applied in clinical practice.

FUNDING:

2019 Provincial Quality Engineering Project of Colleges and Universities (No. 2019jyxm 1005).

ETHICAL APPROVAL:

This study was approved by the ethics committee of the hospital.

PATIENTS' CONSENT:

Written informed consents were obtained from all patients.

COMPETING INTEREST:

The authors declared no competing interest.

AUTHORS' CONTRIBUTION:

YW: Research design, statistical analysis, and article writing. TP, WW, XG: Disease diagnosis, personnel coordination, and postoperative follow-up.

LW: Funds management, research design, and article writing.

All the authors have approved the final version of the manuscript to be published.

REFERENCES

- Mattle HP, Arnold M, Lindsberg PJ, Schonewille WJ, Schroth G. Basilar artery occlusion. *Lancet Neurol* 2011; **10**(11):1002-14. doi: 10.1016/S1474-4422(11)70229-0.
- Shu L, Salehi Ravesh M, Jansen O, Jensen-Kondering U. Stent retriever thrombectomy potentially increases the recanalisation rate, improves clinical outcome, and decreases mortality in acute basilar occlusion: A systematic review and meta-analysis. *Cerebrovasc Dis Extra* 2019; **9**(2):46-56. doi: 10.1159/000499665.
- Yoon W, Kim SK, Heo TW, Bake BH, Lee YY, Kang HK. Predictors of good outcome after stent-retriever thrombectomy in acute basilar artery occlusion. *Stroke* 2015; **46**(10): 2972-5. doi: 10.1161/STROKEAHA.115.010840.
- Mokin M, Sonig A, Sivakanthan S, Ren Z, Elijevich L, Arthur A, et al. Clinical and procedural predictors of outcomes from the endovascular treatment of posterior circulation strokes. *Stroke* 2016; **47**(3): 782-8. doi: 10.1161/Strokeaha.115.011598.
- Powers WJ, Rabinstein AA, Ackerson T, Adeoye OM, Bambakidis NC, Becker K, et al. 2018 guidelines for the early management of patients with acute ischemic stroke: A guideline for healthcare professionals from the American heart association/American stroke association. *Stroke* 2018; **49**(3):e46-e110. doi: 10.1161/STR.0000000000000158.
- Yang H, Ma N, Liu L, Gao F, Mo D, Miao Z. The Basilar Artery on Computed Tomography Angiography Score for Acute Basilar Artery Occlusion Treated with Mechanical Thrombectomy. *J Stroke Cerebrovasc Dis* 2018; **27**(6):1570-4. doi: 10.1016/j.jstrokecerebrovasdis.2018.01.007.
- Wu D, Guo F, Liu D, Hu R, Shen Z, Yang Y, et al. Characteristics and prognosis of acute basilar artery occlusion in minor to moderate stroke and severe stroke after endovascular treatment: A multicenter retrospective study. *Clin Neurol Neurosurg* 2021; **202**:106504. doi: 10.1016/j.clineuro.2021.106504.
- Ros V, Meschini A, Gandini R, Giudice CD, Garaci F, Stanzione P, et al. Proposal for a vascular computed tomography-based grading system in posterior circulation stroke: A single-center experience. *J Stroke Cerebrovasc Dis* 2016; **25**(2):368-77. doi: 10.1016/j.jstrokecerebrovasdis.2015.10.008.
- Tan Z, Parsons M, Bivard A, Sharma G, Mitchell P, Dowling R, et al. Optimal tissue reperfusion estimation by computed tomography perfusion post-thrombectomy in acute ischemic stroke. *Stroke* 2021; **52**(12):e760-e3. doi: 10.1161/STROKEAHA.121.034581.
- Schonewille WJ, Wijman CA, Michel P, Rueckert CM, Weimar C, Mattle HP, et al. Treatment and outcomes of acute basilar artery occlusion in the Basilar Artery International Cooperation study (BASICS): A prospective registry study. *Lancet Neurol* 2009; **8**(8):724-30. doi: 10.1016/S1474-4422(09)70173-5.
- Li WL, Hong WJ, Wang E, Jiang YQ. RAPID Software to the clinical application value of Acute Basilar Artery occlusion with endovascular treatment. *J Stroke Cerebrovasc Dis* 2021; **30**(12):106147. doi: 10.1016/j.jstrokecerebrovasdis.2021.106147.
- Sun X, Yang Q, Ju XY, Wang SL, Qiu ZM, Sang HF, et al. Plasma homocysteine and prognosis of patients with recanalisation after Acute Basilar Artery Occlusion: An analysis from the acute basilar artery occlusion study (BASILAR) nationwide prospective registry. *Curr Neurovasc Res* 2021; **18**(2):197-203. doi: 10.2174/1567202618666210708102502.
- Alemseged F, Shah DG, Diomedi M, Sallustio F, Bivard A, Sharma G, et al. The basilar artery on computed tomography angiography prognostic score for basilar artery occlusion. *Stroke* 2017; **48**(3):631-7. doi: 10.1161/

STROKEAHA.116.015492.

14. Yang H, Ma N, Liu L, Gao F, Mo DP, Miao ZR, *et al.* The basilar artery on computed tomography angiography score for acute basilar artery occlusion treated with mechanical thrombectomy. *J Stroke Cerebrovasc Dis* 2018; **27(6)**: 1570-4. doi: 10.1016/j.jstrokecerebrovasdis.2018.01.007.
15. Dias FA, Castro-Afonso LH, Zotin MCZ, FF, Filho RKDVM, Camilo MR, *et al.* Collateral scores and outcomes after endovascular treatment for basilar artery occlusion. *Cerebrovasc Dis* 2019; **47(5-6)**:285-90. doi: 10.1159/000502083.
16. Wu D, Guo F, Liu D, Hu R, Shen ZK, Yang YW, *et al.* Characteristics and prognosis of acute basilar artery occlusion in minor to moderate stroke and severe stroke after endovascular treatment: A multicenter retrospective study. *Clin Neurol Neurosurg* 2021; **202**:106504. doi: 10.1016/j.clineuro.2021.106504.
17. van der Hoeven EJ, McVerry F, Vos JA, Algra A, Puetz V, L Jaap Kappelle LJ, *et al.* Collateral flow predicts outcome after basilar artery occlusion: The posterior circulation collateral score. *Int J Stroke* 2016; **11(7)**:768-75. doi: 10.1177/1747493016641951.18.
18. Cao J, Mo Y, Chen R, Shao HM, Xuan JG, Peng Y, *et al.* Predictors of functional outcome and mortality in endovascular treatment for acute basilar artery occlusion: A single-centre experience. *Front Neurol* 2021; **12**:731300. doi: 10.3389/fneur.2021.731300.
19. Kong WL, Yuan JJ, Huang JC, Song JX, Zhao CH, Sang HF, *et al.* Outcomes of endovascular therapy in acute basilar artery occlusion with severe symptoms. *JAMA Netw Open* 2021; **4(12)**:e2139550. doi: 10.1001/jamanetworkopen.2021.39550.
20. Monteiro A, Cortez GM, Waqas M, Rai HH, Baig AA, Dossani RH, *et al.* Comparison of effectiveness and outcomes among different thrombectomy techniques in acute basilar artery occlusion: A dual-center experience. *Neurosurg Focus* 2021; **51(1)**:E8. doi: 10.3171/2021.4.FOCUS21114.
21. Tajima Y, Hayasaka M, Ebihara K, Yokoyama D, Suda I. Predictors of very poor outcome after mechanical thrombectomy for acute basilar artery occlusion. *Neurol Med Chir (Tokyo)* 2020; **60(10)**:507-13. doi: 10.2176/nmc.aa.2020-0148.

