

A New Method in Transcanal Medial Grafting Type-I Cartilage Tympanoplasty

Harun Kucuk

Department of Otolaryngology, Istinye University Medical Park Hospital, Gaziosmanpasa, Istanbul, Turkiye

ABSTRACT

Objective: To determine the surgical results of a modified technique for the tympanic membrane (TM) perforation repair and to compare this new technique with the traditional methods.

Study Design: An interventional study.

Place and Duration of the Study: Department of Otolaryngology, Medicana International Hospital, Samsun, Turkiye, from June 2019 till June 2021.

Methodology: The study was conducted with 24 patients who underwent cartilage tympanoplasty. Pure-tone audiometry (PTA), preoperative and postoperative air and bone conduction hearing levels were determined. The mean values of air and bone conduction and air-bone gap (ABG) were recorded.

Results: Postoperatively, 23 grafts were intact, and one was perforated, perforation secondary to otomycosis in the first month post-operatively. Eight patients had previous unsuccessful tympanoplasty history. These patients' tympanic grafts were intact with this technique. Surgical success rate was 96.0%. Postoperative hearing gain was 12,8 dB. Functional success rate was 88.0%. Mean surgery time was 30 minutes. Patients easily continued their lives in one-week time after the surgery.

Conclusion: The new modified cartilage tympanoplasty method had high surgical success, and good audiometric results were obtained.

Key Words: Type-I cartilage, Tympanoplasty, Transcanal medial grafting, Tympanomeatal flap elevation.

How to cite this article: Kucuk H. A New Method in Transcanal Medial Grafting Type-I Cartilage Tympanoplasty. *J Coll Physicians Surg Pak* 2024; **34(02)**:226-229.

INTRODUCTION

Tympanoplasty is defined as repair of perforated tympanic membrane with/without reconstruction of ossicular chain. It was firstly described by Zollner and Wullstein in 1952.¹ Since the description of tympanoplasty, various surgical methods and graft materials had been described to repair tympanic membrane (TM) perforation. During the development of tympanoplasty techniques; temporalis fascia, perichondrium, and cartilage had been used for TM perforation repair as a graft material.²⁻⁴ In both underlay and overlay approaches with temporalis fascia and perichondrium grafts, the successful closure rate of TM and improvement of hearing results are about 60-90%.^{4,5} These techniques require external canal incision and tympanomeatal flap elevation for interaction between membrane and ossicles. Gross et al. described adipose plug for small perforations as a graft material for TM repair.⁶

In 1998, Eavey described "inlay butterfly cartilage tympanoplasty" as a new technique with tragal cartilage.⁷ Ghanem et al. performed this technique for large perforations with successful closure rate.⁸

During the development of surgical techniques and graft materials, the new era opened with using otologic endoscopes at tympanoplasty. Thus, transcanal approaches were increasingly and widely used. Along with these developments, many grafting techniques and their modifications had been described. Today, one of the most commonly used techniques is the medial grafting technique and its modifications.

In this study, a modified technique for TM perforation repair was used. This was transcanal medial grafting cartilage tympanoplasty with no tympanomeatal flap elevation and auditory canal incision. It aimed to introduce this modified technique and discuss the surgical results of this technique while comparing it with the other techniques.

METHODOLOGY

This observational study was carried out at Samsun Medicana International Hospital following an approval from the Institutional Review Board (IRB No. 12.06.2019/1). The study was conducted on 24 patients aged above 18 years who underwent cartilage tympanoplasty between June 2019 and June 2021. All patients' gender, age, symptom duration, and previous surg-

Correspondence to: Dr. Harun Kucuk, Department of Otolaryngology, Istinye University Medical Park Hospital, Gaziosmanpasa, Istanbul, Turkiye
E-mail: drharunk@gmail.com

Received: May 06, 2023; Revised: October 05, 2023;

Accepted: October 06, 2023

DOI: <https://doi.org/10.29271/jcpsp.2024.02.226>

ical history were acquired through the medical records. Pure tone audiometric examination, computed tomography of temporal bone, and microscopic middle ear examination were routinely performed before the tympanoplasty. Pure-tone audiometry (PTA) values were determined for preoperative and postoperative 0.5, 1, 2, and 4 kHz at air and bone conduction hearing level. The mean values of air and bone conduction and air-bone gap (ABG) were recorded. Postoperative mean hearing gain was calculated. The patients with chronic otitis media with cholesteatoma or mastoid disease and small perforations were excluded from the study. TM perforation size larger than 50% were defined as large perforations. Large and subtotal perforations were operated with this technique. Also, patients who had previous tympanic membrane repair with temporalis fascia that resulted in unsuccessful surgical result and had no mastoid disease were operated with this approach. All patients were operated under the general anaesthesia. Patients were hospitalised for a day and subsequently underwent a series of postoperative follow-up at the clinic. They were observed on the seventh day for removal of sponge stone from external auditory canal, at first month for examination of tympanic membrane to observe the graft integrity, and sixth month for audiometry and yearly examination of graft. The surgical success, both technically and anatomically, was defined as achieving an intact repaired tympanic membrane.

All patients were prepared and draped for a sterile procedure and were operated under the general anaesthesia. Surgical operation microscope and/or otologic endoscopes were used during the operation. Tragus and external auditory canal were injected with 1-3 ml of local anaesthetic (Lidocaine 20mg/ml and 0.125% epinephrine). The tympanic membrane perforation edges were refreshed with pick (Figure 1a). On presence of calcific plaque on TM remnant, all calcific plaques were removed. TM remnant on manubrium mallei was dissected with over malleus to mallei and elevated laterally to replace over tragal cartilage graft (Figure 1b). Tragal cartilage was harvested making a linear incision on the tragus preserving the perichondrium on one surface. The cartilage size was determined to cover TM perforation, and a circular cartilage graft was formed. In the meantime, the perichondrium on the other side was prepared to be 1 mm larger than the circumference of the cartilage graft. Thus, an island graft, one side with perichondrium, was prepared. The localisation on the manubrium mallei was then determined in the prepared graft. In this localisation, a notch was created on cartilage. In this notch, the piece of cartilage in the form of a watermelon slice was removed while preserving the perichondrium to prevent graft mobilisation. Thus, this notch provided better interaction between graft and ossicular chain (Figure 2). There was no need to routinely fill the middle ear cavity with a sponge. The middle ear cavity was supported with sponge if the graft did not come into contact with the membrane residue. Tragus skin incision was sutured with 5/0 nylon. All sponges were removed postoperatively at the first week (Figure 3a and 3b).

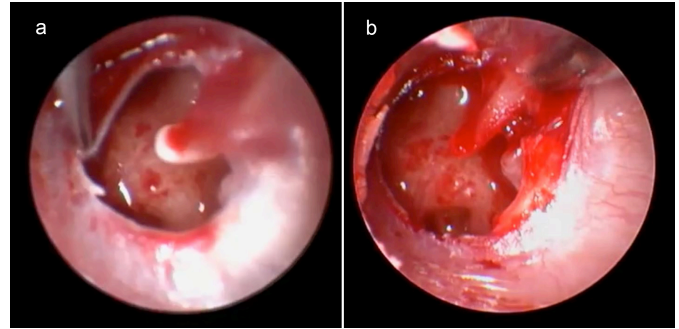


Figure 1: (a) Intraoperative view of refreshing tympanic membrane, (b) Dissection of tympanic membrane remnant on the manubrium mallei.

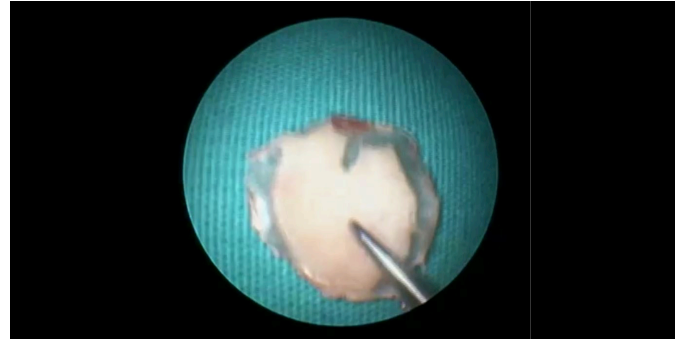

Figure 2: The notch composed on the graft and the final form of the graft.

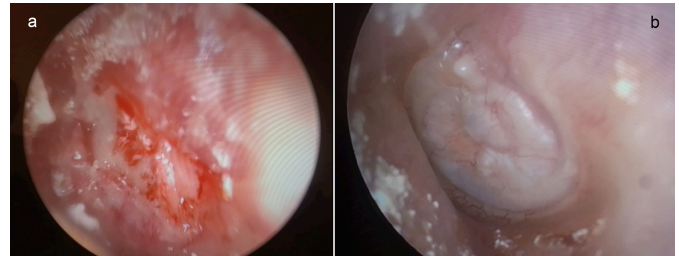


Figure 3: (a) Postoperative (1-week) appearance of the graft after removal of the sponges from the ear canal. (b) The view of the graft at the first postoperative month.

The surgical approach, complications, and surgical outcomes were collected from the patients' medical charts. The successful technique was defined as intact repaired tympanic membrane during the follow-up period.

Statistical analyses were performed using SPSS Statistic programme v.27 (SPSS Inc., Chicago, USA). The continuous variables were summarised as mean and standard deviation (sd) or median (min - max). The categorical measurements were summarised as numbers (percentage of the diagnostic group). Since the number of participants included in the study was less than 30 and the distribution was irregular in the Kolmogorov Smirnov test, non-parametric comparison was made. Wilcoxon test was used for preoperative and postoperative comparison. Statistical significance was accepted as $p < 0.05$.

RESULTS

There were 14 (60%) males and 10 (40%) females and mean age was 32.7 ± 11 years. Patients' mean follow-up time was 24 (12-48) months. Postoperatively, 23 (96%) grafts were intact,

and one (4%) had perforation. Perforation secondary to otomycolysis developed in the first month postoperatively. Eight patients had previous unsuccessful tympanoplasty history. These patients' tympanic grafts were intact with this technique. The surgical success rate was 0.96%. Preoperative mean air conduction threshold (ACT) was 35.00 (25-50) dB, preoperative bone conduction threshold (BCT) was 10.00 (7-20) dB. Preoperative mean air bone gap (ABG) was 20.0 (15-30) dB. Postoperative mean ACT was 20 (10-35) dB. and Postoperative mean air bone gap (ABG) was 8.0 (0-20) dB. So, postoperative hearing gain was 12.0 dB. Functional success rate was 0.88%. Mean surgery time was 30 minutes (min: 20 minutes - max: 45 minutes). In terms of ACT and ABG, there was a statistically significant difference between preoperative and postoperative ($p < 0.001$). Vertigo was observed in only one patient. After removing sponges in the ear canal, the complaint rapidly improved. The patients easily continued their lives within one week after the surgery.

DISCUSSION

Type-1 cartilage tympanoplasty, is a surgical procedure to repair tympanic membrane and reconstruct hearing that had been performed for many years.⁹ During the development process of this surgical approach, various cartilage grafts, and grafting techniques had been described. Graft shape, size, and grafting method are some of the important factors that affect functional and audiometric results of the surgery.⁹

Inlay cartilage tympanoplasty was first described by Eavey *et al.* in 1998.⁷ Soon Ghanem *et al.* used this technique successfully for large perforations.⁸ These techniques were found to be easily applicable, with high perforation closure rate and good audiologic results. When the cases using palisade grafting technique were examined, it was seen that up to 96% graft success was achieved and good audiometric results were obtained.¹⁰ In Type 1 tympanoplasty with island graft, graft success was around 90% and audiological results were satisfactory.¹¹ Onal *et al.* reported that the functional success of the island graft group in terms of air-bone gap closure was statistically better than temporalis fascia group.¹² In contrast to their study, Bozdemir *et al.* found that the air-bone gap closure was statistically better in temporalis fascia group when compared to the island cartilage group.¹³ In the present study, a modified medial grafting method was applied. With this method, 96% graft success was achieved. The authors interpreted this result as follows. With this method, the integrity of the outer ear canal and tympanic annulus was preserved. Moreover, since the graft was placed over-under technique and channel integrity was preserved, the possibility of graft mobilisation decreased and its interaction with the membrane remnant was adequate. Another explanation was that there was no impairment in tissue blood supply secondary to surgery due to the protected canal integrity. Therefore, it was thought that the migration of epithelium on the graft from the aviated TM remnant was faster, thus achieving good graft success.

In a study by Kirazli *et al.* on 15 patients in the island cartilage group and 10 patients in the temporalis fascia group, they stated the mean postoperative gain for the cartilage and temporalis group to be 11.9 dB and 11.5 dB, respectively, and there was no statistically significant difference when the groups were compared.¹⁴ In the study conducted by Dornhoffer *et al.*, it was stated that the hearing gain due to the closure of the air-bone gap was statistically significant individually in both the temporal fascia and cartilage groups, but there was no significant difference between the two groups.¹⁵ In the present study, preoperative mean air conduction threshold (ACT) was 33.8 dB, preoperative bone conduction threshold (BCT) was 13.08 dB, preoperative mean air-bone gap (ABG) was 20.5 dB, postoperative mean ACT was 21 dB, postoperative hearing gain was 12.8 dB, and the functional success rate was 0.88. Mean surgery time was 30 minutes (min: 20 minutes - max: 45 minutes). Vertigo was observed in only one patient. After removing sponges in the ear canal, the complaint rapidly improved. Patients easily continued their lives in one-week time after surgery.

The technique used in the current study was suitable for all pars large tensa perforations. It easily performed with operation microscope and otologic endoscopes. When TM perforation sides were not fully visible, otologic endoscopes had advantages to operation microscope. The advantages of this technique included a short operation time, less pain after surgery, short hospitalisation time, easy postoperative care, no requirement of mastoid bandage, early adaptation to daily life, and less ear wax accumulation because of protection of external auditory canal integrity. Moreover, there was no need to shave the hair on the operation site. The disadvantages of technique were: sometimes, the graft size adjustment may be difficult while using one hand during the operation; graft placement was difficult according to inlay technique; high ossicle displacement risk for an inexperienced surgeon on graft insertion. These were overcome with the modified technique. This study had some limitations. One of the main limitations of the study was that the number of patients was small. Another limitation was the selection of patients from a single centre. On the other hand, the advantages of this method were that it provided high surgical success and good audiometric results as compared to other surgical methods, and a good postoperative life-quality in a short time after the surgery.

CONCLUSION

With this modified cartilage tympanoplasty method, high surgical success and good audiometric results were obtained. Providing a good quality of life after the surgery was one of the advantages of this method. It was one of the successful Type-1 tympanoplasty methods to be preferred safely in large TM perforations.

ETHICAL APPROVAL:

This observational study was carried out at Samsun Medica International Hospital following an approval from the Institutional Review Board (IRB No. 12.06.2019/1).

PATIENTS' CONSENT:

Patients' consent was not obtained as the study was designed on retrospective pathology archive preparations.

COMPETING INTEREST:

The author declared no conflict of interest.

AUTHOR'S CONTRIBUTION:

HK: Conception or design of the work, or the acquisition, analysis, or interpretation of data for the work, drafting the work or revising it critically for important intellectual content, final approval of the version to be published, agreement to be accountable for all aspects of the work ensuring that questions related to the accuracy or integrity of any part of the work are appropriately investigated and resolved.

REFERENCES

1. Brar S, Watters C, Winters R. Tympanoplasty. In: StatPearls [Internet]. Treasure Island (FL): StatPearls Publishing; 2022. Available from: <http://www.ncbi.nlm.nih.gov/books/NBK565863/>.
2. Karakus MF, Karakurt SE, Ozcan KM, Ikinciogullari A, Colak M, Dere HH. The Effect of the Korner's Septum on graft and hearing success after Type 1 tympanoplasty. *J Coll Physicians Surg Pak* 2020; **30(2)**:154-7. doi: 10.29271/jcsp.2020.02.154.
3. Khan SN, Udaipurwala IH, Mehmood T, Rahat ZM. Hearing status after radical mastoidectomy without tympanoplasty. *J Coll Physicians Surg Pak* 2017; **27(12)**:759-62.
4. Yurttas V, Yakut F, Kutluhan A, Bozdemir K. Preparation and placement of cartilage island graft in tympanoplasty. *Braz J Otorhinolaryngol* 2014; **80(6)**:522-6. doi: 10.1016/j.bjorl.2014.08.007.
5. Haksever M, Akduman D, Solmaz F, Gundogdu E. Inlay butterfly cartilage tympanoplasty in the treatment of dry central perforated chronic otitis media as an effective and time-saving procedure. *Eur Arch Otorhinolaryngol* 2015; **272(4)**:867-72. doi: 10.1007/s00405-014-2889-6.
6. Gross CW, Bassila M, Lazar RH, Long TE, Stagner S. Adipose plug myringoplasty: An alternative to formal myringoplasty techniques in children. *Otolaryngol Head Neck Surg* 1989; **101(6)**:617-20. doi: 10.1177/019459988910100601.
7. Eavey RD. Inlay tympanoplasty: Cartilage butterfly technique. *Laryngoscope* 1998; **108(5)**:657-61. doi: 10.1097/00005537-199805000-00006.
8. Ghanem MA, Monroy A, Alizade FS, Nicolau Y, Eavey RD. Butterfly cartilage graft inlay tympanoplasty for large perforations. *Laryngoscope* 2006; **116(110)**:1813-6. doi: 10.1097/01.mlg.0000231742.11048.ed.
9. Ferlito S, Fadda G, Lechien JR, Cammaroto G, Bartel R, Borello A, et al. Type 1 tympanoplasty outcomes between cartilage and temporal fascia grafts: A long-term retrospective study. *J Clin Med* 2022; **11(23)**:7000. doi: 10.3390/jcm11237000.
10. Rasool S, Qureshi S, Varshney A, Hassan S, Kokab F, Naseeruddin K. Palisade cartilage tympanoplasty, an alternative surgical approach for CSOM. *Iran J Otorhinolaryngol* 2022; **34(123)**: 179-83. doi: 10.22038/IJORL.2022.60937.3093.
11. Venkatesan D, Umamaheswaran P, Vellikkannu R, Kannan S, Sivaraman A, Ramamurthy S. A comparative study of temporalis fascia graft and full thickness tragal island cartilage graft in Type 1 tympanoplasty. *Indian J Otolaryngol Head Neck Surg* 2022; **74**:619-23. doi: 10.1007/s12070-021-02459-2.
12. Onal K, Arslanoglu S, Oncel S, Songu M, Kopar A, Demiray U. Perichondrium/Cartilage island flap and temporalis muscle fascia in Type I tympanoplasty. *J Otolaryngol Head Neck Surg* 2011; **40(4)**: 295-9. doi: 10.2310/7070.2011.100-267.
13. Bozdemir K, Kutluhan A, Yalciner G, Tarlak B, Bilgen AS. Tympanoplasty with island cartilage or temporalis fascia: A comparative study. *ORL J Otorhinolaryngol Relat Spec* 2012; **74(1)**:28-32. doi: 10.1159/000335056.
14. Kirazli T, Bilgen C, Midilli R, Ogut F. Hearing results after primary cartilage tympanoplasty with island technique. *Otolaryngol Head Neck Surg* 2005; **132(6)**:933-7. doi: 10.1016/j.otohns.2005.01.044.
15. Dornhoffer JL. Hearing results with cartilage tympanoplasty. *Laryngoscope* 1997; **107(8)**: 1094-9. doi: 10.1097/00005537-199708000-00016.

