

Modified Double-Tract Reconstruction in Gastrointestinal Reconstruction after Proximal Gastrectomy

Yingying Li, Jian Wu, Ming Han, Wenbin Li and Zhibin Bi

Department of Gastrointestinal Surgery, Heji Hospital Affiliated to Changzhi Medical College, Shanxi, China

ABSTRACT

Objective: To determine the clinical efficacy and safety of modified double-channel anastomosis for digestive tract reconstruction in proximal gastrectomy for early gastric cancer (EGC).

Study Design: Case series.

Place and Duration of the Study: Department of Gastrointestinal Surgery, Heji Hospital, Changzhi Medical College, Shanxi, China, from January to November 2022.

Methodology: Based on inclusion and exclusion criteria, this study included a total of 21 patients with oesophagogastric junction cancer or proximal gastric cancer who underwent laparoscopic proximal gastrectomy with modified double-channel anastomosis. After resection of the proximal stomach, the remaining stomach was shaped into a tube. The distal end of the oesophagus was anastomosed to the jejunum. The jejunum was anastomosed 10-15 cm from the oesophagojejunostomy site laterally to the anterior wall of the stomach 3 cm from the gastric remnant. General data including operative time, anastomosis time, intraoperative blood loss, time to oral intake, length of hospital stay, and postoperative complications were evaluated. Postoperative gastroscopy and gastrointestinal imaging were performed to assess the residual stomach motility and anti-reflux effect.

Results: All twenty-one patients underwent modified double-channel anastomosis. The mean operation time was 254 (211 - 297) minutes. Mean reconstruction time was 65 (60 - 70) minutes. A mean of 19 (15 - 29) lymph nodes were cleared. Mean intraoperative blood loss was 86 (78.5-105ml). Mean time to oral intake was 6 (5 - 6.5) days. Postoperatively, there were two cases of pulmonary infection. There was no occurrence of anastomotic stenosis, anastomotic bleeding, or leakage. Gastrointestinal contrast study at 6 months postoperatively revealed reduced gastrointestinal motility in three cases and good residual gastric motility observed in the remaining patients. Gastroscopic examination at 6 months postoperatively revealed only one case of reflux oesophagitis.

Conclusion: Modified double-channel anastomosis for proximal gastrectomy is safe and feasible. It provides a good anti-reflux effect and gastric emptying function without increasing the risk of postoperative complications.

Key Words: Adenocarcinoma of the oesophagogastric junction, Upper gastric carcinoma, Proximal gastrectomy, Double-tract reconstruction.

How to cite this article: Li Y, Wu J, Han M, Li W, Bi Z. Modified Double-Tract Reconstruction in Gastrointestinal Reconstruction after Proximal Gastrectomy. *J Coll Physicians Surg Pak* 2024; **34(11)**:1374-1377.

INTRODUCTION

Oesophagogastric junction adenocarcinoma (AEG) and proximal gastric cancer have shown an increasing incidence globally, posing challenges and threats to human health.^{1,2} The proportion of early gastric cancer cases has also significantly increased worldwide.³ In the Asian countries, laparoscopic proximal gastrectomy (PG) is considered more suitable for treating early gastric cancer, including AEG, involving the upper-third of the stomach, compared to total gastrectomy.⁴ The oncological safety of PG has been confirmed compared to total gastrectomy.

Simultaneously, the preservation of a portion of the stomach with PG allows patients to achieve a better postoperative nutritional status, reducing postoperative weight loss and vitamin B12 malabsorption.⁵ However, an ideal anastomotic method has not yet been established due to issues such as reflux, anastomotic stenosis, and technical difficulties associated with PG.

PG combined with double-tract reconstruction (DTR) is currently a mainstream method of gastrointestinal reconstruction, reflecting the combination of functional preservation and anti-reflux effects.⁶ Nevertheless, there are still certain limitations, such as residual gastric emptying disorders and the inability of double tracts to be maintained in the long term. Shaibu *et al.* found that the incidence of gastric emptying disorders in DTR was 39%.⁷ However, the recovery of gastrointestinal motility was beneficial for improving nutritional deficiencies and weight loss after proximal gastrectomy.⁸ If food cannot pass through the residual stomach, the effects of DTR surgery may be similar to total gastrectomy.^{9,10} Therefore, the authors developed a newly designed DTR technique to achieve more stable therapeutic effects, which is called modified double-tract anastomosis.

Correspondence to: Dr. Zhibin Bi, Department of Gastrointestinal Surgery, Heji Hospital Affiliated to Changzhi Medical College, Shanxi, China
E-mail: bizhibin76800@126.com

Received: November 18, 2023; Revised: February 15, 2024;
Accepted: February 19, 2024
DOI: <https://doi.org/10.29271/jcpsp.2024.11.1374>

The aim of this study was to evaluate the clinical efficacy and safety of laparoscopic proximal gastrectomy combined with modified double-tract anastomosis.

METHODOLOGY

This case series included patients with AEG and proximal gastric cancer who underwent laparoscopic PG with double-tract reconstruction at the Affiliated Hospital of Changzhi Medical College and Heji Hospital in China, from January to November 2022. The inclusion criteria were AEG patients with Siewert Type II and Type III, with tumour diameter <4 cm; absence of distant metastasis preoperative clinical stage cT0-3N0-1M0, oesophageal involvement <4 cm; and tumours located mainly in the cardia infiltrating the lesser curvature of the stomach. The exclusion criteria were concurrent malignancies in other sites; patients who received neoadjuvant chemotherapy before the surgery; tumours with distant metastasis; and patients with surgical contraindications or who were unable to tolerate surgery.

The study was conducted in accordance with the Helsinki Declaration and approved by the Hospital's Ethics Committee (Ethics Approval Number: 2021-36). Written informed consent was obtained from all patients.

The primary measured outcomes included surgery time, reconstruction time of the digestive tract, number of lymph node dissections, blood loss, time to resume oral intake, length of hospital stay postoperatively, and postoperative complications.

All surgeries in this study were performed by the same surgical team. The proximal stomach was dissected laparoscopically, and lymph node dissection included No. 1, 2, 3a, 4sa, 4sb, 7, 8a, 9, and 11p groups.¹¹ If the tumour invaded the oesophagus at a distance of 2 - 4 cm, mediastinal lymph node dissection was performed. A small incision was made along the midline of the upper abdomen, and a wound protector was placed. The oesophagus was divided 3 cm proximal to the tumour margin. The residual stomach was fashioned into a tube-shaped stomach; using a 60 mm linear cutting stapler, the stomach was transected horizontally from the junction of the gastric fundus and body, extending along the longitudinal axis of the stomach to the level of the gastric angle, resulting in a tube-shaped stomach with a length of 15 cm and a width of 3.5 - 4 cm.² Oesophagojejunostomy was performed using the *Roux-en-Y* technique. Gastric-jejunum anastomosis was performed to establish the double-tract. The jejunum located 10 - 15 cm from the oesophagojejunostomy was anastomosed side-to-side with the anterior wall of the tube-shaped stomach located 3 cm from the residual end, creating a structure similar to the gastric fundus. A 60 mm linear cutting stapler was used to enlarge the gastrojejunostomy. All anastomotic sites, gastric stump, and residual jejunum were reinforced with the interrupted full-thickness sutures using 3-0 absorbable sutures (Figure 1).

Patients were followed up at 3 months, 6 months, and 12 months postoperatively through outpatient visits or telephone

interviews. Late complications including reflux oesophagitis, anastomotic stricture, and residual gastric emptying were observed.

R Foundation for Statistical Computing (4.0.2, Vienna, Austria) was employed for the statistical analysis. The Shapiro-Wilk's test was used to verify the normality of the data. Quantitative data were expressed as medians (interquartile range, IQR). Qualitative data were presented as frequencies and percentages. A p-value <0.05 was considered to indicate statistically significant differences.

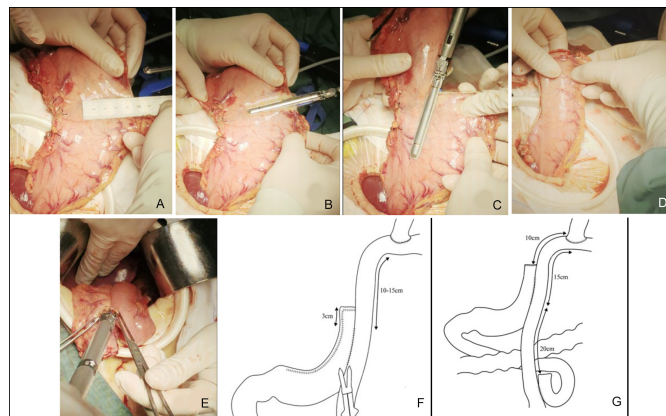


Figure 1: Intraoperative images. (A) Width of 4 cm. (B) Transaction from the greater curvature side to the lesser curvature side at the junction of the gastric fundus and body. (C) Vertical transection along the gastric body to the level of the gastric angle, including the gastric body, tumour, and partial gastric less curvature tissue. (D) Formation of a tubular structure with a length of 15 cm and a width of 3.5-4 cm. (E, F) Side-to-side anastomosis between the jejunum at a distance of 10-15 cm from the oesophagojejunostomy and the gastric anterior wall at a distance of 3 cm from the remnant end, creating a structure similar to the gastric fundus. (G) Overall schematic diagram of the modified double-tract anastomosis.

RESULTS

Table I presents the baseline characteristics of the patients. Twenty-one patients underwent the procedure (17 males and 4 females), with a mean age of 64 (ranging from 53 to 70) years, a median body mass index of 23.1 (ranging 18.4 to 28.3) kg/m², and a tumour diameter of 3 (ranging 2.50 to 3.90) cm. Among them, 2 (9.5%) patients had a history of abdominal surgery, 3 (14.2%) patients had diabetes, and 5 (23.8%) patients had hypertension.

All patients in this study underwent the surgery successfully. As shown in Table II, the mean operation time was 254 (211 - 297) minutes, the reconstruction time for the digestive tract was 65 (60 - 70) minutes, and the number of dissected lymph nodes was 19 (15 - 29). The intraoperative blood loss was 86 (78.5 - 105) ml. The first-flatus time was 58 (47 - 72) hours, and the time to resume eating was 6 (5 - 6.5) days. The postoperative hospital stay was 12 (10.5 - 13.5) days. There were no serious complications such as anastomotic leakage, anastomotic fat degeneration, pancreatic fistula, or intra-abdominal abscess. The overall postoperative survival rate was 100%.

All 21 patients were followed up after surgery. Two (9.5%) patients developed pulmonary infection one week after the

surgery, and they were discharged after improvement with treatment. One (4.7%) patient developed reflux symptoms 6 months after the surgery and was diagnosed with reflux oesophagitis during gastroscopy, which was relieved after treatment with acid-suppressing medicines. In addition, in terms of gastric emptying function: Three (14.2%) patients were found to have weakened residual gastric motility in the gastrointestinal contrast examination after 6 months of the surgery; the remaining patients had good residual gastric motility.

Table I: Baseline characteristics of the patients.

Variable	Value (n= 21)
Gender [n(%)]	
Male	17 (81)
Female	4 (19)
Age (years)	64 (53 - 70)
BMI (kg/m ²)	(18.4 - 28.3)
Tumour diameter (cm)	3 (2.50 - 3.90)
Tumour TNM staging	
T1S	2 (9.5)
T1	11 (52.4)
T2	7 (33.3)
T3	1 (4.8)
Tumour differentiation grade	
High-grade intraepithelial neoplasia	2 (9.5)
High	6 (28.6)
Moderate	9 (42.9)
Low	4 (19)
Diabetes mellitus comorbidity	3 (14.3)
Hypertension comorbidity	5 (23.8)

Table II: Perioperative data and postoperative complications of patients undergoing modified double-tract reconstruction after proximal gastrectomy.

Variable	Value (n = 21)
Operation time (min)	254 (211 - 297)
Reconstruction time (min)	65 (60 - 70)
Estimated blood loss (ml)	86 (78.5 - 105)
Harvested lymph nodes	19 (15 - 29)
Time to first flatus postoperatively (h)	58 (47 - 72)
Time to resume oral intake postoperatively (day)	6 (5 - 6.5)
Postoperative hospital stay (day)	12 (10.5 - 13.5)
Reoperation	0
Postoperative mortality	0
Postoperative complications	3 (14.9%)
Reflux symptoms	1 (4.7%)
Pulmonary infection	2 (9.5%)
Overall survival rate	100%

DISCUSSION

In terms of oncological safety, it is not necessary to perform total gastrectomy for early upper gastric cancer. PG is a more suitable surgical method as it preserves partial gastric function and has a comparable overall survival rate to the total gastrectomy.¹² However, due to the need to resect structures such as the His angle, gastric fundus, and LES during the PG, the loss of anti-reflux mechanisms often leads to complications such as gastro-oesophageal reflux, resulting in ongoing controversy over the digestive tract reconstruction following PG. DTR is currently a popular method after PG, but it still has certain limitations. Therefore, the authors introduced modifications as a new anastomotic approach.

In traditional DTR, the rate of gastric emptying disorder was found to be 48.9% at 3 months postoperatively, which may be

related to the resection of the gastric electrical pacing points in the mid-body greater curvature during PG, leading to a weakened gastric emptying capacity.¹³ Shaibu *et al.* found a 39% occurrence rate of gastric emptying disorder after DTR.⁷ To address this, when creating the tubular stomach, it was vertically divided from the junction of the gastric fundus and body, cutting from the greater curvature to the lesser curvature, and then removing the tissue of the lesser curvature from top to bottom. This preserved a portion of the tail of the stomach, located in the upper-middle part of the stomach near the greater curvature, which is beneficial for maintaining the postoperative gastric emptying capacity.¹⁴⁻¹⁶ Additionally, the smaller volume of the tubular stomach increased intragastric pressure, reducing the retention time of food in the stomach and lowering the occurrence rate of gastric retention. In this study, all patients underwent gastrointestinal contrast examination at 6 months postoperatively, and the occurrence rate of gastric emptying disorder was 14.2%, lower than previous studies, indicating good postoperative gastric emptying function after modified DTR.

The anti-reflux effect is one of the most important indicators for evaluating the digestive tract reconstruction method after proximal gastrectomy. In this surgery, the authors anastomosed the anterior wall of the tubular stomach 3 cm from the top with the jejunum, creating a structure similar to an artificial gastric fundus to reduce reflux from the residual stomach to the interposed jejunal segment. Furthermore, the length gradient of the tubular stomach made it less prone to reflux into the jejunum. On the other hand, the insertion of the jejunum (10-15 cm) in DTR acted as a buffer against reflux, resulting in a better anti-reflux effect. All cases in this study showed good anti-reflux performance. Previous studies have shown that the incidence rate of reflux oesophagitis one year after DTR was only 11.7%,¹⁷ similar to this study's results.

Although DTR involves more anastomoses, careful intraoperative operation and reinforcement of anastomotic suture lines can effectively reduce the occurrence of postoperative anastomotic complications. The low frequency of perioperative and postoperative complications indicates that the modified double-tract reconstruction has relatively reliable surgical safety. The modified double-tract reconstruction, using a 60 mm linear cutting stapler, expands the anastomosis between the jejunum 10-15 cm from the oesophagus and the tubular stomach anterior wall 3 cm from the residual end, reducing the occurrence rate of anastomotic stricture. The expanded anastomosis is beneficial for more food to enter the stomach, improving the postoperative nutritional status of the patients.¹⁸ The limitations of this study include the subjective symptoms such as not being evaluated through questionnaires, and the lack of assessment of long-term functional benefits. Although this was only a retrospective study of a small number of cases, the technique appears to provide feasible outcomes.

CONCLUSION

PG combined with modified double-tract reconstruction is a safe and effective method for reconstructing the digestive tract after proximal gastrectomy. It preserves partial gastric function

while reducing the incidence of gastric emptying disorders and avoiding severe reflux oesophagitis after the surgery.

ETHICAL APPROVAL:

This study was approved by the Ethics Committee of Heji Hospital Affiliated to Changzhi Medical College (Ethical Approval Number: 2021-36).

PATIENTS’ CONSENT:

Informed consent was obtained from the patients to publish the data concerning this study.

COMPETING INTEREST:

The authors declared no conflict of interest.

AUTHORS’ CONTRIBUTION:

YL: Study design and data collection.

JW, MH, WL: Data collection.

ZB: Analysis and organisation of the data.

All authors approved the final version of the manuscript to be published.

REFERENCES

1. Manabe N, Matsueda K, Haruma K. Epidemiological review of gastroesophageal junction adenocarcinoma in Asian countries. *Digestion* 2022; **103(1)**:29-36. doi: 10.1159/000519602.
2. Sung H, Ferlay J, Siegel RL, Laversanne M, Soerjomataram I, Jemal A, et al. Global Cancer Statistics 2020: GLOBOCAN estimates of incidence and mortality worldwide for 36 cancers in 185 countries. *CA Cancer J Clin* 2021; **71(3)**: 209-49. doi: 10.3322/caac.21660.
3. Mantilla MJ, Chaves JJ, Ochoa-Vera M, Africano F, Parra-Medina R, Tovar-Fierro G, et al. Clinical characteristics of early-onset gastric cancer. A study in a Colombian population. *Rev Gastroenterol Peru* 2023; **43(3)**:236-41.
4. Zhao L, Ling R, Chen J, Shi A, Chai C, Ma F, et al. Clinical outcomes of proximal gastrectomy versus total gastrectomy for proximal gastric cancer: A systematic review and meta-analysis. *Dig Surg* 2021; **38(1)**:1-13. doi: 10.1159/000506104.
5. Yamasaki M, Takiguchi S, Omori T, Hirao M, Imamura H, Fujitani K, et al. Multicenter prospective trial of total gastrectomy versus proximal gastrectomy for upper third cT1 gastric cancer. *Gastric Cancer* 2021; **24(2)**:535-43. doi: 10.1007/s10120-020-01129-6.
6. Lewis TS, Feng Y. A review on double tract reconstruction after proximal gastrectomy for proximal gastric cancer. *Ann Med Surg (Lond)* 2022; **79**:103879. doi: 10.1016/j.amsu.2022.103879.
7. Shaibu Z, Chen Z, Mzee SAS, Theophilus A, Danbala IA. Effects of reconstruction techniques after proximal gastrectomy: A systematic review and meta-analysis. *World J Surg Oncol* 2020; **18(1)**:171. doi: 10.1186/s12957-020-01936-2.

8. Toyomasu Y, Ogata K, Suzuki M, Yanoma T, Kimura A, Kogure N, et al. Restoration of gastrointestinal motility ameliorates nutritional deficiencies and body weight loss of patients who undergo laparoscopy-assisted proximal gastrectomy. *Surg Endosc* 2017; **31(3)**:1393-401. doi: 10.1007/s00464-016-5127-z.
9. Tanaka K, Ebihara Y, Kurashima Y, Nakanishi Y, Asano T, et al. Laparoscopic proximal gastrectomy with oblique jejunogastrostomy. *Langenbecks Arch Surg* 2017; **402(6)**: 995-1002. doi: 10.1007/s00423-017-1587-4.
10. Qiu GL, Wei C, Zhu MK, Han SN, Li XW, Wang HJ, et al. Efficacy of laparoscopic proximal gastrectomy with double-tract reconstruction versus laparoscopic total gastrectomy with Roux-en-Y reconstruction for early upper gastric cancer. *Zhonghua Wei Chang Wai Ke Za Zhi* 2022; **25(5)**:412-20. doi: 10.3760/cma.j.cn441530-20211118-00466.
11. Japanese Gastric Cancer Treatment Guidelines 2021 (6th edition). *Gastric Cancer* 2023; **26(1)**:1-25. doi: 10.1007/s10120-022-01331-8.
12. Kunisaki C, Yoshida K, Yoshida M, Matsumoto S, Arigami T, Sugiyama Y, et al. Effects of proximal gastrectomy and various clinical factors on postoperative quality of life for upper-third gastric cancer assessed using the post-gastrectomy syndrome assessment scale-45 (PGSAS-45): A PGSAS next study. *Ann Surg Oncol* 2022; **29(6)**:3899-908. doi: 10.1245/s10434-021-11136-1.
13. Ahn SH, Jung DH, Son SY, Lee CM, Park DJ, Kim HH, et al. Laparoscopic double-tract proximal gastrectomy for proximal early gastric cancer. *Gastric Cancer* 2014; **17(3)**: 562-70. doi: 10.1007/s10120-013-0303-5.
14. O’Grady G, Du P, Cheng LK, Egbuji JU, Lammers WJ, Windsor JA, et al. Origin and propagation of human gastric slow-wave activity defined by high-resolution mapping. *Am J Physiol Gastrointest Liver Physiol* 2010; **299(3)**:G585-92. doi: 10.1152/ajpgi.00125.2010.
15. Sanders KM. Spontaneous electrical activity and rhythmicity in gastrointestinal smooth muscles. *Adv Exp Med Biol* 2019; **1124**:3-46. doi: 10.1007/978-981-13-5895-1_1.
16. Zhang YQ, Xu ZY, Du YA, Yang LT, Huang L, Yu PF, et al. [Functional outcomes of 100 patients with adenocarcinoma of the esophagogastric junction undergoing Cheng’s GIRAFFE(®) reconstruction after proximal gastrectomy]. *Zhonghua Wei Chang Wai Ke Za Zhi* 2022; **25(5)**:447-53. doi: 10.3760/cma.j.cn441530-20220414-00146.
17. Xiao SM, Zhao P, Ding Z, Xu R, Yang C, Wu XT, et al. Laparoscopic proximal gastrectomy with double-tract reconstruction for upper third gastric cancer. *BMC Surg* 2021; **21(1)**:140. doi: 10.1186/s12893-021-01153-y.
18. Hosoda K, Yamashita K, Moriya H, Washio M, Mieno H, Ema A, et al. Esophagogastric junction cancer successfully treated by laparoscopic proximal gastrectomy and lower esophagectomy with intrathoracic double-flap technique: A case report. *Asian J Endosc Surg* 2018; **11(2)**:160-4. doi: 10.1111/ases.12419.

