

# Comparative Efficacy of Red Beetroot Extract and Ozonated Olive Oil on Wound Healing in Rats

Serdar Aktas<sup>1</sup>, Yelda Ozsunar<sup>2</sup>, Serdal Ogut<sup>3</sup>, Serap Gokce<sup>4</sup> and Canten Tataroglu<sup>5</sup>

<sup>1</sup>Faculty of Veterinary Medicine, Adnan Menderes University, Aydin, Turkey

<sup>2</sup>Department of Radiology, Faculty of Medicine, Adnan Menderes University, Aydin, Turkey

<sup>3</sup>Faculty of Health Sciences, Adnan Menderes University, Aydin, Turkey

<sup>4</sup>Faculty of Nursing, Adnan Menderes University, Aydin, Turkey

<sup>5</sup>Department of Pathology, Faculty of Medicine, Adnan Menderes University, Aydin, Turkey

## ABSTRACT

**Objective:** To compare and assess the effect of red beetroot extract and ozonated olive oil on wound healing in rats.

**Study Design:** Experimental study.

**Place and Duration of the Study:** Department of Experimental Animal Research Laboratory, Faculty of Medicine, Aydin Adnan Menderes University, from June to July 2021.

**Methodology:** Twenty-one, female Wistar albino rats were divided into 3 groups; red beetroot extract group (RBG, n=7), ozonated olive oil group (OOG, n=7), and physiological saline group (CG). Three round wound areas of similar shapes were produced on the back areas. Skin incisions with a diameter of 15 mm were made in rats with a scalpel under anaesthesia protocol. Beetroot extract was applied to RBG, ozonated olive oil to OOG, and saline to CG, once a day for 21 days. Tissue samples were taken from the wounds on the 3<sup>rd</sup>, 10<sup>th</sup>, and 21<sup>st</sup> day of the study, and a histopathological examination (Hematoxylin eosin staining) was performed for haemorrhage, congestion, necrosis, inflammation and fibrosis levels. Wound healing was also determined macroscopically by photography on same days. Serum oxidant (TOS,  $\mu\text{mol H}_2\text{O}_2$  equivalent-s/L), antioxidant status (TAS, mmol trolox equivalents/L), serum total thiol ( $\mu\text{mol/L}$ ), serum native thiol ( $\mu\text{mol/L}$ ) and paraoxonase (PON, U/L) were determined from blood samples on the 21<sup>st</sup> day.

**Results:** Lower inflammation and higher blood antioxidant levels were determined in the RBG and OOG groups compared to the CG. A better wound healing on histology was observed in the OOG group compared to RBG.

**Conclusion:** Red beetroot extract and ozonated olive oil enhanced wound healing in female rats. Ozonated olive oil had more effective wound-healing effect than beetroot extract.

**Key Words:** Wound healing, Ozonated olive oil, Red beetroot extract, Antioxidant effect.

**How to cite this article:** Aktas S, Ozsunar Y, Ogut S, Gokce S, Tataroglu C. Comparative Efficacy of Red Beetroot Extract and Ozonated Olive Oil on Wound Healing in Rats. *J Coll Physicians Surg Pak* 2023; **33(12)**:1385-1389.

## INTRODUCTION

Wound healing is a multifaceted and dynamic process that initiates promptly after injury and may span from days to months or even years.<sup>1</sup> Several factors, including the anatomical site of the wound, the underlying cause, and the severity of the injury, intricately influence this process. Wound care materials should possess antibacterial, antifungal, and antioxidant properties, along with the capacity to stimulate the production of growth factors, collagen, and fibroblasts, all crucial elements for normal wound healing. Strengthening the antioxidant defence system, especially against increased oxidative stress during wound healing, significantly affects the healing process. Herbal extracts display therapeutic potential, notably in alkaloids, flavonoids, glycosides, and terpenes.<sup>2</sup>

These plant-based extracts have been recognised for their antibacterial properties, ability to enhance collagen synthesis, promote cell proliferation, stimulate fibroblasts, exert antimicrobial activity, and provide antioxidant benefits.<sup>2,3</sup>

Betalain compound is approved by both the European Union and the American Food and Drug Administration (FDA) for use as a natural colourant in a variety of products, including food items, cosmetics, and pharmaceuticals, under the code E162. Betanin, a water-soluble heterocyclic compound featuring nitrogen particles, is classified among betacyanins due to its characteristic red-violet pigmentation.<sup>4</sup> Previous research had documented betanin's gastroprotective properties, particularly in the context of gastric ulcers.<sup>5</sup>

Natural and biocompatible herbal products derived exclusively from botanical sources are promising candidates to enhance wound healing outcomes.<sup>6</sup> Notably, extensive literature review underscored a relative scarcity of studies investigating red beetroot, enriched with betalains, for applications beyond its traditional role as a food additive. Olive oil has important benefits in wound healing due to the antioxidant substances and vitamins (especially tocopherol) in it. In the context of wound care

Correspondence to: Dr. Serdar Aktas, Faculty of Veterinary Medicine, Adnan Menderes University, Aydin, Turkey  
E-mail: saktas@adu.edu.tr

Received: June 29, 2023; Revised: November 03, 2023;

Accepted: November 13, 2023

DOI: <https://doi.org/10.29271/jcpsp.2023.12.1385>

ozonated olive oil, a derivative of this treatment has demonstrated the ability to expedite wound healing, exert antimicrobial effects, and even offer anti-ageing properties when applied at lower doses.<sup>7</sup> The aim of this study was to compare the effects of ozonated olive oil and red beetroot extract on the rat wound healing model.

## METHODOLOGY

The study was started after permission from Aydin Adnan Menderes University Animal Experiments Local Ethics Committee (Approval number: 64583101/2021/068). A total of 21 female Wistar albino rats, aged 3 to 4 months, with a body weight ranging from 200 to 300 g were included in the study. The experimental phase took place during the period of June to July 2021. These rats were randomly divided into three groups: the physiological saline group (CG, n=7), the red beetroot extract group (RBG, n=7), and the ozonated olive oil group (OOG, n=7).

The procedures for wound formation were conducted in accordance with previously reported methods.<sup>8</sup> To facilitate this, the rats were anaesthetised through intraperitoneal administration of ketamine HCl (50 mg/kg/bw, Ketalar, EWL Eczacibasi/Istanbul) and xylazine (5 mg/kg/bw, Xylazinobio, Bioveta/Czech Republic). The dorsal skin of the rats was shaved using an electric razor, followed by cleansing with batticon solution. Subsequently, three full-thickness skin incisions with a 15 mm diameter were made along the cephalic region using a size 15 scalpel. To alleviate pain and ensure animal welfare, Paracetamol was added to drinking water at a dosage of 100 mg/kg/bw on the day of wound creation.

The red beetroot (*Beta vulgaris rubra*) extract used in the study was prepared through specialised procedures, resulting in a 3% solution utilising distilled water. This solution was characterised by its composition, containing 924 mg betalain, 14.3 mg flavonoid, 6.36 mg ascorbic acid, 514 mg total phenolic content, and 0.43 mg total mineral matter per 100 g of dry powder compounds. Commercially sourced olive oil (Taris North Aegean Extra Virgin Olive Oil/Turkey) underwent ozonation procedures. Ozonation was conducted for a duration of 30 minutes using an ozone generator with an O<sub>3</sub> production capacity of 1,000 mg/h (Product name: AZ-1000MG-G).

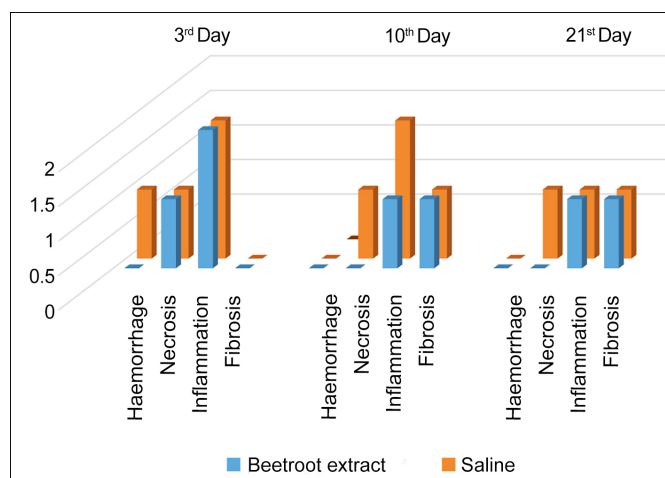
Data for the study were acquired by evaluating histochemical changes (haemorrhage, necrosis, congestion, inflammation, and fibrosis levels) and biochemical parameters associated with wound healing, specifically total antioxidant capacity (TAS), total oxidant capacity (TOS), serum total thiol, native thiol and paraoxonase (PON). Tissue samples were obtained on the 3<sup>rd</sup>, 10<sup>th</sup>, and 21<sup>st</sup> day post-wound creation. The excised skin tissues were initially immersed in a 10% formalin solution for 24 hours prior to processing and embedding in paraffin wax. Subsequently, paraffin-embedded tissues were sectioned at 4µm thickness, stained with haematoxylin-eosin (HE), and examined using light microscopy (Olympus BX50; Olympus Corp., Tokyo, Japan). Tissue scoring was evaluated by 3 pathologists and an average was taken. Histopathological changes were graded according to the predefined criteria (Table I). At the conclusion of the study, serum samples were extracted from intracardiac blood samples

and stored at -20°C. Commercial test kits (Rel assay diagnostics, Turkey) were used to determine total antioxidant (TAS), total oxidant (TOS), serum native thiol, serum total thiol, and PON.

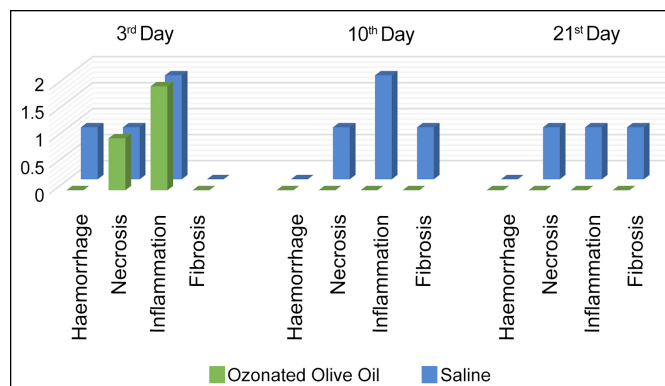
Data obtained from the study were subjected to statistical analysis using the IBM SPSS 24 software package. The dataset was initially examined for frequency and percentage distributions. Since the sample size (n < 30) did not meet the conditions for a normal distribution, the Shapiro-Wilk test was utilised, and the results indicated a non-normal distribution (p < 0.05). Consequently, the Kruskal-Wallis test followed by the Tukey tests were applied for further analysis. Results are presented as mean ± standard deviation (SD), with significance set at p < 0.05.

## RESULTS

On the 3<sup>rd</sup> day of the study, a consistent finding of moderate inflammation and mild necrosis was observed across all experimental groups. Notably, congestion and bleeding were exclusively identified in the CG, while fibrosis remained absent in all groups at this point of time (Figure 1 and 2). Upon reaching the 10<sup>th</sup> day of the study, moderate inflammation persisted in the CG, while the RBG demonstrated an absence of inflammation, a distinction not replicated in the OOG (Figure 2). Necrotic tissue continued to be discernible solely in the CG, with congestion and bleeding conspicuously absent across all groups.



**Figure 1: Histopathological evaluation and comparison of the wound healing efficiency of red beetroot extract and saline groups (Control).**



**Figure 2: Histopathological evaluation and comparison of the wound healing efficiency of ozonated olive oil and saline groups (Control).**

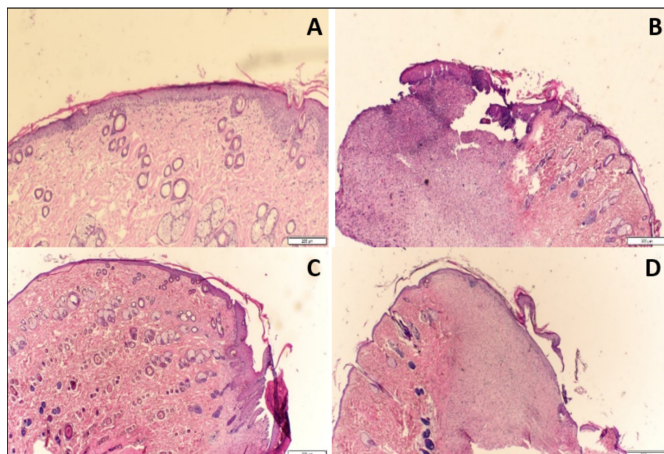
**Table I: The classification method used in the histopathological evaluation and the evaluated parameters.**

Grade	Inflammation	Necrosis	Congestion	Fibrosis	Haemorrhage
0	None	Normal	Normal	Normal	Normal
1	Mild infiltration	Low tissue reaction	Low tissue reaction	Low tissue reaction	Low tissue reaction
2	Moderate	High tissue reaction	High tissue reaction	High tissue reaction	High tissue reaction

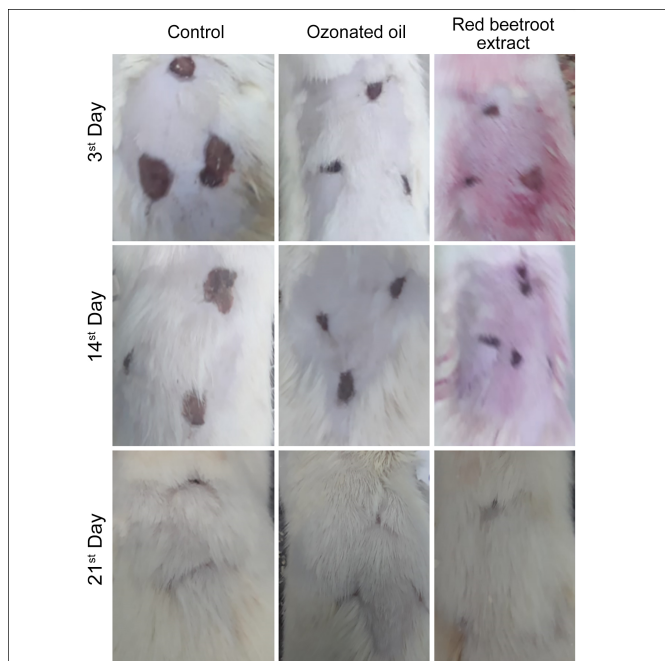
**Table II: Analysis of blood serum samples taken at the end of the study (Day 21).**

Groups	TAS (mmol Trolox equivalents/L) $\bar{X} \pm SD$ Median IQR			TOS ( $\mu\text{mol H}_2\text{O}_2$ equivalents /L) $\bar{X} \pm SD$ Median IQR			Serum total thiol ( $\mu\text{mol/L}$ ) $\bar{X} \pm SD$ Median IQR			Serum native thiol ( $\mu\text{mol/L}$ ) $\bar{X} \pm SD$ Median IQR			PON (U/L) $\bar{X} \pm SD$ Median IQR		
Saline	2.50 $\pm 0.018$	2.59 [0.58]		1.83 $\pm 0.16$	1.98 [0.54]		408.32 $\pm 27.73$	416.42 [41.41]		227.65 $\pm 49.64$	233.55 [46.57]		73.09 $\pm 10.05$	73.45 [11.80]	
Beetroot extract	3.62 $\pm 1.19$	3.74 [0.40]		1.19 $\pm 0.11$	3.74 [0.40]		513.81 $\pm 35.47$	513.65 [35.73]		299.61 $\pm 60.01$	295.71 [22.96]		103.03 $\pm 17.47$	100.67 [14.24]	
Ozonated olive oil	3.08 $\pm 0.23$	2.95 [0.57]		1.47 $\pm 0.14$	2.95 [0.57]		483.78 $\pm 32.07$	477.24 [42.92]		275.13 $\pm 55.57$	272.59 [10.43]		83.13 $\pm 12.85$	81.87 [10.08]	
p	0.002			0.002			<0.001			<0.001			<0.001		

TAS, Total antioxidant status; TOS, Total oxidant status; PON, Paraoxonase. Kruskal-Wallis test was used in the statistical analysis.



**Figure 3: Histopathological evaluation of wound specimens, (A) Normal epidermis and dermis in saline group (x200 magnification), (B) Histologic appearance of an ulcer in the skin, (C) Reepithelisation in the surface and beneath granulation tissue, (D) Granulation tissue and fibrosis.**



**Figure 4: Macroscopic views of wound healing processes.**

By the 21<sup>st</sup> day of observation, mild inflammation persisted in both the CG and RBG, while a mild degree of fibrosis was solely evident in the RBG group. Once again, congestion and bleeding were conspicuously absent in all groups. Further insight into the histopathological findings at the 3<sup>rd</sup>, 10<sup>th</sup>, and 21<sup>st</sup> day intervals is presented in Figure 3. A macroscopic perspective of the dorsal wound sites is depicted in Figure 4. In the study, the total antioxidant status (TAS) exhibited the lowest value within the CG, with the highest TAS recorded in the RBG ( $3.62 \pm 1.19$  mmol/L). Statistical analysis revealed a noteworthy difference in TAS levels among the groups. Subsequent detailed analysis identified that this discrepancy was predominantly attributable to the RBG.

Evaluation of total oxidant status (TOS) indicated the lowest value within the RBG ( $1.19 \pm 0.11$  mmol/L), whereas the CG exhibited the highest mean TOS ( $1.83 \pm 0.16$  mmol). A statistically significant inter-group difference was noted in TOS levels, echoing the TAS results, with the RBG being the primary contributor to this divergence (Table II).

Serum thiol levels were notably distinct among the groups, with the RBG displaying the highest average ( $513.81 \pm 35.47$   $\mu\text{mol/L}$ ) and the saline-treated group exhibiting the lowest levels ( $408.32 \pm 27.73$   $\mu\text{mol/L}$ ). This difference was statistically significant, and in subsequent subgroup analysis, it was determined that the variance could be primarily attributed to the RBG.

Serum native thiol levels were similarly analysed, revealing the highest mean within the RBG ( $299.61 \pm 60.01$   $\mu\text{mol/L}$ ) and the lowest within the CG ( $227.65 \pm 49.64$   $\mu\text{mol/L}$ ). Statistical analysis confirmed the RBG's mean to be significantly higher than that of all other groups. Upon evaluation of serum paraoxonase levels, the RBG displayed the highest mean ( $103.03 \pm 17.47$  U/L), whereas the CG exhibited the lowest mean ( $73.09 \pm 10.05$  U/L). These findings aligned with the overall trend observed across the other parameters (Table II).

## DISCUSSION

Wound healing is a highly orchestrated process comprising a sequence of interrelated events. Numerous wound care prod-



ucts have been developed to facilitate this process and mitigate potential complications. In the context of wound healing, physiological saline and olive oil have garnered empirical support for their efficacy. This study offered novel insights into the wound-healing potential of red beetroot extract through a comparative evaluation against saline and ozonated olive oil.

During the course of the study, it became evident that red beetroot extract exhibited a relatively modest anti-inflammatory effect. However, it consistently prevented congestion and bleeding at all stages of wound healing. While necrosis was observed to be mild in the acute phase, its ameliorative influence on necrosis became more pronounced during the subacute and chronic phases. Notably, fibrosis, which was absent during the acute phase, emerged and persisted in the subsequent phases. Inflammation, a typical early response to wound formation, is anticipated to diminish between Day 1 and 5. Prolonged inflammation can impede the wound-healing process. Consequently, the heightened inflammation observed on the 3<sup>rd</sup> day of wound healing in the study was expected to gradually decrease in the following days. The existing researches highlighted the robust anti-inflammatory properties of betalain compounds found in red beetroot extract, corroborating with this study's findings.<sup>9,10</sup> Moreover, betanin, a prominent betalain, exerts anti-inflammatory effects by modulating multiple signalling pathways, thus preventing cardiovascular diseases.<sup>11</sup> Additionally, betanin had been reported to inhibit key inflammatory enzymes, including cyclooxygenase (COX-2) and lipoxygenase (LOX), while also reducing inflammatory cell activity.<sup>12,13</sup> A common aetiology of necrosis was hypoxia, while oxidative stress represented another contributing factor. Betanin, recognised for its antioxidant potential, may contribute to the long-term reduction of necrosis, albeit to a limited extent in the current study. Nevertheless, the observed reduction in inflammation reaffirmed the potential of red beetroot extract in promoting favourable wound healing outcomes, particularly in terms of inflammation.

Ozonated olive oil emerged as a potent anti-inflammatory agent, particularly during the chronic phase of wound healing. It consistently prevented congestion, fibrosis, and bleeding at all stages and exhibited a notable inhibitory effect on necrosis in the chronic phase. Extensive research has already explored the effects of ozonated olive oil on wound healing, substantiating its multifaceted benefits.<sup>14</sup> Ozonated olive oil had been shown to enhance the production of growth factors, fibroblasts, and collagen, concurrently reducing inflammation and facilitating wound nutrition through increased angiogenesis.<sup>15,16</sup> Furthermore, ozonated oil's capacity to facilitate oxygen diffusion may contribute to its role in preventing necrosis.

Conversely, physiological saline did not exhibit significant anti-inflammatory effects and failed to prevent necrosis in the acute phase or fibrosis in the chronic phase. While physiolog-

ical saline is widely regarded as a compatible irrigation and wound dressing solution, the observation of congestion and bleeding in the saline group contradicted prior studies that have not reported such effects.<sup>17</sup> These findings suggested that additional factors may be at play in influencing wound healing outcomes.

Evaluation of serum oxidant and antioxidant levels highlighted the robust antioxidant properties of red beetroot extract, a finding substantiated by the TOS values. Betalain compounds, well-documented for their antioxidant activities, had been reported to mitigate oxidative stress at both tissue and organ levels.<sup>13</sup> A previous research had demonstrated the antioxidant potential of betanin, particularly in the context of spinal cord ischemia-reperfusion and protection against carbon tetrachloride-induced toxicity.<sup>18</sup> In this study, treatment with red beetroot extract led to a significant increase in antioxidant parameters (serum total thiol, native thiol, and paraoxonase), accompanied by a significant decrease in oxidant parameters (TOS) when compared to the other groups (Table II). This antioxidant capacity can be attributed to the secondary metabolites contained within beetroot. It is important to acknowledge the limitations of this study. Due to technical constraints, the authors were unable to evaluate fibroblast counts in the tissue and Matrix Metalloproteinases-2 (MMP-2), which are relevant factors in wound healing. Future research endeavours should be considered addressing these aspects to provide a more comprehensive understanding of the wound-healing mechanism.

## CONCLUSION

While red beetroot extract demonstrated anti-inflammatory properties and the capacity to ameliorate necrosis, ozonated olive oil emerged as a robust anti-inflammatory agent with broad benefits in wound healing. These findings emphasised the multifaceted nature of wound healing and the potential of natural compounds, such as red beetroot extract and ozonated olive oil to enhance this intricate process.

### ETHICAL APPROVAL:

This study was approved by the Aydin Adnan Menderes University Animal Experiments Local Ethics Committee (Date: 22/04/2021, Number: 64583101/2021/068).

### COMPETING INTEREST:

The authors declared no competing interest.

### AUTHORS' CONTRIBUTION:

SA: Study design, pharmaceutical applications, article writing.

YO: Project manager, literature review.

SO: Literature review, methodology.

SG: Statistical analysis, article editing.

CT: Pathological evaluations, tissue evaluation.

All authors approved the final version of the manuscript for publication.

## REFERENCES

- Rodrigues M, Kosaric N, Bonham CA, Gurtner GC. A Cellular Perspective. *Physiol Rev* 2019; **99**: 665-706. doi: 10.1152/physrev.00067.2017.
- Hoffmann J, Gendrisch F, Schempp CM, Wölflle U. New Herbal Biomedicines for the topical treatment of dermatological disorders. *Biomedicines* 2020; **8**(2):27. doi: 10.3390/biomedicines8020027.
- Sancar B, Canbulat S, Erkal SI. Yara bakımında kullanılan bitkisel yöntemler ve hemsirelik. *Türkiye Klinikleri. J Intern Med Nurs-Special Topics* 2017; **3**(2): 116-24.
- Vieira Teixeira da Silva D, Dos Santos Baião D, de Oliveira Silva F, Alves G, Perrone D, Mere Del Agnila E, et al. Betanin, a natural food additive: Stability, bioavailability, antioxidant and preservative ability assessments. *Molecules* 2019; **24**(3):458. doi: 10.3390/molecules24030458.
- Sistani KN, Ardeshtir A, Anahita R, Marzieh P, Hamed R. Gastroprotective effects of betanin against ethanol-induced gastric ulcer in rats, jundishapur. *J Nat Pharm Prod* 2019; **14**(3):e14473. doi: 10.5812/jjnpp.14473.
- Shedoeva A, Leavesley D, Upton Z, Fan C. Wound healing and the use of medicinal plants. *Evid Based Complement Alternat Med* 2019; **2019**:2684108. doi:10.1155/2019/2684108.
- Donato-Trancoso A, V de Carvalho Faria R, C de S Ribeiro B, Nogueira JS, Atella GC, Chan L, et al. Dual effects of extra virgin olive oil in acute wounds. *Wound Repair Regen* 2023; **31**(3):338-48. doi:10.1111/wrr.13082.
- Zcharia E, Zilka R, Yaar A. Heparanase accelerates wound angiogenesis and wound healing in mouse and rat models. *FASEB J* 2005; **19**(2):211-21. doi:10.1096/fj.04-1970com.
- Tural K, Ozden O, Bilgi Z, Kubat E, Ermutlu CS, Merhan O, et al. The protective effect of betanin and copper on spinal cord ischemia-reperfusion injury. *J Spinal Cord Med* 2021; **44**(5):704-10. doi: 10.1080/10790268.2020.1737788.
- Chen L, Zhu Y, Hu Z, Wu S, Jin C. Beetroot as a functional food with huge health benefits: Antioxidant, antitumor, physical function, and chronic metabolomics activity. *Food Sci Nutr* 2021; **9**(11): 6406-20. doi:10.1002/fsn3.2577.
- Silva DVTD, Baião DDS, Ferreira VF, Paschoalin VMF. Betanin as a multipath oxidative stress and inflammation modulator: A beetroot pigment with protective effects on cardiovascular disease pathogenesis. *Crit Rev Food Sci Nutr* 2022; **62**(2):539-54. doi: 10.1080/10408398.2020.1822277.
- Martinez RM, Hohmann MS, Longhi-Balbinot DT, Zarpelon AC, Baracat MM, Georgetti SM, et al. Analgesic activity and mechanism of action of a Beta vulgaris dye enriched in betalains in inflammatory models in mice. *Inflammopharmacology* 2020; **28**(6):1663-75. doi:10.1007/s10787-020-00689-4.
- Ahmadi H, Nayeri Z, Minuchehr Z, Sabouni F, Mohammadi M. Betanin purification from red beetroots and evaluation of its anti-oxidant and anti-inflammatory activity on LPS-activated microglial cells. *PLoS One* 2020; **15**(5):e0233088. doi:10.1371/journal.pone.0233088.
- Anzolin AP, da Silveira-Kaross NL, Bertol CD. Ozonated oil in wound healing: What has already been proven? *Med Gas Res* 2020; **10**(1):54-9. doi:10.4103/2045-9912.279985.
- Guzel O, Yildar E, Erdikmen DO. Medical ozone and its use in veterinary surgery. *Istanbul Univ Vet Fak Derg* 2011; **37**(2):177-84.
- Krkl C, Yigit MV, Ozercan IH, Aygen E, Gulturk B, Artas G. The effect of ozonated olive oil on neovascularization in an experimental skin flap model. *Adv Skin Wound Care* 2016; **29**(7):322-7. doi:10.1097/01.ASW.0000484172.04260.46.
- Guo S, Dipietro LA. Factors affecting wound healing. *J Dent Res* 2010; **89**(3):219-29. doi:10.1177/0022034509359125.
- lahtisham-UI-Haq, Butt MS, Randhawa MA, Shahid M. Hepatoprotective effects of red beetroot-based beverages against CCl<sub>4</sub> -induced hepatic stress in Sprague Dawley rats. *J Food Biochem* 2019; **43**(12):e13057. doi:10.1111/jfb.13057.

.....