

Digital Necrosis Due to Septic Embolism: An Unseen Complication of Gangrenous Cholecystitis

Nazmi Ozer and Abdullah Sahin

Department of General Surgery, Adana City Training and Research Hospital, University of Health Sciences, Adana, Turkey

ABSTRACT

Gangrenous cholecystitis is one of the most severe complications of cholelithiasis. It causes serious morbidity and mortality. The main pathology in this complication is progressive vascular insufficiency, which may lead to necrosis and perforation of the gallbladder wall. Vascular insufficiency can affect other organs besides the gallbladder. Since its symptoms are not different from that of acute cholecystitis, delayed diagnosis and treatment can cause death. Treatment is a surgical intervention as soon as the diagnosis is made. Complications such as wound infection, intra-abdominal abscess, circulatory disorders, and lung problems can be seen in the postoperative period. Embolism and necrosis in distant organs as a complication of gangrenous cholecystitis have not been reported till date. In this case, we present a patient, who developed necrosis of the fingers and toes due to septic embolism as a complication of gangrenous cholecystitis.

Key Words: *Cholelithiasis, Acute cholecystitis, Gangrene, Necrosis.*

How to cite this article: Ozer N, Sahin A. Digital Necrosis Due to Septic Embolism: An Unseen Complication of Gangrenous Cholecystitis. *J Coll Physicians Surg Pak* 2022; **32(12)**:1620-1622.

INTRODUCTION

Gangrenous cholecystitis is one of the most severe forms of acute cholecystitis and it can develop in 2-29% of patients with cholecystitis.¹⁻³ It occurs with venous and arterial insufficiency followed by ischemia and necrosis as a result of the progression of inflammation in the gallbladder.^{4,5}

Since most of the patients are of advanced age and have additional diseases such as hypertension, coronary artery disease, and diabetes mellitus that cause micro and macrocirculatory disturbances, vascular insufficiency can manifest its effects more easily in all organs and prepare the ground for complications.⁶

The circulatory disturbance in gangrenous cholecystitis patients can affect not only the gastrointestinal system but all systems.⁷ In addition to gangrene of the gallbladder, problems that have never been seen before such as embolism and necrosis in distant organs may occur.

In this case report, we present a male patient who developed digital necrosis due to septic embolism after gangrenous cholecystitis.

CASE REPORT

An 84-year male patient, with history of inguinal hernia surgery, hypertension for 25 years, and diabetes mellitus for 30 years, presented with a complaint of abdominal pain that was intermittent for about 1 year. The pain has gradually intensified over the past 1 week. He was admitted to the emergency service with the addition of nausea and vomiting to this condition. On physical examination, guarding and rebound tenderness was positive in the right upper quadrant. Vital signs showed fever of 38.2°C, pulse rate, 100/minute, blood pressure, 100/80 mmHG, and respiratory rate, 24/minute.

The laboratory results showed white blood cell (WBC) count of 21,000/ μ L; haemoglobin, 13.5 g/dl; platelets, 273,000/ μ L; glucose, 170 mg/dl; C-reactive protein (CRP), 417 mg/L; urea, 148 mg/dl; creatinine, 1.89 mg/dl; aspartate aminotransferase (AST), 105 U/L; and alanine aminotransferase (ALT), 177 U/L.

In imaging examinations, there was no significant finding on radiography of the chest and abdominal X-ray. In abdominal tomography investigation, free fluid was observed in perhepatic and persplenic areas, along with diffuse thickening of gallbladder wall. The wall thickness of the fundus was about 1.5 cm and there was wall irregularity. These findings were suspicious in terms of perforation (Figure 1a).

The patient was admitted to the surgical intensive care unit (SICU) with a preliminary diagnosis of gallbladder perforation, sepsis, and multi-organ failure. Intravenous (iv) hydration (1000 cc isotonic saline) and antibiotic treatment (Ceftriaxone, 2x1 g and Metronidazole, 3x500 mg) were started. He was later taken into operation; the abdomen was entered with the right

Correspondence to: Dr. Nazmi Ozer, Department of General Surgery, Adana City Training and Research Hospital, University of Health Sciences, Adana, Turkey
E-mail: nazmiozer83@gmail.com

Received: July 15, 2020; Revised: November 28, 2020;

Accepted: December 23, 2020

DOI: <https://doi.org/10.29271/jcpsp.2022.12.1620>

subcostal incision. On exploration, the gallbladder was found to be gangrenous and there was one small perforation area in the fundus and minimal fluid around the gallbladder. Culture was taken from the fluid, and the patient underwent cholecystectomy procedure. After the site of the surgery was washed with plenty of isotonic saline, a drain was placed in the site and the layers were closed duly (Figure 1b).

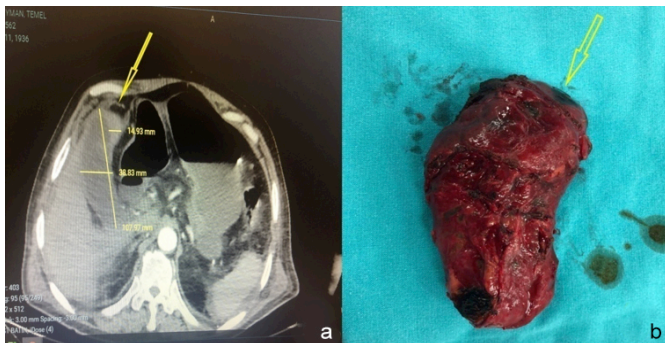


Figure 1: (a) Diffuse thickening of the gallbladder wall and wall irregularity in the fundus on abdominal tomography (yellow arrow). (b) Macroscopic gangrenous appearance of the gallbladder, with a small perforation area (yellow arrow).

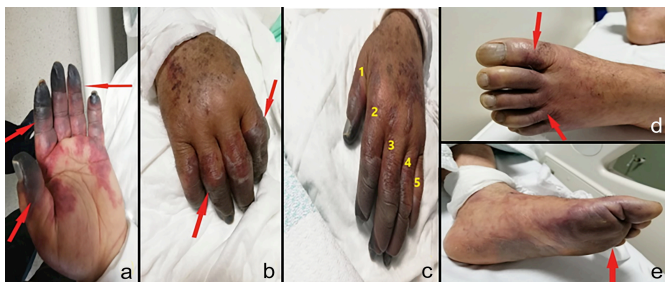

Figure 2: (a) Necrotic areas and demarcation lines in the distal metacarpals on the left-hand palmar side (red arrows). (b) Necrotic areas and demarcation lines in the distal metacarpals on the right-hand dorsal side (red arrows). (c) Numbering of fingers and view of the left hand from the dorsal side. (d,e) Starting points of ecchymosis on the feet from the dorsal and palmar side (red arrows).

The patient continued to receive (iv) hydration (1500 cc isotonic saline and 1500 cc buffered 5% dextrose). After the growth of *proteus mirabilis* in the culture, antibiotic was changed to meropenem, 3x1 g. On the third post-operative day, bruises and color changes were noted on the patient's hands and feet, and consultation was requested from the cardiovascular surgery with a preliminary diagnosis of embolism. Cardiovascular surgery recommended heparinisation and follow-up of the patient because the patient's pulses were full and his extremities were hot; Clexane 0.4 cc (Enoxaparine sodium, anti-Xa /0.4 ml) was started subcutaneous. On 5th postoperative day, ischemia became prominent in the distal phalanges of fingers and toes and turned into necrosis (Figure 2). On reassessment of the patient, on doppler ultrasound requested by cardiovascular surgery, blood flow was not observed in multiple fingers and toes of both hands and feet (Figure 2) and cardiovascular surgery suggested amputation of necrotic finger and toe tips. The patient was referred to orthopaedic clinic for digital amputation. Necrotic ends of all digits were amputated. On 5th postoperative day, efflux ion started from the stumps of the patient's

amputated fingers. Culture was sent, which grew *Proteus mirabilis* and *Escherichia Coli*. It was thought that the patient's condition occurred due to septic embolism. The antiriot therapy was changed again and Tazocin (piperacillin and tazobactam, 3x4.5 g) and Amikacin (amikacin sulfate, 1x1 g) were started. On follow-up, the general condition of the patient improved, and the drain of the patient was removed when nothing came from the abdominal drain. The efflux ion from the stump ceased on 15th postoperative day, and the patient, whose vital signs were stable and who was in good general condition, was discharged on the 21st day of hospitalisation.

DISCUSSION

Several predisposing factors play a role in the progression of patients with acute cholecystitis to gangrenous cholecystitis. These are the conditions which disturb the micro and macrovascular circulation such as delayed surgery, advanced age, male gender, cardiovascular disease, and diabetes mellitus.^{8,9}

Micro and macrovascular circulatory disorders in gangrenous cholecystitis cause additional problems in patients. In this case report, a serious complication, septic embolism leading to digital necrosis and amputation, was observed, which has not been reported previously.

On review of diseases causing digital necrosis in the literature, in a series of 23 patients, systemic lupus erythematosus was implicated in 5 cases, Sjogren's syndrome in 4 cases, Behçet's disease in 3 cases, paraneoplastic syndrome due to thyroid malignancy in 1 case and scleroderma disease in 10 cases. No cases of cholecystitis were encountered.¹⁰

In another study, a case of digital necrosis due to septic embolism was reported in a 19-year-old patient as a result of upper respiratory tract infection.¹¹

While there is a case of gangrenous cholecystitis developing after the orthopaedic surgery in the literature, no case developing septic embolism and digital necrosis after gangrenous cholecystitis was found.¹²

In conclusion, clinicians should be vigilant for gangrenous cholecystitis, especially in patients with additional diseases that can cause circulatory disturbances, in cases of cholelithiasis and especially acute cholecystitis. It should be kept in mind that gangrenous cholecystitis may cause simple complications such as wound infection, as well as life-threatening complications such as septic embolism leading to loss of extremity. With early diagnosis and surgical intervention, the main pathology will be eliminated and complications will be prevented.

PATIENT'S CONSENT:

Informed consent was obtained from the patient who participated in this study.

COMPETING INTEREST:

The authors declared no competing interest.

AUTHORS' CONTRIBUTIONS:

NO: Concept, data collection, analysis, and critical reviews.

AS: Design, supervision, literature search, and manuscript writing.

All the authors have approved the final version of the manuscript to be published.

REFERENCES

1. Chang WC, Sun Y, Wu EH, Kim SY, Wang ZJ, Huang GS. et al. CT findings for detecting the presence of gangrenous ischemia in cholecystitis. *Am J Roentgenol* 2016; **207(2)**: 302-9. doi: 10.2214/AJR.15.15658.
2. Real-Noval H, Fernández-Fernández J, Soler-Dorda G. Predicting factors for the diagnosis of gangrene acute cholecystitis. Factores predictores para el diagnóstico de la colecistitis aguda gangrenosa. *Cirugia Y Cirujanos* 2019; **87(4)**:443-9. doi: 10.24875/CIRU.18000706.
3. Önder A, Kapan M, Ülger BV, Oğuz A, Türkoğlu A, Uslukaya Ö. Gangrenous cholecystitis: Mortality and risk factors. *Int Surg* 2015; **100(2)**:254-60. doi: 10.9738/INTSURG-D-13-00222.1.
4. Aydın C, Altaca G, Berber I, Tekin K, Karam, Titiz I. Prognostic parameters for the prediction of acute gangrenous cholecystitis. *J Hepatobiliary Pancreat Surg* 2006; **13(2)**:155-9. doi: 10.1007/s00534-005-1042-8.
5. Nikfarjam M, Niumsawatt V, Sethu A, Fink MA, Muralidharan V, Starkey G, et al. Outcomes of contemporary management of gangrenous and non-gangrenous acute cholecystitis. *HPB* 2011; **13(8)**:551-8. doi: 10.1111/j.1477-2574.2011.00327.x.
6. Dubecz A, Langer M, Stadlhuber RJ, Schweigert M, Solymosi N, Feith M, Stein HJ. Cholecystectomy in the very elderly is 90 the new 70? *J Gastrointest Surg* 2012; **16(2)**:282-5. doi: 10.1007/s11605-011-1708-2.
7. Indar AA, Beckingham IJ. Acute cholecystitis. *BMJ* 2002; **325(7365)**:639-43. doi: 10.1136/bmj.325.7365.639.
8. Fagan SP, Awad SS, Rahwan K, Hira K, Aoiki N, Itani KMF, et al. Prognostic factors for the development of gangrenous cholecystitis. *Am J Surg* 2003; **186(5)**:481-5. doi: 10.1016/j.amjsurg.2003.08.001.
9. Habib FA, Kolachalam RB, Khilnani R, Preventza O, Mittal VK. Role of laparoscopic cholecystectomy in the management of gangrenous cholecystitis. *Am J Surg* 2001; **181(1)**:71-5. doi: 10.1016/s0002-9610(00)00525-0.
10. Aydi Z, Rachdi I, Ben DB, Baili L, Daoud F, Boussema F. Etiologic profile of digital necrosis in an internal medicine department. *Tunis Med* 2015; **93(5)**:308-311.
11. Shiber JR, Wooten SL. Images in emergency medicine. Digital septic emboli. *Ann Emerg Med* 2007; **50(6)**:740-8. doi: 10.1016/j.annemergmed.2007.04.020.
12. Cheikhrouhou H, Jmal K, Kharrat A, Keskes M, Karoui A. Cholécytite aigue gangréneuse alithiasique en postopératoire d'une chirurgie orthopédique: A propos d'un cas [Acute acalculous gangrenous cholecystitis in postoperative period after orthopedic surgery: About a case]. *Pan Afr Med J* 2017; **27**:8. doi:10.11604/pamj.2017.27.8.11526.

• • • • •