

Thrombocytopenia Caused by Iron Infusion in a Patient with End-Stage Kidney Disease

Sir,

A 60-year male patient, with dialysis-dependent End-stage Kidney Disease (ESKD), was admitted to the hospital with uncontrolled blood pressure. His blood pressure was controlled within 24 hours of admission on adjustment of anti-hypertensive medications. On evaluation of anaemia, he had iron deficiency with haemoglobin (Hb) of 8.0 g/dl, platelets, $177 \times 10^9/L$, and transferrin saturation of 14%. Intravenous iron sucrose 100 mg infusion per haemodialysis was started. A drop in platelet count was observed just after infusing 1st dose of iron. A total of three doses of iron were infused, each on an alternate day. His platelet count continued to decline to $14 \times 10^9/L$ till Day 7. On review of medications being taken by the patient, no drug was found that could cause thrombocytopenia, except for iron. Workup for the acute drop in platelets showed normal fibrinogen degradation products (FDPs), D-dimer, fibrinogen, liver function tests (LFTs), PT/APTT/INR, and lactate dehydrogenase (LDH) level. Peripheral blood film was negative for any schistocyte. Tests for Dengue, malaria, and Hepatitis B and C were negative. Ultrasound abdomen was negative for any visceral abnormality or lymphadenopathy. Intravenous iron was then stopped and his platelets started improving. On Day 6 of stopping iron, his platelets improved to $90 \times 10^9/L$ and normalised to $209 \times 10^9/L$ on OPD follow-up (Figure 1).

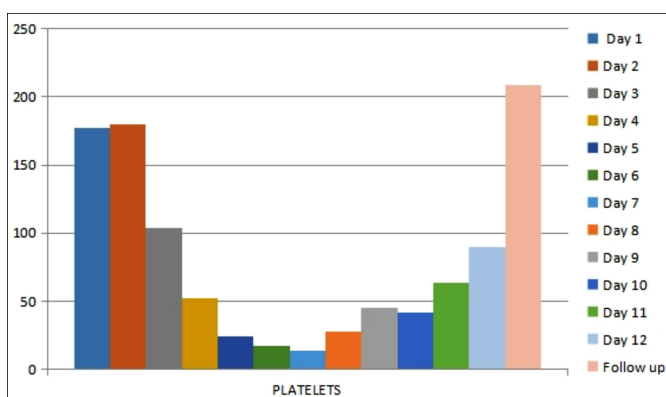


Figure 1: Trend of platelet count.

Haematological disorders including anaemia and thrombocytopenia are common in ESKD patients.¹ The use of erythropoiesis-stimulating agents (ESA) and iron supplementation is routine for ESKD patients.² Drug-induced thrombocytopenia is the most common cause of thrombocytopenia in patients with ESKD.³ Iron infusion as a cause of thrombocytopenia in ESKD is rare⁴ and can be diagnosed after excluding other causes

including sepsis, vitamin B12 deficiency, chronic liver disease, and malignancy. Bone marrow biopsy may be required. However, diagnosis can be established on clinical grounds if platelet count starts to improve after stopping iron therapy.

The pathogenetic explanations for iron-induced thrombocytopenia include stem cell trafficking phenomenon (adequate iron store), stem cell steal phenomenon (inadequate iron store), and an idiosyncratic phenomenon.⁵ In this case, the authors observed improvement in platelet count within 2 days of stopping intravenous iron, and platelet normalised to $209 \times 10^9/L$ within 1 month.

COMPETING INTEREST:

The authors declared no competing interest.

AUTHORS' CONTRIBUTION:

KN, SB, AH: Contributed to literature search and manuscript writing.

All authors approved the final version of the manuscript to be published.

REFERENCES

- Atkinson Meredith A, Warady BA. Anaemia in chronic kidney disease. *Pediatric Nephrol* 2018; **33(2)**:227-38. doi: 10.1007/s00467-017-3663-y.
- Gafter-Gvili, A, Schechter A, Rozen-Zvi B. Iron deficiency anaemia in chronic kidney disease. *Acta Haematol* 2019; **142(1)**:44-50. doi: 10.1159/000496492.
- Kahraman C, Ucgün S, Kahraman NK. Intravenous iron infusion induced severe temporary thrombocytopenia case in iron deficiency anaemia: A review. *Ann Med Educ* 2016; **3**:7-10.
- Kalpathi R, Kiss JE. Thrombotic thrombocytopenic purpura, heparin-induced thrombocytopenia, and disseminated intravascular coagulation. *Critical Care Clinics* 2020; **36(2)**:357-77. doi: 10.1016/j.ccc.2019.12.006.
- Go RS, Porrata LF, Call TG. Thrombocytopenia after iron dextran administration in a patient with severe iron deficiency anaemia. *Ann Intern Med* 2000; **132(11)**:925. doi: 10.7326/0003-4819-132-11-200006060-00025.

Shaheen Bibi, Kunwer Naveed and Abdul Haq

Department of Nephrology, Liaquat National Hospital, Karachi, Pakistan

Correspondence to: Dr. Shaheen Bibi, Department of Nephrology, Liaquat National Hospital, Karachi, Pakistan
E-mail: shaheensultan51@gmail.com

Received: April 28, 2023; Revised: June 03, 2023;

Accepted: June 05, 2023

DOI: <https://doi.org/10.29271/jcpsp.2023.11.1337>