

# Proximity of Roots of Posterior Teeth to Maxillary Sinus in Different Facial Biotypes

Neha Arshad<sup>1</sup>, Erum Amin<sup>1</sup>, Ahsan Malik<sup>2</sup>, Zainab Bint-e-Nasir<sup>1</sup> and Mahrukh Zafar<sup>3</sup>

<sup>1</sup>Department of Orthodontics, Armed Forces Institute of Dentistry, Rawalpindi, Pakistan

<sup>2</sup>Department of Dental Education, Foundation University Islamabad, Islamabad, Pakistan

## ABSTRACT

**Objective:** To evaluate the relationship between maxillary posterior teeth roots to maxillary sinus floor (MSF) using three-dimensional imaging and to evaluate the correlation of vertical facial biotype, gender, and age to the proximity of posterior roots to the sinus.

**Study Design:** Observational, Cross-sectional study.

**Place and Duration of the Study:** Department of Orthodontics, Armed Forces Institute of Dentistry, Combined Military Hospital, Rawalpindi, from January 2021 to July 2022.

**Methodology:** Three-dimensional CBCT scans of 100 patients aged between 13 to 43 years were evaluated and divided into three matching groups based on vertical face forms i.e. hyperdivergent, normodivergent, and hypodivergent. Root proximity to maxillary sinus was scored (0-3) for each scan. Nonparametric Wilcoxon Mann Whitney U test and Kruskal Wallis test were used to compare average tooth and patient scores to vertical face type, age, and gender.

**Results:** Out of 100 patients, 54 were males and 46 were females with 44% aged between 13-23 years, 27% between 24 to 33 years, and 29% between 34 to 43 years. Average patient and tooth scores were highest in the hyperdivergent face type ( $p < 0.001$ ). No statistically significant relation was found between gender and degree of root proximity to MSF ( $p > 0.05$ ). Age was negatively correlated to root sinus wall connection ( $p < 0.001$ ).

**Conclusion:** Patients with hyperdivergent face forms are at greater risk of root resorption and prolonged orthodontic treatment due to the closer proximity of root apices to the maxillary sinus as compared to hypodivergent and normodivergent face forms. Moreover, roots were farther from the maxillary sinus wall with advanced age.

**Key Words:** Maxillary sinus, Cone beam computed tomography, Face.

**How to cite this article:** Arshad N, Amin E, Malik A, Nasir ZBE, Zafar M. Proximity of Roots of Posterior Teeth to Maxillary Sinus in Different Facial Biotypes. *J Coll Physicians Surg Pak* 2023; **33(07)**:732-737.

## INTRODUCTION

Maxillary sinuses, or antrum of Highmore, are the largest pyramidal-shaped paranasal sinuses that are located in maxilla. They are smaller in size at birth and enlarge gradually by the process of physiological pneumatization that increases around 12 years of age and ceases around the second decade of life when third molar has erupted completely.<sup>1</sup> A periosteal-lined layer of cortical bone makes up the maxillary sinus wall.<sup>2</sup> The topographical relationship between the maxillary sinus wall and the posterior teeth roots is a crucial factor in the prognosis of orthodontic tooth movement; tooth movement against the cortical bone of the sinus might result in root resorption.<sup>3</sup>

genetic predisposition, magnitude of the applied force, anatomy of bone surrounding teeth and proximity of root apex to the maxillary sinus wall. It can also result in slower rate of tooth movement and longer treatment duration.<sup>4</sup> Sun *et al.* concluded that it is possible to move teeth orthodontically through the maxillary sinus, however, root resorption can occur if teeth, tip instead of undergoing bodily movement. Therefore, in order to effectively plan orthodontic therapy, it is essential to accurately determine how the posterior maxillary teeth relate to the maxillary sinus wall, especially in cases that require intrusion of posterior maxillary teeth, distalisation, protraction, extraction or correction of severely displaced or impacted teeth, dental implants insertion and orthognathic surgery.<sup>5-8</sup>

Using two-dimensional imaging to assess the relation between the maxillary sinus and the roots of posterior teeth is not particularly precise. Often occurring issues include image distortion, magnification, image blurring, and superimposition of anatomical components. On the other hand, three-dimensional imaging through Cone Beam Computed Tomography (CBCT) gives more accurate information regarding proximity of root apices to the maxillary sinus wall.<sup>9</sup>

Correspondence to: Dr. Neha Arshad, Department of Orthodontics, Armed Forces Institute of Dentistry, Rawalpindi, Pakistan  
E-mail: neha13dec@hotmail.com

Received: March 06, 2023; Revised: May 06, 2023;

Accepted: June 13, 2023

DOI: <https://doi.org/10.29271/jcpsp.2023.07.732>

The common risk factors associated with root resorption are

The postnatal facial growth and enlargement of maxillary sinus

are positively correlated.<sup>10</sup> The vertical development pattern of the face may consequently be related to how close the posterior maxillary teeth are to the maxillary sinus. Therefore, the goal of this study was to evaluate the relationship between the posterior maxillary teeth's roots and the maxillary sinus wall in various skeletal face types, which can aid in comprehensive treatment planning for orthodontic patients.

## METHODOLOGY

The current cross-sectional study was conducted at the Armed Forces Institute of Dentistry, Combined Military Hospital, Rawalpindi, following approval from the Institute Research Ethical Committee. OpenEpi 3.01 was used to determine the sample size, based on the study by Costea *et al.* The level of confidence was kept at 95%, and the absolute precision was preserved at 5%. Ninety-seven scans made up the sample size. CBCT data were collected from the Radiology Department from January 2021 to July 2022. CBCT scans were performed for treatment planning in orthodontic and orthognathic cases, impacted canines, dental implants, and various surgical procedures. Those scans were selected from patients of either gender between 13-43 years of age, visually clear, showing maxillary posterior teeth with complete root formation (excluding third molars), on both the right and the left sides.

Exclusion criteria were pathology of maxillary sinus or root apices of posterior maxillary teeth, facial asymmetry or craniofacial deformities, genetic syndromes or deformities such as cleft lip and palate, patient with history of orthodontic treatment, history of surgery or trauma in maxillofacial region and temporomandibular joint disorder.

CBCT images were taken using NewTom VGi machine. All images were acquired at 110kV and 6.11mA voxel size with exposure time of 3.6s. For image viewing and analysis, Newtom Software was used. Brightness and contrast of images were adjusted by using the tools in the software for optimal visualisation. Lateral cephalograms were reconstructed from CBCT images (Figure 1). The cephalometric landmarks included Orbitale, Porion, Gonion, and Menton. Frankfurt Mandibular Plane Angle (FMA) was defined as the angle formed between Frankfurt horizontal plane and mandibular plane, and used to categorise subjects into the following face types as normodivergent (FMA 22°-28°), hypodivergent (FMA <22°), and hyperdivergent (FMA >28°). Each subject's maxillary posterior teeth, including the first and second premolars and molars on both the right and left sides, were analysed. On CBCT scans, proximity of roots of posterior teeth to maxillary sinus floor (MSF) was scored using Jung and Cho classification as illustrated in Figure 2.<sup>11</sup>

In addition, subjects were divided into three groups depending on age, with a ten-year gap between each group.

The average patient score was determined for each patient by adding all of the patient's root scores and dividing the result by the total number of roots for the patient. Similarly for each tooth, an average score was determined by summing the scores of the left and right roots and dividing the result by the total number of left

and right roots in the tooth. The statistical analysis was carried out using SPSS version 26.0. For average tooth scores and patient scores, the data were described as mean, median, mode, and standard deviation. Using the Shapiro-Wilk test, the data's normality was examined. Non-parametric tests were done since the data were not normally distributed. Comparison of right and left sides was done using Wilcoxon signed rank test. Mann Whitney U test was used to examine differences depending on gender. Spearman's rho correlation and Kruskal Wallis test were used to compare tooth and patient scores with the age of patients. The average tooth and patient scores were compared with facial biotypes using the Kruskal Wallis test with pairwise comparison. The level of significance was set at 5% or 0.05.

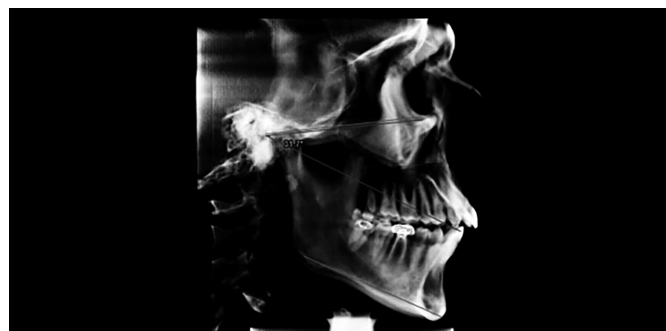

Figure 1: Lateral Cephalogram reconstructed from CBCT.

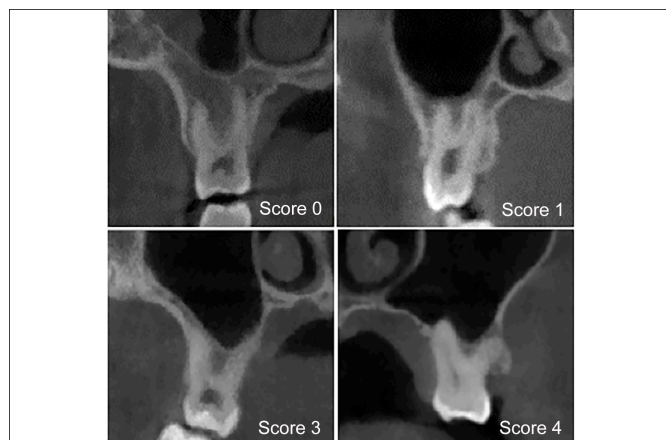


Figure 2: Association between the maxillary sinus floor and the posterior tooth root apex according to the Jung and Cho classification: 0 = Root apex away from MSF with a portion of spongy bone in between. 1 = Root apex contacting the MSF. 2 = Root apex projecting laterally along the sinus/MSF interposed between the roots. 3 = Root apex projecting into the maxillary sinus.

## RESULTS

Eight teeth per patient, or a total of 800 teeth, were evaluated in 100 individuals. The mean age of the subjects was  $26.54 \pm 8.46$  years with 54% males (n=54). Out of 100 patients, 44% aged between 13-23 years, 27% between 24 to 33 years, and 29% between 34 to 43 years. Based on vertical facial type, the study recruited an almost equal number of patients in each group *i.e.*, 33 patients with normodivergent face type, 33 patients with hypodivergent profile, and 34 patients with hyperdivergent facial profile.

**Table I: Central tendency and variability of all tooth scores and patient scores.**

Variables	Average tooth score for first premolars	Average tooth score for second premolars	Average tooth score for first molars	Average tooth score for second molars	Average patient score
Mean	0.1700	0.9300	1.3986	1.2494	1.0140
Median	0.0000	1.0000	1.3300	1.1700	0.8900
Mode	0.00	1.00	2.00	0.83	0.61
Std. deviation	0.46177	0.92665	0.78295	0.66440	0.57946
Variance	0.213	0.859	0.613	0.441	0.336

**Table II: Comparison of tooth and patient scores with age.**

Age categories	Age 13-23 years		Age 24-33 years		Age 34-43 years		Test statistics	p-value
	Mean Score ± SD	Mean rank	Mean score ± SD	Mean rank	Mean score ± SD	Mean rank		
Average patient score	1.38 ± 0.56	68.94	0.82 ± 0.39	41.15	0.64 ± 0.40	31.22	33.442	<0.001
Pair-wise comparison of age with average patient score								
Age vs. Average patient score	Test statistics		Standard error	Standard test statistic	Adj sig. (p-value)*			
Age 24-33 years MINUS age 13-23 years	27.795		7.09	3.99	<0.001			
Age 34-43 years MINUS age 13-23 years	37.719		6.93	5.44	<0.001			
Age 34-43 years MINUS age 24-33 years	9.924		7.75	1.28	0.602			

\*Significance values have been adjusted by the Bonferroni correction for multiple tests.

**Table III: Comparison of tooth and patient score with vertical facial types using Kruskal Wallis analysis.**

Variables	Hypodivergent		Normodivergent		Hyperdivergent		Test Statistics	p-value
	Mean Score ± SD	Mean Rank	Mean Score ±SD	Mean Rank	Mean Score ±SD	Mean Rank		
Average tooth score for 1 <sup>st</sup> premolars	0.00 ± 0.00	43.00	0.21 ± 0.53	52.09	0.29 ± 0.57	56.24	9.427	0.009
Average tooth score for 2 <sup>nd</sup> premolars	0.42 ± 0.47	35.55	0.91 ± 1.05	47.61	1.44 ± 0.88	67.82	23.276	<0.001
Average tooth score for 1 <sup>st</sup> molars	0.75 ± 0.50	26.77	1.41 ± 0.63	51.48	2.01 ± 0.64	72.57	42.137	<0.001
Average tooth score for 2 <sup>nd</sup> molars	0.73 ± 0.40	27.42	1.29 ± 0.56	52.79	1.71 ± 0.61	70.68	37.831	<0.001
Average patient score	0.53 ± 0.29	25.09	1.06 ± 0.51	53.26	1.44 ± 0.50	72.49	45.207	<0.001

The Jung and Cho classification was used to stratify the root proximity of the posterior teeth to MSF based on the right and left sides of the face and the type of tooth. The descriptive information about the scores for the distances between the sinus floor and the right and left side root tips showed that buccal and palatal roots of the maxillary first premolars were the farthest from MSF (both right and left), whereas the mesiobuccal roots of the maxillary first and second molars are the closest to MSF on both the right and left sides. The results of Wilcoxon Signed Rank test for comparison of tooth and patient scores of right versus left reinforced the descriptive findings, that the differences between the two sides were minimal.

Age-wise comparison of average patient score along with pair-wise comparison revealed a moderately negative correlation ( $r = -0.57$  for Spearman's rho correlation) for the average patient score with increasing age ( $<0.001$ ). Moreover, the results of Kruskal-Wallis also showed that the average patient score decreased with increasing age. The mean patient score decreased from  $1.38 \pm 0.56$  among individuals aged 13-23 years age to  $0.82 \pm 0.39$  in the

24-33 years age group, and further declined to  $0.64 \pm 0.40$  in the 34-43 years age group (Table II).

Gender-based comparison using Mann Whitney U test showed that the root apices in male subjects were relatively closer to the sinus floor than those of the female subjects. The largest difference between mean scores of males and females was recorded for second premolars and first molars *i.e.*, 0.24 and 0.22, respectively. However, the differences were not statistically significant for any of the tooth or patient score variables.

Table III shows the comparison between average tooth scores and average patient scores with facial biotype. The mean for various teeth in hypodivergent faces varied from 0 to 0.75. On the contrary, the roots of hyperdivergent face type had significantly higher proximity to MSF as compared to other face types, particularly among molars. The mean values for various teeth in hyperdivergent faces varied from 0.29 to 2.01. The average tooth and patient scores for normodivergent faces were between those of hypodivergent and hyperdivergent.

Pair-wise comparison showed statistically significant differences in the average patient score, average tooth scores for the second premolars, and both molars among different facial types. There were statistically significant differences between the normodivergent and hypodivergent faces, normodivergent and hyperdivergent faces, as well as between hyperdivergent and hypodivergent faces.

## DISCUSSION

Cone Beam Computed Tomography is a reliable diagnostic technology in dentistry. In orthodontics, it can be used to identify normal and abnormal anatomy, root length and morphology, locating supernumerary or impacted teeth, determining the association between arch size and tooth size, relation between maxilla and mandible, planning for orthognathic surgeries, and detecting TMJ status.<sup>12</sup> CBCT also shows precise proximity of root apices to the maxillary sinus. Kirkham-Ali *et al.* and Sun *et al.* found that an OPG shows reliable results when root tips are distant from the maxillary sinus wall.<sup>9,13</sup> However, a CBCT should be considered if the root tips are near to the sinus wall. Therefore, in this study, CBCT was used to assess the connection between the roots of the maxillary posterior teeth and the maxillary sinus floor (MSF).

Various complications related to the maxillary sinus and tooth root relationship have been reported in different fields of dentistry. In Orthodontics, complications such as root resorption, tooth tipping, delayed therapy, and mini-screw hazards have been reported. Cases which require intrusion of posterior teeth such as high-angle cases with open bite, demand special attention for proper assessment of this relationship to avoid complications during treatment.<sup>5</sup> The vertical face type and the position of the roots of the maxillary posterior teeth in relation to the maxillary sinus floor were shown to be statistically significantly correlated in this study (MSF). Maxillary teeth in subjects with hyperdivergent face type had greater proximity to the MSF as compared to other face types. This relationship is inverse of what would be generally expected. A shorter facial profile (hypodivergent) would be expected to have lesser distance between the root apices and MSF as compared to a relatively longer facial profile. However, this study's results provided evidence for opposite *i.e.*, more protrusion and proximity to MSF in participants with longer faces. The reason for this could be that participants with hyperdivergent face types generally have smaller maximal bite forces as compared to hypodivergent face types.<sup>14</sup> Patients with long faces have weaker masseter muscle and medial pterygoid muscle.<sup>15</sup> This can shift the natural remodelling process towards greater resorption of associated skeletal components according to Wolf's law, which can ultimately result in greater expansion and a larger volume of maxillary sinus. These results are in agreement with studies carried out by Costea *et al.* and Ahn *et al.*<sup>16,17</sup> In the current study according to tooth type, the first

molar showed highest proximity to MSF followed by second molar. However, a few other studies report that the second molar is closest to MSF;<sup>18,20</sup> this difference could be due to unaccounted for variables such as different ethnicities and races of study populations.

Furthermore, no gender or side-based statistically significant variation in root proximity to MSF was discovered in this study. Similar findings were observed by Motiwala *et al.*<sup>20</sup> On the contrary, a few of the other studies indicated that males have longer tooth roots, predisposing them to roots with closer proximity to MSF.<sup>2,17,18,21</sup> However, studies carried out in Chinese and Japanese populations state the opposite, that roots of posterior maxillary teeth are closer to MSF in females.<sup>22,23</sup> Therefore, evidence of root proximity to MSF based on gender is contradictory.

Age and average patient score were shown to be significantly negatively correlated; as age advances average patient score decreases. Smaller patient score indicates that posterior root apices are farther from MSF. In other words, the distance between posterior root apices and MSF increases with age. This finding is in line with the results of previous studies carried out on Pakistani, Chinese, and Japanese populations.<sup>20,22,23</sup> These results are strengthened by the observation that the maxillary sinus size fluctuates with age. A study conducted by Sarilita *et al.* found that maxillary sinus pneumatization begins during infancy and maximizes during second decade of life after which it starts decreasing gradually.<sup>24</sup> Moreover, the physiological process of tooth wear increases with aging. To compensate for reduced clinical crown height, slight extrusion of teeth to maintain occlusal contact can also increase distance between root apices and MSF.

The clinical importance of the findings of this study is that special care should be taken when planning for orthodontic tooth movement of posterior teeth, especially intrusions in hyperdivergent young patients with anterior open bite, as close proximity of posterior teeth to MSF in such patients can hinder the planned tooth movements and increase the risk of root resorption. Light forces should be used to prevent unwanted complications. It may be crucial to assess relation of posterior root apices to the maxillary sinus floor before starting orthodontic treatment, especially in young patients with hyper divergent face form. However, these findings are applicable to the studied population and should be considered with caution for others.

## CONCLUSION

The first and second maxillary molars' mesiobuccal root apices were situated closest to the maxillary sinus. The first premolars' root apices were the farthest away from the maxillary sinus floor. Gender does not significantly influence

where the roots of the posterior teeth are in reference to the maxillary sinus floor. Age does, however, have a negative correlation. The position of the apices of posterior teeth in respect to the maxillary sinus floor exhibits strong relationships with the vertical facial biotype. The greater proximity of the posterior root apices to the maxillary sinus floor was associated with hyperdivergent facial shape.

#### ETHICAL APPROVAL:

Ethical approval was granted by the Ethical Committee of the Institute.

#### PATIENTS' CONSENT:

Patients' consents were not required in this study as the data was taken from the patients' records without mentioning patient's personal details or pictures.

#### COMPETING INTEREST:

The authors declared no competing interest.

#### AUTHORS' CONTRIBUTION:

NA: Conception, design, data collection, manuscript writing.

EA: Conception, design, and supervision.

AM: Manuscript correction and data analysis.

ZN: Manuscript writing.

MZ: Data analysis and interpretation.

All the authors have approved the final version of the manuscript to be published.

## REFERENCES

- Scuderi AJ, Harnsberger HR, Boyer RS. Pneumatization of the paranasal sinuses: Normal features of importance to the accurate interpretation of CT scans and MR images. *AJR Am J Roentgenol* 1993; **160(5)**:1101-4. doi: 10.2214/ajr.160.5.8470585.
- Qin Y, Shu G, Xu T. Evaluation of the relationship between maxillary sinus wall and maxillary canines and posterior teeth using cone-beam computed tomography. *Med Sci Monit* 2020; **26**:e925384. doi: 10.12659/MSM.925384.
- Talo Yildirim T, Oztekin F, Tozum MD. Topographic relationship between maxillary sinus and roots of posterior teeth: A cone beam tomographic analysis. *Eur Oral Res* 2021; **55(1)**:39-44. doi: 10.26650/eor.20210052.
- Sun W, Xia K, Huang X, Cen X, Liu Q, Liu J. Knowledge of orthodontic tooth movement through the maxillary sinus: A systematic review. *BMC Oral Health* 2018; **18(1)**:91. doi: 10.1186/s12903-018-0551-1.
- Manea A, Dinu C, Baciut M, Buduru S, Almasan O. Intrusion of maxillary posterior teeth by skeletal anchorage: A systematic review and case report with thin alveolar biotype. *J. Clin. Med* 2022; **11(13)**:3787. doi: 10.1186/s12903-018-0551-1.
- Hui VLZ, Xie Y, Zhang K, Chen H, Han W, Tian Y, et al. Anatomical limitations and factors influencing molar distalisation. *Angle Orthod* 2022; **92(5)**:598-605. doi: 10.2319/092921-731.1.
- Kim SW, Lee IH, Kim SW, Kim DH. Points to consider before the insertion of maxillary implants: The otolaryngologist's perspective. *J Periodontal Implant Sci* 2019; **49(6)**:346-54. doi: 10.5051/jpis.2019.49.6.346.
- Loureiro RM, Collin J, Sumi DV, Araújo LC, Murakoshi RW, Gomes RLE, et al. Postoperative CT findings of orthognathic surgery and its complications: A guide for radiologists. *J Neuroradiol* 2022; **49(1)**:17-32. doi: 10.1016/j.neurad.2021.04.033.
- Kirkham-Ali K, La M, Sher J, Sholapurkar A. Comparison of cone-beam computed tomography and panoramic imaging in assessing the relationship between posterior maxillary tooth roots and the maxillary sinus: A systematic review. *J Investig Clin Dent* 2019; **10(3)**:e12402. doi: 10.1111/jicd.12402
- Rzysztńska A, Kulczyk T, Rewekant A, Sroka A, Jończyk-Potoczna K, Gawriółek K, et al. The association between maxillary sinus dimensions and midface parameters during human postnatal growth. *Biomed Res Int* 2018; **2018**: 6391465. doi: 10.1155/2018/6391465.
- Jung YH, Cho BH. Assessment of the relationship between the maxillary molars and adjacent structures using cone beam computed tomography. *Imaging Sci Dent* 2012; **42(4)**:219-24. doi: 10.5624/isd.2012.42.4.219.
- Alshammery FA. Three dimensional (3D) imaging techniques in orthodontics-an update. *J Family Med Prim Care* 2020; **9(6)**:2626-30. doi: 10.4103/jfmpc.jfmpc\_64\_20.
- Sun W, Xia K, Tang L, Liu C, Zou L, Liu J. Accuracy of panoramic radiography in diagnosing maxillary sinus-root relationship: A systematic review and meta-analysis. *Angle Orthod* 2018; **88(6)**:819-29. doi: 10.2319/022018-135.1.
- Kaur H, Singh N, Gupta H, Chakarvarty A, Sadana P, Gupta N, et al. Effect of various malocclusion on maximal bite force- a systematic review. *J Oral Biol Craniofac Res* 2022; **12(5)**:687-93. doi: 10.1016/j.jobcr.2022.08.009.
- Yamada T, Sugiyama G, Mori Y. Masticatory muscle function affects the pathological conditions of dentofacial deformities. *Jpn Dent Sci Rev* 2020; **56(1)**:56-61. doi: 10.1016/j.jdsr.2019.12.001.
- Costea MC, Bondor CI, Muntean A, Badea ME, Mesaroş AŞ, Kuijpers-jagtman AM. Proximity of the roots of posterior teeth to the maxillary sinus in different facial biotypes. *Am J Orthod Dentofacial Orthop* 2018; **154(3)**:346-55. doi: 10.1016/j.ajodo.2018.01.006.
- Ahn NL, Park HS. Differences in distances between maxillary posterior root apices and the sinus floor according to skeletal pattern. *Am J Orthod Dentofacial Orthop* 2017; **152(6)**:811-9. doi: 10.1016/j.ajodo.2017.05.021.
- Oishi S, Ishida Y, Matsumura T, Kita S, Sakaguchi-Kuma T, Imamura T, et al. A cone-beam computed tomographic assessment of the proximity of the maxillary canine and posterior teeth to the maxillary sinus floor: Lessons from 4778 roots. *Am J Orthod Dentofacial Orthop* 2020; **157(6)**:792-802. doi: 10.1016/j.ajodo.2019.06.018.
- Eid EA, El-Badawy FM, Hamed WM. Intrusion of maxillary molar roots into the maxillary sinus in a sample of the Egyptian population using cone beam computed tomography. *Egypt J Radiol Nucl Med* 2021; **52(1)**:163.
- Motiwala MA, Arif A, Ghafoor R. A CBCT based evaluation of

- root proximity of maxillary posterior teeth to sinus floor in a subset of Pakistani population. *J Pak Med Assoc* 2021; **71(8)**:1992-5. doi: 10.47391/JPMA.462.
21. Hu X, Lei L, Cui M, Huang Z, Zhang X. Anatomical analysis of periapical bone of maxillary posterior teeth: A cone beam computed tomography study. *J Int Med Res* 2019; **47(10)**: 4701-10. doi: 10.1177/0300060519860960.
22. Pei J, Liu J, Chen Y, Liu Y, Liao X, Pan J. Relationship between maxillary posterior molar roots and the maxillary sinus floor: Cone-beam computed tomography analysis of a western Chinese population. *J Int Med Res*; 2020; **48(6)**: 03000 60520926896. doi: 10.1177/0300060520926896.
23. Gu Y, Sun C, Wu D, Zhu Q, Leng D, Zhou Y. Evaluation of the relationship between maxillary posterior teeth and the maxillary sinus floor using cone-beam computed tomography. *BMC Oral Health* 2018; **18(1)**:164. doi: 10.1186/s12903-018-0626-z.
24. Sarilita E, Lita YA, Nugraha HG, Murniati N, Yusuf HY. Volumetric growth analysis of maxillary sinus using computed tomography scan segmentation: A pilot study of indonesian population. *Anat Cell Biol* 2021; **54(4)**:431-5. doi: 10.5115/acb.21.051.

•••••