

# Transcranial Sonographic Evaluation of Preterm Neonates Presenting with Seizures and Its Association with Intracranial Abnormalities

Zobia Saleem, Raham Bacha and Summan Hameed

*Department of Radiology and Medical Imaging, The University of Lahore, Lahore, Pakistan*

## ABSTRACT

This study aimed to determine the association of intracranial abnormalities through transcranial ultrasound in preterm neonates having seizures and to analyse them with preterm classes. It was a cross-sectional analytical study at the Radiology Department of Shalamar Hospital, Lahore. This study observed a total of 103 pretermers with a history of seizures through transcranial ultrasound. These pretermers were classified into three classes according to their gestational age. Abnormal cranial scans were found in 42 (40.8%) preterm infants, with ventriculomegaly and intracranial haemorrhage more common in 18.4% and 17.5% of neonates. The p-values for intracranial haemorrhage in classes I, II, and III were 0.016, 0.001, and <0.001, respectively, while ventriculomegaly in preterm classes II and III was 0.003 and <0.001, respectively. In all preterm categories, intracranial haemorrhage was found to be the most likely cause of seizures, which tended to increase with decreasing gestational age. However, ventriculomegaly was identified as a significant cause of seizures in preterm classes II and III but not in class I.

**Key Words:** *Cranial ultrasound, Preterm, Seizures.*

**How to cite this article:** Saleem Z, Bacha R, Hameed S. Transcranial Sonographic Evaluation of Preterm Neonates Presenting with Seizures and Its Association with Intracranial Abnormalities. *J Coll Physicians Surg Pak* 2023; **33(09)**:1073-1075.

The number of preterm births is gradually increasing, accounting for more than 10% of all live births worldwide. Pretermers are more vulnerable to ischemic and hemorrhagic brain injuries as they suffer from limited cerebral autoregulation due to vascular, cellular, and anatomical features of the developing brain and physiological instability. Preterm neonates have a higher morbidity rate than full-term neonates in the early neonatal period.<sup>1</sup> Although advances in the medical field have decreased the mortality of infants born preterm, the survivors remain at increased risk of a wide range of neurodevelopmental disabilities, including mental retardation, cerebral palsy, hearing, and visual and cognitive impairments. Seizures are one of the most critical risk factors for adverse outcomes in preterm neonates. The prevalence of seizures in full-term neonates is 0.5%, while it is 22.2% in preterm neonates.<sup>2</sup>

Neurological abnormalities in premature infants are often presented during the neonatal period. These diseases can cause long-term neurodevelopmental and cognitive impairment if not diagnosed timely.

This study aimed to determine the association of intracranial abnormalities through transcranial ultrasound in preterm neonates having seizures and to analyse these pathologies with respect to preterm classes. This study will help us to determine the importance of early screening and diagnosis of intracranial abnormalities in pretermers with seizures with the help of cranial ultrasound (CUS), which ultimately allow early interventions and prevents long-term future disabilities.

Preterm neonates with confirmed seizure occurrence were included in this cross-sectional analytical study from March to November 2021 in the Radiology Department of Shalamar Hospital, Lahore. The sample size was calculated at 95% level of significance and 8% margin of error while taking the prevalence of seizures in pretermers as 22.2%. The following formula was used to calculate the sample size.

$$n = \frac{Z_{1-\alpha/2}^2 P(1-P)}{d^2}$$

$$n = \frac{(1.96)^2 \times 0.22(1-0.22)}{(0.08)^2}$$

$$n = 103$$

Pretermers with confirmed history of seizures within the first week of postnatal life were included in the study, while pretermers with no history of seizures were excluded from the study.

These pretermers were classified into classes I, II, and III, corresponding to 26 to 28 weeks, 28 to 32 weeks, and 32 to 37 weeks, respectively. All pretermers falling in inclusion criteria were

*Correspondence to: Zobia Saleem, Department of Radiology and Medical Imaging, The University of Lahore, Lahore, Pakistan*  
*E-mail: zobiasaleem95@gmail.com*

*Received: September 28, 2022; Revised: January 23, 2023;*  
*Accepted: May 11, 2023*  
*DOI: <https://doi.org/10.29271/jcpsp.2023.09.1073>*

included through a consecutive sampling technique. These patients were then assessed by transcranial sonography during the 1<sup>st</sup> week of their postnatal life, and the results were compared with overall preterm neonates and preterm classes separately. Transcranial ultrasound was performed by an experienced radiologist who had prior experience spanning 4.5 years. Ultrasound was done with the help of a multi-frequency (5-10 MHz) convex sector transducer for optimal resolution and better results. Toshiba Aplio 500 Platinum was used for scanning. Using the anterior fontanelle approach, images were obtained in coronal and sagittal planes. The Statistical Package for the Social Sciences (SPSS) version 21 was used for data entry and analysis. The categorical variables were represented by frequency and percentage. Chi-square test was applied, and the p-value  $\alpha \leq 0.05$  was taken as the significance level.

The grading system was adopted to categorize the extent of intracranial bleeding as grade 1 (limited to caudothalamic groove), grade 2 (less than 50% volume of the normal-sized ventricle), grade 3 (extends into dilated ventricles), and grade 4 (parenchymal haemorrhage secondary to venous infarction caused by compression of deep terminal veins by an expanded ventricle filled with blood).<sup>3</sup>

A total of 103 pretermers; 63 males (61.2%) and 40 females (38.8%) with a history of seizures were included. Cranial ultrasound revealed the presence of intracranial diseases, the most prevalent of which were ventriculomegaly (18.4%) and intracranial haemorrhage (17.5%). Out of 17.5% intraventricular patients, 6.8%, 5.8%, 3.0%, and 1.9% represented grade I, II, III, and IV, respectively. Other abnormalities observed included increased periventricular echogenicity (PVE, 7.8%), echogenic sulci (5.8%), cerebral oedema (2.9%), and congenital abnormalities (2.9%). Choroidal cyst and corpus callosum agenesis were the least common abnormalities, with a 1.9% and 1.0% frequency, respectively.

Table I shows the relationship of normal and abnormal findings with ICH and VM in all preterm classes. ICH had a significant association in classes I, II, and III with p-values of 0.016, 0.001, and <0.001, respectively. Ventriculomegaly was significantly associated with classes II and III ( $p=0.003$  and <0.001, respectively).

Abnormal CUS displayed a variety of intracranial abnormalities; the most prevalent were ventriculomegaly and ICH. This study had the benefit of assessing ventriculomegaly related to all ventricles separately. Isolated dilatation of the 3<sup>rd</sup> ventricle was associated with other midline abnormalities such as CC agenesis. The study found that the most common was the combined dilatation of the lateral and third ventricles. ICH was also detected according to its location. The left-sided ICH was more common compared to the right-sided ICH and bilateral ICH.

Another finding associated with seizures was increased PVE, also termed white matter abnormality in the previous litera-

ture. Periventricular echogenicity was seen as diffuse echogenic areas of white matter in the periventricular area. The rest of the findings were cerebral oedema, congenital anomalies (Arnold Chiari malformation, Down's syndrome, and Dandy-Walker malformation), choroidal cyst, and corpus callosum agenesis, which are also supported by the other studies. Meningitis, mainly represented by echogenic sulci on ultrasound, was seen in many preterm neonates having seizures.

The present study compared the classes of preterms with all intracranial pathologies, which were isolated or overlapped findings, which gives the information about pathologies in different classes. Diseases were most widespread in class III, corresponding to gestational age 32 to 37 weeks. Overlapping findings can also be seen in the study of Dörner *et al.* Her study concludes that different kinds of brain injuries are often confused with each other, and neuroimaging prediction models often group intracranial abnormalities together based on how bad they are, not their specific pathology. This makes it hard to figure out the neurodevelopmental risk for both preterms with single injuries and those with multiple injuries simultaneously.<sup>4</sup> According to this study, ICH and ventriculomegaly were often seen as overlapping findings, shown in class III (Figure 1). ICH and increased PVE, which later leads to PVL, was also a common comorbidity present in preterm class II and III.

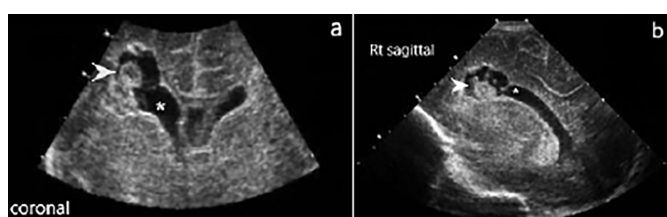
In this study, ICH and ventriculomegaly were the most common seizure aetiologies. The present study showed a significant association of intracranial haemorrhage with all preterm classes and increased with decreasing gestational age. Shahid *et al.* also discussed the same trend.<sup>5</sup> Ballabh *et al.* explained that the germinal matrix has the most blood vessels and the most densely packed ones before 37 weeks of gestational age. The round shape of the cross-sectional blood vessels shows that the germinal matrix vasculature is still developing. This dense vascularity and inherent fragility of the germinal matrix make it more likely for the premature babies to bleed. The present study also showed the significant relation of ventriculomegaly with preterm class II and III. No proper literature was found describing the association of ventriculomegaly with preterm categories. Unlike the aetiology of intracranial haemorrhage and periventricular leukomalacia, two ultrasonographic abnormalities in preterm newborns that have been investigated extensively, the pathogenesis of ventriculomegaly is still not well-established.<sup>6</sup>

Intracranial haemorrhage and ventriculomegaly were significant pathologies of seizures detected through transcranial ultrasound in preterm neonates. In such individuals, ventriculomegaly was also found to be an overlapping pathology with other intracranial pathologies like ICH and cerebral oedema. Intracranial haemorrhage was the probable seizure aetiology in all preterm classes despite gestational age. However, ventriculomegaly (isolated and overlapping) was identified as a significant cause of seizures in preterm classes II and III but not in class I.

**Table I: Relationship of normal versus abnormal CUS with ICH and VM in preterm classes.**

CUS in preterm classes	Intracranial haemorrhage			p-value*	Ventriculomegaly			p-value*
	Absent/ Other findings	Present	Total		Absent/ Other findings	Present	Total	
Class I (24-28 weeks)								
Normal	7 (70%)	0	7 (70%)	0.016	7 (70%)	0	7 (70%)	---
Abnormal	1 (10%)	2 (20%)	3 (30%)		3 (30%)	0	3 (30%)	
Total	8 (80%)	2 (20%)	10 (100%)		10 (100%)	0	10 (100%)	
Class II (28-32 weeks)								
Normal	21 (60%)	0	21 (60%)	0.001	21 (60%)	0	21 (60%)	0.003
Abnormal	08 (22%)	6 (17%)	14 (40%)		9 (25%)	5 (14%)	14 (40%)	
Total	29 (82%)	6 (17%)	35 (100%)		30 (85%)	5 (14%)	35 (100%)	
Class III (32-37 weeks)								
Normal	33 (56%)	0	33 (56%)	<0.001	33 (56%)	0	33 (56%)	<0.001
Abnormal	15 (25%)	10 (17%)	25 (43%)		11 (18%)	14 (24%)	25 (43%)	
Total	48 (82%)	10 (17%)	58 (100%)		44 (75%)	14 (24%)	58 (100%)	

CUS: Cranial Ultrasound, ICH: Intracranial haemorrhage. \*Chi-square test was applied for p-value calculation. p-value <0.05 was considered as statistically significant.



**Figure 1: ICH and ventriculomegaly in 3 days old preterm neonate (a) Coronal view (b) Right sagittal view depicting intracranial haemorrhage (arrow-head) and ventriculomegaly (asterisk).**

The limitation of this study is that it comprises of only six months of the data collection period, which is why the number of some pathologies was less than expected. An extensive study with a larger sample size should be conducted, as it will yield better results. CUS may not be able to detect all infection-related lesions causing seizures, including encephalitis and micro-abscesses.

#### COMPETING INTEREST:

The authors declared no competing interest.

#### ETHICAL APPROVAL:

The Ethical Committee of the institution provided approval for this study.

#### PATIENTS' CONSENT:

Informed consent was obtained.

#### AUTHORS' CONTRIBUTION:

ZS: Conception of study, article writing, and critical analysis.  
RB: Data entry, SPSS statistics, result, content typing, and formatting.  
SH: Study design, methodology, and critical analysis of the article.

All authors have approved final version of the manuscript to be published.

## REFERENCES

1. Lalzad A, Wong FY, Singh N, Coombs P, Brockley C, Brennan S, et al. Surveillance practice for sonographic detection of intracranial abnormalities in premature neonates: A snapshot of current neonatal cranial ultrasound practice in Australia. *Ultrasound Med Biol* 2020; **46(9)**:2303-10. doi: 10.1016/j.ultrasmedbio.2020.06.002.
2. Pisani F, Spagnoli C, Falsaperla R, Nagarajan L, Raman-tani G. Seizures in the neonate: A review of etiologies and outcomes. *Seizure* 2021; **85**:48-56. doi: 10.1016/j.seizure.2020.12.023.
3. Weerakkody Y, Rasuli B. Germinal matrix haemorrhage (grading). Reference article, Radiopaedia.org (Accessed on 14 November 2022). <https://doi.org/10.53347/rID-7600>.
4. Dorner RA, Burton VJ, Allen MC, Robinson S, Soares BP. Preterm neuroimaging and neurodevelopmental outcome: A focus on intraventricular haemorrhage, post-hemorrhagic hydrocephalus, and associated brain injury. *J Perinatol* 2018; **38(11)**:1431-43. doi: 10.1038/s41372-018-0209-5.
5. Shahid G. Risk factors of subependymal haemorrhage-in-traventricular haemorrhage in preterm infants. *J Rawalpindi Med Coll* 2017; **21**:23-8.
6. Patel SK, Zamorano-Fernandez J, Nagaraj U, Bierbrauer KS, Mangano FT. Not all ventriculomegaly is created equal: Diagnostic overview of fetal, neonatal and pediatric ventriculomegaly. *Childs Nerv Syst* 2020; **36(8)**: 1681-96. doi: 10.1007/s00381-019-04384-w.

.....