

Comparison of the Locking Intramedullary Nailing, Single Plate and Double Plate Osteosynthesis in Treatment of Humerus Shaft Fractures

Haci Bayram Tosun¹, Sancar Serbest², Mehmet Mete Yasar³, Abuzer Uludag³ and Galip Ersoz¹

¹Department of Orthopaedics and Traumatology, Elazig Fethi Sekin Training and Research Hospital, Elazig, Turkey

²Department of Orthopaedics and Traumatology, Faculty of Medicine, Kirikkale University, Kirikkale, Turkey

³Department of Orthopaedics and Traumatology, Faculty of Medicine, Adiyaman University, Adiyaman, Turkey

ABSTRACT

Objective: To compare the clinical and radiographic outcomes between patients treated with single plate osteosynthesis, double plate osteosynthesis, and antegrade locked intramedullary nailing (IMN) in treatment of humerus diaphyseal fractures.

Study Design: Descriptive study.

Place and Duration of the Study: Department of Orthopaedics and Traumatology, Adiyaman University Training and Research Hospital, Adiyaman, Turkey, between 2014 and 2020.

Methodology: A total of 99 patients with humerus diaphyseal fractures were retrospectively evaluated. Forty-six had been treated with single plating, 24 were treated with double plating, and 29 with IMN. The outcomes were evaluated in terms of the union time, union rate, complications, and Disabilities of the Arm, Shoulder, and Hand (DASH) functional scores.

Results: The average union time was 17 weeks and nonunion rate was 6% of patients. There was no significant difference between the groups in terms of DASH functional score and nonunion ($p > 0.05$). The surgical time and bleeding amount were significantly shorter in the IMN group compared to the other groups ($p < 0.05$). A statistically significantly short union time was observed in both plating groups compared to IMN ($p < 0.05$), but it was not different between single and dual plating ($p > 0.05$).

Conclusion: Regardless of the implant used, good reduction and stable fixation, respect for the soft tissue and use of the implant in accordance with the surgical technique are sufficient to achieve union in the surgical treatment of humeral shaft fractures.

Key Words: Humeral shaft fracture, Surgical treatment options, Comparison, Outcomes.

How to cite this article: Tosun HB, Serbest S, Yasar MM, Uludag A, Ersoz G. Comparison of the Locking Intramedullary Nailing, Single Plate and Double Plate Osteosynthesis in Treatment of Humerus Shaft Fractures. *J Coll Physicians Surg Pak* 2023; **33(11)**:1315-1320.

INTRODUCTION

Humeral shaft fractures account for approximately 3% of all fractures, and 20% of humeral fractures are found in adults.¹⁻³ These fractures are often treated conservatively. After the functional bracing became popular in the treatment of these fractures in the 1970s, it was accepted as the standard treatment.²⁻⁶ But high rates of nonunion have been reported with conservative treatment in the recent years.⁷ There is an obvious trend towards surgical stabilisation² and surgical fixation is becoming more popular due to a more demanding society in the high-income countries.⁶

The plate osteosynthesis and locking intramedullary nailing are frequently used in surgical treatments. Although these treatments have their own advantages and disadvantages, the rates of union vary according to the method used.^{3,4,8} Recently, double plating for treatment of humerus shaft nonunion has been recognised as an alternative fixation method, and this method allows early and aggressive movement due to its strong stability.⁹

Although many clinical studies and meta-analyses have guided the surgeons for the treatment of these fractures, there is still no consensus as to what the most suitable treatment is as many factors need to be considered before making a choice of treatment.¹

This study aimed to compare the functional outcomes and union rates after the fixation of humerus by use of intramedullary nailing, single plating, and double plating in the treatment of humerus shaft fractures.

METHODOLOGY

Of all 99 patients, records were evaluated retrospectively out of the cohort which underwent surgical treatment at Adiyaman

Correspondence to: Dr. Haci Bayram Tosun, Department of Orthopaedics and Traumatology, Elazig Fethi Sekin Training and Research Hospital, Elazig, Turkey
E-mail: bayramtosun@hotmail.com

Received: December 22, 2022; Revised: May 22, 2023;

Accepted: August 25, 2023

DOI: <https://doi.org/10.29271/jcpsp.2023.11.1315>

University Training and Research Hospital, Adiyaman, Turkey, for humerus shaft fractures between 2014 and 2020. Forty-six patients had been treated with single plating (Figure 1), 24 patients were treated with double plating (Figure 2), and 29 patients were treated with intramedullary locking nailing (IMN) (Figure 3), sequentially and randomly. All imaging and medical records were extracted from electronic patient records (Picture Archiving and Communication System—PACS software) at the hospital. An approval for the study was given by the Adiyaman University Hospital Ethics Committee (2018/8-19). All patients were informed about the treatment and their written consents were obtained. All patients underwent standard radiological evaluation including lateral and anteroposterior (AP) views at presentation and follow-ups. All fractures were graded according to the AO/OTA classification,⁹ and Gustilo classification for open fractures.¹⁰

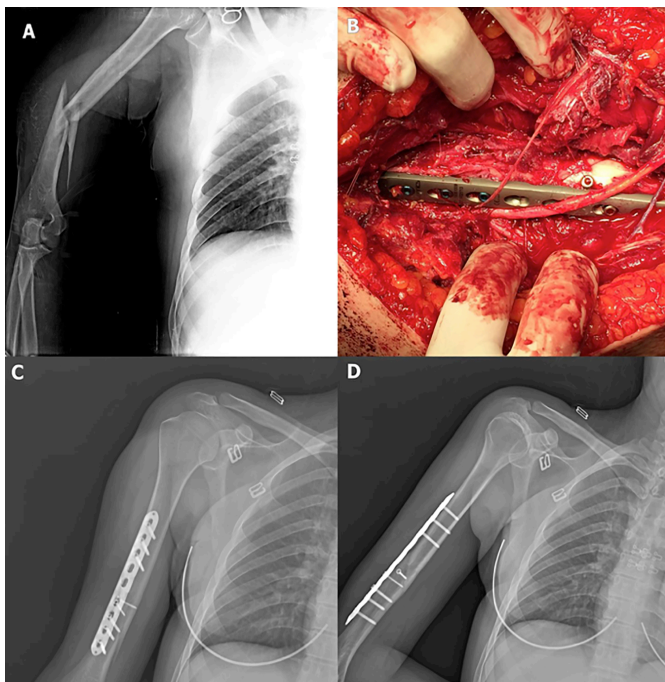


Figure 1: (A) X-ray shows the right humeral shaft fracture, 12-C1 according to AO/OTA classification, (B) Intraoperative appearance of open reduction and single plate osteosynthesis, (C) and (D) Anteroposterior and lateral radiographs show the bone union 3 months after surgical management.

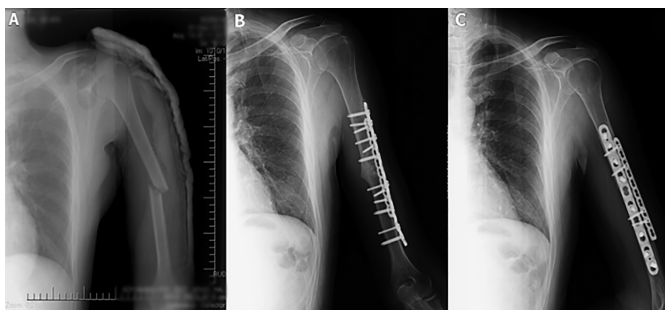


Figure 2: (A) X-ray shows the left humeral shaft fracture, 12-A2 according to AO/OTA classification, (B) and (C) Anteroposterior and lateral radiographs show the bone union 3 months after surgical management with double plate osteosynthesis.

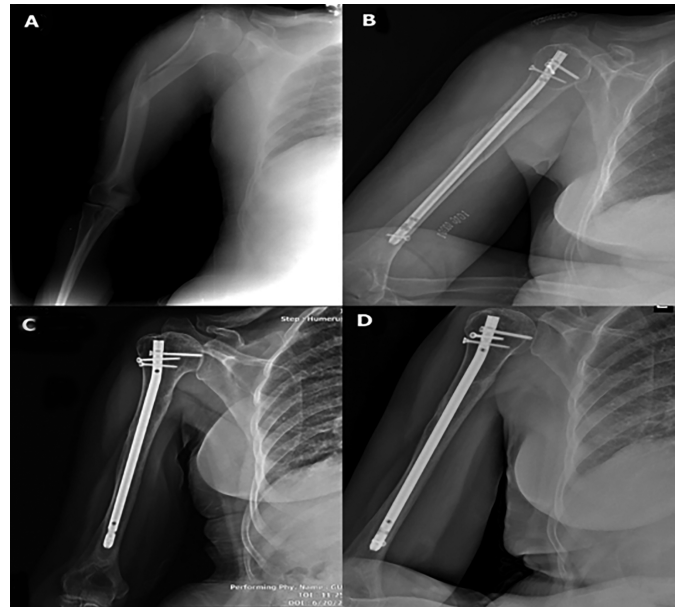


Figure 3: (A) X-ray shows the right humeral shaft fracture, 12-C1 according to AO/OTA classification, (B) Postoperative radiography after surgical management with locked intramedullary nail, (C) and (D) Anteroposterior and lateral radiographs show the bone union 5 months after surgical management.

All the fractures were located between 3 cm distal to surgical neck or 4 cm proximal to the olecranon fossa. Humeral shaft fractures were treated operatively in case of >20° angulation anteriorly, >15-30° varus/valgus deformation, >3 cm shorting, >20° rotation, failure or poor alignment after casting, accompanying vascular injury (nerve palsy was not a definitive indication), open fractures, polytrauma and patients' choice.^{11,12} The patients with pathological fractures, follow-up of shorter than 3 months, patients treated with minimally invasive percutaneous osteosynthesis, and old neglected fractures and refractures were excluded from the study. All surgical options were performed in the beach-chair position by the same surgeon after general anaesthesia. All patients had been given antibiotic prophylaxis with cefazolin for 24 hours and discharged after 48 hours from the surgery. Bone graft was not used in any patients. All patients were put on arm sling after surgery.

On the first day after surgery, passive and active assisted range of motion exercises of the elbow and shoulder were begun, continued as strengthening exercises after radiographic union appeared.

All patients had been evaluated in follow-up at 6 weeks and at 3, 6, 12 months. The outcomes were evaluated in terms of the union time, union rate, complications before surgery (radial nerve palsy, vascular injury), operative time from skin incision to skin closure, complications (surgical site infections, nonunion, iatrogenic radial nerve palsy) and functional outcome. Functional outcome was assessed by using the DASH score.⁷

Fracture union was considered as absence of pain at the fracture site and the presence of callus in three cortices on views in the AP and lateral radiographic. Nonunion was defined as the absence of healing as clinical and radiographic up to six and/or nine months.¹²

Table I: Baseline characteristics and demographic data.

		Total (n=99)	Single plating (n=46)	Double plating (n=24)	IMN (n=29)
Age (year)	(mean±SD)	42.9±1.9	40.7 ±3	42.9±3.8	46.7±3.4
Gender (M/F)	(n)	68/31	37/11	15/9	16/11
Extremity side (right/left)	(n)	59/40	30/16	14/10	15/14
Follow-up (weeks)	(mean±SD)	16.5±0.7	15.4±1	17.8±1.6	17.2±1.6
Radial nerve palsy before surgery	(n)	5	4	1	-

Table II: Type of fractures according to AO Foundation/Orthopaedic Trauma Association.

Type	Total (n=99)	Single plating (n=46)	Double plating (n=24)	IMN (n=29)
A	58	31	13	14
B	28	14	6	8
C	13	1	5	7

Table III: Comparison of the results of the treatment methods.

Variable	Total (n=99)	Single plating (n=46)	Double plating (n=24)	IMN (n=29)	p-values	
Surgical time (min)	65.86	67.20	71.25	58.70	0.421	
Bleeding amount (ml)	163.78	190.62	202.5	81.66	0.806	0.019^a
Union time (weeks)	17.05	16.35	14.75	20.33	0.630	<0.001^a
Nonunion n (%)	6(6.06)	2(2.02)	1(1.01)	3(3.03)	>0.05	0.015^b
Infection n (%)	3 (3.03)	1 (1.01)	2 (2.02)	-	>0.05	
Iatrogenic radial palsy n (%)	2 (2.02)	2 (2.02)	-	-	>0.05	
Shoulder pain n (%)	4 (4.04)	-	-	4 (4.04)	>0.05	
DASH score	17.37	16.07	18.5	18.66	0.776	0.734

^a p <0.05 between single plating vs IMN, ^b p <0.05 between double plating vs IMN. Bold values indicate statistical significance in One-Way ANOVA test.

The anterolateral or lateral approach was preferred depending on the fracture pattern and soft tissue conditions, and then the radial nerve was dissected and retracted. The commonly used implant was a 4.5 mm DCP (dynamic compression plate) plate with the length depending upon the type of fracture after open reduction. Plate-screw fixation was done, with six to eight cortices involved, both proximal and distal to the fracture.

Double plating was done through the same approach. In the double plating procedure, one of the plates was 4.5 mm broad DCP or 3.5 mm anatomical plate, and the other plate was a 3.5 mm narrow DCP plate. The 3.5 mm narrow DCP plate was always preferred as a secondary support plate. Four screws were bi-cortical placed to be at two proximal and two distal to the fracture part. No screws were sent into the screw holes adjacent to the fracture line. The fixation of plates was performed to be angled at 90° to the posterior and lateral surfaces of the humerus.¹¹

Intramedullary locking nailing was performed following closed reduction. A freehand technique was used for distal locking (Sanatmetal, Humerus nail, Hungary), and intramedullary reaming was done in all cases.

All statistical analyses were performed with SPSS version 16.0 (SPSS Inc., Chicago, IL). A confidence interval (CI) of 95% and a 2-tailed p <0.05 were determined to be statistically significant for all the analyses. One-way ANOVA with Tukey-Kramer test was used for the comparison among each surgical technique. A p-value <0.05 was statistically significant.

RESULTS

This study included 99 patients with a mean age of 42.9±1.9 years. The mean period of follow-up was 16.5±0.7 (8-48) months. The demographic characteristics of the groups are given in Table I. All patients were categorised according to AO-OTA classification (Table II).

Nonunion rate was 6.06% in all the patients. Nonunion occurred in two (2.02%) of the single plating, one (1.01%) of the double plating and three (3.03%) of the IMN. A patient with concomitant contralateral femoral neck and shaft fracture was observed nonunion in double plating group in the latest follow-up. One of the plates in this patient was broken due to the overload after the use of crutches in the early period. Even though there was absence of union, this patient did not accept surgery because of no serious instability. One patient was seen with nonunion and breakage of plate in the single plating group. This patient was treated with double plating and eventually had complete healing. Another patient who was a substance abuser had a humerus shaft fracture and the clavicle fracture. Plate osteosynthesis was done for both fractures. After nonunion and implant failure, the IMN was performed, and union of fractures was achieved in both fractures.

Three patients who underwent nailing had nonunion. A patient with Gustilo Type 1 open fracture had nonunion due to distraction at fracture, and it was refixed using osteosynthesis with double plate after removal of the nail, and a union of fracture was achieved. In another patient with a segmental humerus fracture, although the union at proximal part of fracture was observed, union at distal part of fracture

was not observed. After removal of nail, it was fixed with a single plate and complete union was achieved. Furthermore, a morbidly obese patient with complex fracture developed nonunion after closed reduction and IMN. The cause of the nonunion was inadequate reduction in another patient, and fracture union was achieved after single plating.

Five (5.05%) patients had a radial nerve injury due to trauma before surgery, and plate osteosynthesis had been done for all these patients. Two (2.02%) patients in the plating group had an iatrogenic radial nerve injury. Radial nerve palsy was observed in seven patients who recovered completely during the follow-ups. Radial or axillary nerve injury was not observed in any of the patients who underwent nailing.

Open fractures were seen in one patient in IMN and double plating (Gustilo Grade 1 or 2a). None of these had developed deep infection after debridement and early fixation. Three patients treated with plating developed superficial infection which recovered completely with antibiotic treatment. Four (4.04%) patients in IMN group reported shoulder pain and limitation of movement related to the prominent nail end. There was no significant difference between the groups ($p > 0.05$).

There was no significant difference between the groups in terms of DASH functional score ($p > 0.05$). It was observed that the surgical time and bleeding amount were significantly shorter in the IMN group compared to the other groups ($p < 0.05$). A statistically significant short union time was observed in both plating groups compared to IMN ($p < 0.05$), but it was not different between single and dual plating ($p > 0.05$, Table III).

DISCUSSION

In this study, there was no statistical difference in terms of bone union and functional results among the groups. Although the surgical time and bleeding amount were significantly shorter in the IMN group, the union time of fractures was shorter in both plating groups.

Non-complicated humerus shaft fractures are mostly treated conservatively and union rates are over 90%.¹³ Surgical options should be considered if conservative treatment is unsuccessful.^{4,13} Moreover, the indications for surgical treatment are polytraumatic injuries, open fractures, vascular injury, segmental fractures, pathological fractures, bilateral humerus fractures, ipsilateral articular or floating elbow fractures, neurological loss after penetrating injuries, radial nerve palsy after fracture manipulation.³ Surgical treatment is often preferred to achieve optimal reduction and stable alignment.¹⁻³ Schoch *et al.* stated that surgical treatment has been increasing with time in the United States.¹⁴ Although they have reported satisfactory results with conservative treatment, the reason for this increase is unknown. The

possible reasons for rise in the surgical treatment include a perceived quicker return to work, early joint rehabilitation, younger age, open fracture, private insurance, and avoidance of wearing a brace for a long time.¹⁴ In this study, avoidance of brace use for a long time, early return to work, early rehabilitation, and demand to use their extremity as soon as possible in their daily life increased the tendency from conservative treatment to adopt operative treatment.

Plate fixation has become the preferred method since the last decades.^{4,6-8} However, the recent advances in technology and market growth have popularised the use of IMN. The plate osteosynthesis has disadvantages such as excessive stripping of soft tissues from the bone, injury of radial nerve, and especially fixation failure in osteoporotic bones.¹⁵ Also, IM nailing is a minimally invasive surgery that has advantages such as load-sharing device and less stress shielding, low possibility of refracture after implant removal and internal grafting due to reaming.⁸ This study has shown that there is no difference between rigid plate fixation and IMN fixation in terms of fracture union, provided that the surgical technique are followed.

The most important reasons of the shoulder problems after IMN are tear of rotator cuff, damage of chondral, and prominent nail end.^{7,8,16} In this study, the shoulder pain and limitation of movement were observed in 4.04% of patients in IMN group. The most important cause of shoulder pain is related to the prominent nail end rather than cartilage damage or split separation of the rotator cuff, so it is necessary to pay attention to this aspect.

Dual plating is well-defined for distal humeral fractures of the upper extremity. The indication for the use of double plating has been increased over the last few years. While double plating is frequently used in treatment of nonunion, it has also started to be used in primary fixation of various complicated fractures at the present time. Double plating is advantageous in regions subject to high bending and torsional stresses because of its strong biomechanical stability.¹⁷ Prasarn *et al.* reported that dual plating allows aggressive range of motion by making rigid construct.¹¹ Tecimel *et al.* reported that although there was no significant difference between single and double plate,¹⁸ superior clinical results were obtained in the functions of shoulder and elbow in double plating. The authors think that open reduction and double plating give confidence to the surgeon, but it was observed that there was no difference between single and double plating. Also, the increased cost of double plating should be considered.

Changulani *et al.* reported higher arm shortening (1.5–4 cm) and restriction of shoulder motion in IMN group compared to plate osteosynthesis.⁸ In a meta-analysis, Kurup *et al.* reported that there was no significant difference between plating and IMN.¹⁹ But there was a significant increase in impingement and restriction of shoulder movement following nailing. Wang *et al.* reported that despite no significant difference was seen between the plating and nailing, more re-oper-

ations were being done using to bone graft in plating groups.²⁰ In this study, the nonunion rate was 6.06% and nonunion occurred in two (2.02%) of the single plating, one (1.01%) of the double plating, and three (3.03%) of the IMN. Regardless of the surgical fixation method, the excessive stripping of soft tissue from the bone, open and complex fractures, inadequate reduction and non-compliance of patient are important causes of nonunion. The authors think that the nonunion rate will be observed very low when good reduction and stable fixation are performed, no matter which surgical method is used.

Wang *et al.* reported that IMN fixation significantly decreased intraoperative blood loss, operative time, hospital stay, union time and complication rate compared to plating.²⁰ In this study, the surgical time and bleeding amount were significantly shorter in the IMN group, but the union time of fractures was shorter in both plating groups. There was no statistically significant difference in terms of union of fracture and functional scores between the groups. It can be said that patient's satisfaction was higher in the double plating group because rigid stability allows early movement and early return to work.

Van de Wall *et al.* reported that only 2.6% of the patients developed iatrogenic radial nerve palsy, and complete recovery was seen in 61.5% of patients initially presenting with radial nerve palsy, partial in 34.6%, and no recovery in 3%.¹² In the present study, radial nerve palsy was observed in 7.07% of the patients who underwent plate because of trauma and iatrogenic complications. All recovered completely during the follow-ups. Nerve injury was not observed in IMN group.

The limitations of this study are a small number of patients, its retrospective design, the use of different surgical options not standardised according to the type and location of the fracture.

CONCLUSION

Regardless of the implant used, good reduction and stable fixation, respect for the soft tissue and use of the implant in accordance with the surgical technique are sufficient to achieve union in the treatment of humeral shaft fractures. Although double plating after open reduction may be preferred in the treatment of humeral shaft fractures because of its early motion and strong fixation, the increased cost of the treatment should be considered.

ETHICAL APPROVAL:

The study protocol was approved by the Adiyaman University Hospital Ethics Committee (2018/8-19).

PATIENTS' CONSENT:

All patients were informed about the treatment and their written consents were obtained before commencing this study.

COMPETING INTEREST:

The authors declared no competing interest.

AUTHORS' CONTRIBUTION:

HBT: Study design, planning, data collection, manuscript writing, and critical revision.

SS: Data collection and statistical analysis.

MMY: Data collection and analysis, manuscript writing.

AU: Data analysis and critical revision.

GE: Literature review and manuscript writing.

All authors approved the final version of the manuscript to be published.

REFERENCES

1. Bisaccia M, Meccariello L, Rinonapoli G, Rollo G, Pellegrino M, Schiavone A, *et al.* Comparison of plate, nail and external fixation in the management of diaphyseal fractures of the humerus. *Med Arch* 2017; **71(2)**:97-102. doi:10.5455/med-arh.2017.71.97-102.
2. Zhao JG, Wang J, Meng XH, Zeng XT, Kan SL. Surgical interventions to treat humerus shaft fractures: A network meta-analysis of randomized controlled trials. *PLoS One* 2017; **12(3)**:e0173634. doi:10.1371/journal.pone.0173634.
3. Carroll EA, Schweppe M, Langfitt M, Miller AN, Halvorson JJ. Management of humeral shaft fractures. *J Am Acad Orthop Surg* 2012; **20(7)**:423-33. doi: 10.5435/JAAOS-20-07-423.
4. Tetsworth K, Hohmann E, Glatt V. Minimally invasive plate osteosynthesis of humeral shaft fractures: Current state of the art. *J Am Acad Orthop Surg* 2018; **26(18)**:652-61. doi: 10.5435/JAAOS-D-17-00238.
5. Campochiaro G, Baudi P, Gialdini M, Corradini A, Duca V, Rebuzzi M, *et al.* Humeral shaft non-union after intramedullary nailing. *Musculoskelet Surg* 2017; **101(2)**:189-93. doi: 10.1007/s12306-017-0468-x.
6. Gottschalk MB, Carpenter W, Hiza E, Reisman W, Roberson J. Humeral shaft fracture fixation: Incidence rates and complications as reported by American Board of Orthopaedic Surgery Part II candidates. *J Bone Joint Surg Am* 2016; **98(17)**:e71. doi: 10.2106/JBJS.15.01049.
7. Akalin Y, Şahin İG, Çevik N, Güler BO, Avci Ö, Öztürk A. Locking compression plate fixation versus intramedullary nailing of humeral shaft fractures: Which one is better? A single-centre prospective randomised study. *Int Orthop* 2020; **44(10)**:2113-21. doi: 10.1007/s00264-020-04696-6.
8. Changulani M, Jain UK, Keswani T. Comparison of the use of the humerus intramedullary nail and dynamic compression plate for the management of diaphyseal fractures of the humerus. A randomised controlled study. *Int Orthop* 2007; **31(3)**:391-5. doi: 10.1007/s00264-006-0200-1.
9. Meinberg EG, Agel J, Roberts CS, Karam MD, Kellam JF. Fracture and dislocation classification compendium- 2018. *J Orthop Trauma* 2018; **32(1)**:1-170. doi: 10.1097/BOT.0000000000001063.
10. Gustilo RB, Mendoza RM, Williams DN. Problems in the management of Type III (severe) open fractures: A new classification of Type III open fractures. *J Trauma* 1984; **24(8)**:742-6. doi:10.1097/00005373-198408000-00009.

11. Prasarn ML, Ahn J, Paul O, Morris EM, Kalandiak SP, Helfet DL, Lorich DG. Dual plating for fractures of the distal third of the humeral shaft. *J Orthop Trauma* 2011; **25(1)**:57-63. doi: 10.1097/BOT.0b013e3181df96a7.
12. Van de Wall BJM, Ganzert C, Theus C, van Leeuwen RJH, Link BC, Babst R, et al. Results of plate fixation for humerus fractures in a large single-center cohort. *Arch Orthop Trauma Surg* 2020; **140(10)**:1311-18. doi: 10.1007/s00402-019-03319-z.
13. Arealis G, Faria G, Kucera M, Crisan C, Murthy S. Treatment of midshaft humerus fractures using early functional bracing: Results and prognostic factors. *Cureus* 2021; **13(5)**:e14852. doi: 10.7759/cureus.14852.
14. Schoch BS, Padegimas EM, Maltenfort M, Krieg J, Namdari S. Humeral shaft fractures: National trends in management. *J Orthop Traumatol* 2017; **18(3)**:259-63. doi: 10.1007/s10195-017-0459-6.
15. Habernek H, Orthner E. A locking nail for fractures of the humerus. *J Bone Joint Surg Br* 1991; **73(4)**:651-3. doi: 10.1302/0301-620X.73B4.2071653.
16. Feng D, Wang X, Sun L, Cai X, Zhang K, Wang Z, et al. Double plating with autogenous bone grafting as a salvage procedure for recalcitrant humeral shaft nonunion. *BMC Musculoskelet Disord* 2020; **21(1)**:769. doi: 10.1186/s12891-020-03743-y.
17. Katthagen JC, Schliemann B, Michel PA, Heilmann LF, Dyrna F, Raschke MJ. Clinical application and outcomes of upper extremity double plating. *Z Orthop Unfall* 2020; **158(2)**:227-37. doi: 10.1055/a-0862-1070.
18. Tecimel O, Bozkurt İ, Çepni Ş, Yaman F, Fırat A, Öçgüder DA. The comparison of single plate and double plate fixation methods for treatment of humeral shaft nonunions. *Jt Dis Relat Surg* 2021; **32(1)**:67-74. doi: 10.5606/ehc.2021.74488.
19. Kurup H, Hossain M, Andrew JG. Dynamic compression plating versus locked intramedullary nailing for humeral shaft fractures in adults. *Cochrane Database Syst Rev* 2011; **6**:CD005959. doi: 10.1002/14651858.CD005959.pub2.
20. Wang Y, Kayastha Y, Cao Y, Guo Z, Yuan Y, Bi Y. Outcome of humeral shaft fracture treated with intramedullary nail and plate fixation. *J Coll Physicians Surg Pak* 2020; **30(1)**:73-8. doi: 10.29271/jcpsp.2020.01.73.

•••••