

# A Case of Neuromyelitis Optica with Systemic Lupus Erythematosus

Waleed Shahzad<sup>1</sup>, Haris Majid Rajput<sup>1</sup>, Muhammad Hassan<sup>1</sup>, Tehmina Inayat<sup>2</sup> and Mazhar Badshah<sup>1</sup>

<sup>1</sup>Department of Neurology, Shaheed Zulfiqar Ali Bhutto Medical University, Pakistan Institute of Medical Sciences, Islamabad, Pakistan

<sup>2</sup>Department of Medicine, Shaheed Zulfiqar Ali Bhutto Medical University, Pakistan Institute of Medical Sciences, Islamabad, Pakistan

## ABSTRACT

Neuromyelitis Optica (NMO) is a rare idiopathic autoimmune demyelinating disease of the central nervous system (CNS) having a relapsing course. It consists of optic neuritis, longitudinally extensive transverse myelitis (LETM) which involves 3 or more neighbouring portions of the spine and positive serology for anti-NMO IgG antibodies. NMO is often misdiagnosed as multiple sclerosis (MS). Limited literature about NMO and its association with other systemic autoimmune diseases, such as systemic lupus erythematosus (SLE) is available so far. Here, we present a 21-year girl, previously diagnosed case of SLE seven years back, who suffered attacks of transverse myelitis. She had seropositivity for anti-aquaporin-4 (anti-AQP4) receptor antibody. An accurate clinical diagnosis is important to initiate timely immunosuppressive therapy to prevent disability.

**Key Words:** *Neuromyelitis Optica, Transverse myelitis, Systemic lupus erythematosus.*

**How to cite this article:** Shahzad W, Rajput HM, Hassan M, Inayat T, Badshah M. A Case of Neuromyelitis Optica with Systemic Lupus Erythematosus. *J Coll Physicians Surg Pak* 2022; **32(11)**:1498-1500.

## INTRODUCTION

In 1894, the term Neuromyelitis Optica (NMO) was first used by Eugene Devic; since then, it is also known as Devic's disease. It is an idiopathic autoimmune demyelinating disease of the central-nervous system (CNS) having a relapsing course. Common presentations include optic neuritis and transverse myelitis involving 3 or more neighbouring portions of the spinal cord and positive serology for the anti-aquaporin-4 (anti-AQP4) receptor antibodies.<sup>1</sup> These antibodies have high diagnostic values with high sensitivity and specificity.<sup>1</sup> Mortality rate in the past due to this disorder was roughly 33% globally,<sup>2</sup> but according to recent cohort studies, mortality has reduced probably due to increased knowledge of the condition and earlier diagnosis.<sup>2</sup> Initially, it was believed to be a variation of multiple sclerosis but new clinical, immunological, and radiological data, especially the detection of IgG antibody, has given this entity an independent identity. NMO affects both men and women with predilection for females.<sup>3</sup> The median age of onset is 20-50 years.<sup>3</sup>

NMO has been very rarely described in association with systemic lupus erythematosus (SLE). The first case in literature is of a woman with 4 years history of para-paresis, incontinence, and right-sided optic neuropathy.<sup>4</sup> NMO presents with different symptoms, often preceded by a flu-like condition. Sometimes patients also develop visual and hearing impairments, olfactory problems, cognitive decline, and paralysis with incontinence.<sup>5,6</sup> We present a case of a 21-year female, a known case of SLE, who later developed features of NMO, a very rare concurrence of diseases.

**Table I: Auto-immune profile of the patient.**

Test	Patient's Result	Normal Reference
ANA	++	Speckled appearance
Anti-ds DNA	++ 201 U/ml	≤ 4 IU/ml
Anti-Sm	++	
Anti-Ro	++	
Anti-La	Negative	
C3 levels	0.7 g/l	
C4 levels	0.05 g/l	

## CASE REPORT

A 21-year female was diagnosed with a case of SLE in 2012. Initial clinical features suggestive of SLE included joint pains with morning stiffness, photo-sensitivity, oral ulcers, alopecia, and facial malar rash. Her auto-immune profile in 2012 was consistent with SLE (Table I).

She was started on oral hydroxy-chloroquine 200 mg, oral prednisolone 5 mg on alternate days, Vitamin D supplements, and Omeprazole 40 mg. She was poorly compliant to medications.

Correspondence to: Dr. Waleed Shahzad, Department of Neurology, Shaheed Zulfiqar Ali Bhutto Medical University, Pakistan Institute of Medical Sciences, Islamabad, Pakistan

E-mail: waleed@live.com

Received: June 22, 2020; Revised: March 02, 2021;

Accepted: April 28, 2021

DOI: <https://doi.org/10.29271/jcpsp.2022.11.1498>

Now she had presented with acute onset of quadriplegia and urinary retention. There was no chest pain, shortness of breath, swallowing difficulty, gastrointestinal symptoms or redness of the eyes.

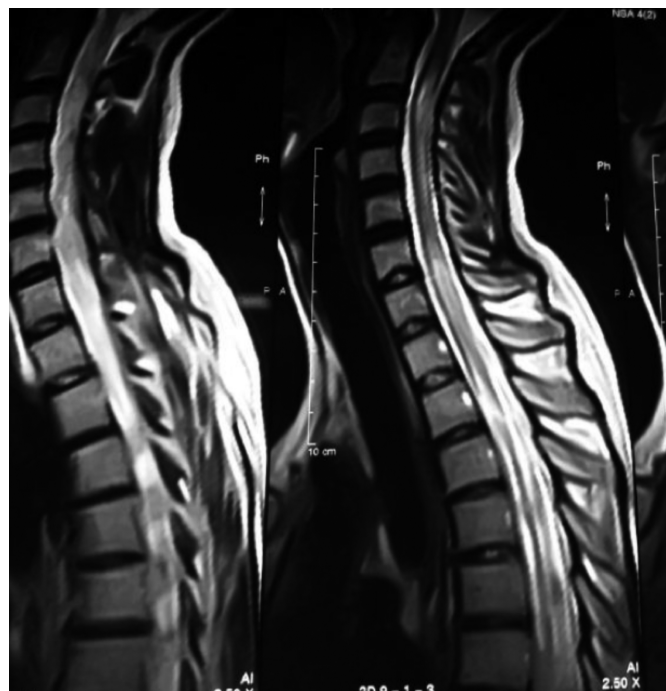On examination, she was afebrile having a heart rate of 74 beats/minute and a respiratory rate of 17 breaths/minute. Higher mental functions and cranial nerves were normal. Pupils were 3 mm in size and reactive to light. Visual acuity, perimetry, and fundoscopy showed no abnormality. She had a modified rankin scale (MRS) of 5. Power grading showed the right arm; 4/5, left arm; 3/5 and right leg; 2/5, and left leg; 1/5. Reflexes were grade 4 in the lower limbs and grade 2 in the upper limbs. The tone was normal. She had a bilateral extensor plantar response. Sensations to pinprick showed a sensory level of T4 and there was impaired joint position sense in the lower limbs. Cardiovascular, respiratory, and abdominal examination showed no abnormality.

**Table II: Blood reports.**

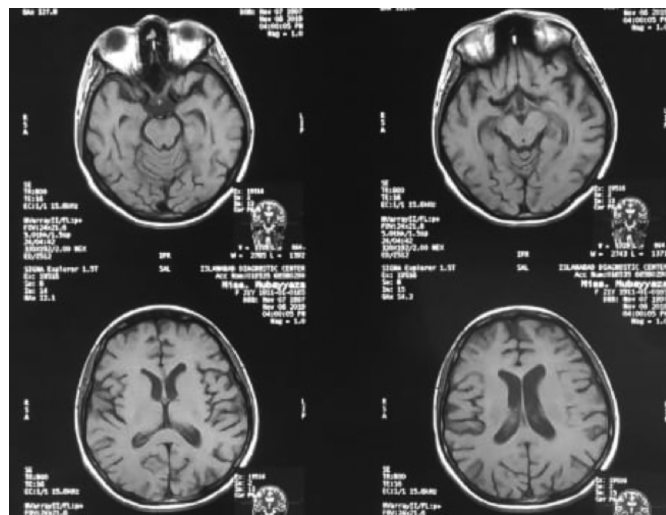
Test	Patient's result	Normal reference
Haemoglobin	12.0	12-15 g/dL
White cell count	9,590	4000-11,000 cells/ $\mu$ L
Erythrocyte sedimentation rate	16	0 to 15 mm/1 <sup>st</sup> hr
Prothrombin time	14 seconds	<14 seconds
Activated partial thromboplastin time	32 seconds	<32 seconds
Anti-aquaporin 4 antibody	Positive ++	Negative
Anti-Cardiolipin Antibodies IgG	1U/mL	<10.0 GPL-U/mL
Anti-Cardiolipin Antibodies IgM	2U/mL	<7.0 PL-U/mL
Anti-Beta2 Glycoprotein 1 IgG Antibody	1 U/mL	<10 U/mL
Anti-Beta2 Glycoprotein 1 IgM Antibody	1 U/mL	<10 U/mL
Lupus anticoagulant	39 seconds	39-53 seconds

In investigations, the blood complete picture showed microcytic hypochromic anaemia with a haemoglobin of 12.0 g/dL and platelets 195,000/ $\mu$ L. The erythrocyte sedimentation rate (ESR) was 56 mm/1<sup>st</sup> hr. Serum creatine was 1.1 mg/dl and alanine aminotransferase (ALT) was 26 mg/dl (Table II). Serum TSH was 2.1 mIU/L. Cerebro-spinal spinal fluid analysis showed raised proteins of 51.9 mg/dL with a normal cell count of 5 cells/ $\text{mm}^3$  and normal glucose of 53 mg/dL. Cervico-dorsal spine imaging showed a long segment well-defined lesion extending from C2 to T10; appearing low on T1 and high on T2 (Figure 1). MRI brain showed no gross abnormality except mild cortical atrophy (Figure 2). The Anti-AQP4 receptor antibody was strongly positive. Chest X-ray, ECG, and echocardiogram showed no pathology. Extended work-up for anti-phospholipid syndrome showed anti-cardiolipin antibody to be 1.6 U/mL and lupus anticoagulant upto 40 seconds. A diagnosis of NMO with SLE was documented. She was started on infusion of cyclophosphamide, intra-venous methyl-prednisolone pulse, 1 gm for 5 days, followed by five sessions of plasma exchange (PLEX). She showed a good response to treatment with an

improved MRS score of 3 and was discharged on oral prednisolone of 60 mg daily and azathioprine 150 mg per day.



**Figure 1: MRI cervical and dorsal spine, T2-weighted sagittal images showing cord swelling with longitudinally extensive lesion from C2 to T10.**



**Figure 2: MRI brain T1-weighted images: grossly normal except for mild cortical atrophy.**

## DISCUSSION

LETM can present as an uncommon sequela of SLE or other autoimmune diseases like acute demyelinating encephalomyelitis (ADEM), Sjogren's syndrome, myasthenia gravis, Hashimoto's thyroiditis, B12 deficiency or Behcet's disease.<sup>7</sup> NMO is a clinical diagnosis with spine radio-imaging showing extensive cord signals harbouring three-or-greater segments. Anti-AQP4 receptor antibody positivity can help in early diagnosis of NMO in patients presenting with LETM, as in this case, where early detection helped in preventing lifetime disabilities.

High dose pulse intra-venous methyl-prednisolone is used as the initial acute first-line therapy while for refractory or severe cases, therapeutic PLEX is generally used.<sup>8</sup> The use of intravenous immune-globulins (IVIG) in acute relapse is mostly limited.<sup>8</sup>

Common initial therapies include mycophenolate mofetil, azathioprine or rituximab, while a few newer agents, like tocilizumab, can be given with a combination of steroids plus methotrexate or azathioprine.<sup>8</sup> It is now believed that cyclophosphamide is not the treatment of choice and has no proven efficacy anymore.<sup>9</sup> Typical MS medications like beta-interferon, natalizumab and fingolimod should be used with caution because of their disastrous effects.<sup>10</sup> In those patients, who have highly active titers of AQP4 antibodies, a treatment-resistant NMO and show no response to steroids, rituximab or PLEX, newer treatment modalities, tocilizumab/eculizumab, can be used.<sup>8</sup> We believe that recognition of NMO as a separate entity along with the knowledge of its association with many other auto-immune diseases is important to overcome the diagnostic delays in NMO patients. NMO shows a variable, often a poor, response to treatment. Blindness can occur from optic atrophy and myelitis can lead to permanent disability. Association of NMO and SLE is rare but early recognition and early testing for NMO will enable the prevention of irreversible complications.

#### **PATIENT'S CONSENT:**

Informed consent was obtained from the patient prior publication of this case.

#### **COMPETING INTEREST:**

The authors declared no competing interest.

#### **AUTHORS' CONTRIBUTION:**

WS: Manuscript writing, manuscript editing, manuscript review, and data collection.

HMR: Manuscript editing and manuscript review.

MH, TI: Data collection and manuscript review.

MB: Data analysis and manuscript review.

All the authors have approved the final version of the manuscript to be published.

## **REFERENCES**

1. Papadopoulos MC, Verkman AS. Aquaporin 4 and neuromyelitis optica. *Lancet Neurol* 2012; **11(6)**:535-44. Doi.10.1016/S1474-4422(12)70133-3.
2. Jarius S, Ruprecht K, Wildemann B, Kuempfel T, Ringelstein M, Geis C, et al. Contrasting disease patterns in seropositive and seronegative neuromyelitis optica: A multicentre study of 175 patients. *J Neuroinflammation* 2012; **9**:14. doi. 10.1186/1742-2094-9-14.
3. Uzawa A, Mori M, Kuwabara S. Neuromyelitis optica: Concept, immunology and treatment. *J Clin Neurosci* 2014; **21(1)**:12-21. doi.10.1016/j.jocn.2012.12.022.
4. Nair KR, Sahasranam KV. Multiple sclerosis in Malabar. *J Assoc Physicians India* 1978; **26(10)**:899. doi 10.4103/0028-3886.232301.
5. DeLuca GC, Joseph A, George J, Yates RL, Hamard M, Hofer M, et al. Olfactory pathology in central nervous system demyelinating diseases. *Brain Pathol* 2015; **25(5)**:543-51. doi 10.1111/bpa.12209.
6. Adawi M, Bisharat B, Bowirrat A. Systemic Lupus Erythematosus (SLE) complicated by neuromyelitis optica (NMO-Devic's Disease): Clinic-pathological report and review of the literature. *Clin Med Insights Case Rep* 2014; **7**:41-7. doi. 10.4137/CCRep.S15177.
7. Scolding N. The differential diagnosis of multiple sclerosis. *J Neurol Neurosurg Psychiatry*. 2001; **71(Suppl 2)**:9-15. doi. 10.1136/jnnp.71.suppl\_2.ii9.
8. Trebst C, Jarius S, Berthele A, Paul F, Schippling S, Wildemann B, et al. Neuromyelitis optica study group. Update on the diagnosis and treatment of neuromyelitis optica: Recommendations of the neuromyelitis optica study group (NEMOS). *J Neurol* 2014; **261**:1-6. doi 10.1007/s00415-013-7169-7.
9. Bichuetti DB, Oliveira EM, de Castro Boulos F, Gabbai AA. Lack of response to pulse cyclophosphamide in neuromyelitis optica: Evaluation of 7 patients. *Arch Neurol* 2012; **69(7)**:938-9. doi.10.1001/archneurol.2012.545.
10. Min JH, Kim BJ, Lee KH. Development of extensive brain lesions following fingolimod (FTY720) treatment in a patient with neuromyelitis optica spectrum disorder. *Mult Scler J* 2012; **18(1)**:113-5. doi 10.1177/1352458511431973.

• • • • •