

Perioperative Nursing of Diffuse Pulmonary Ossification

Fa-Yue Zhang, Ai-Ling Jiang and Tie-Quan Sui

Department of Thoracic Surgery, The Fifth Central Hospital, Binhai District, Tianjin 300450, China

ABSTRACT

This study aims to describe the clinical manifestations of diffuse pulmonary ossification, explore the diagnostic methods to reduce the misdiagnosis rate, and discuss its nursing treatment in the perioperative period. In The Fifth Central Hospital of Tianjin, one patient with diffuse pulmonary ossification, confirmed by surgical lung biopsy, was reported; and the clinical features and effective nursing methods are analysed. The patient was a 16-year teenager, who developed sudden convulsions without obvious cause with limited respiration. After the mental state was restored, the patient presented with chest tightness, shortness of breath, cough and expectoration. Hence, the subject was admitted in our hospital. Routine and imaging examinations failed to draw a definite diagnosis. Then, lung biopsy was performed, and a diagnosis of diffuse pulmonary ossification was made. Diffuse pulmonary ossification is very rare in clinical practice. The clinical manifestations are nonspecific, and imaging features are characterised by diffuse lung damages. Therefore, it is easily misdiagnosed as other interstitial lung diseases. Lung biopsy can be used to confirm this disease. Sequential acupoint stimulation by tapping the back can relieve cough and help patients recover quickly.

Key Words: *Diffuse pulmonary ossification, Nursing, Sequential acupoint stimulation, Interstitial lung disease.*

How to cite this article: Zhang FY, Jiang AL, Sui TQ. Perioperative nursing of diffuse pulmonary ossification. *J Coll Physicians Surg Pak* 2020; 30(1):90-93.

INTRODUCTION

Diffuse pulmonary ossification (DPO) is a disease characterised by ossification of the parenchyma of the lungs. These lesions are mainly located among the alveoli, lobules, and in the subpleural connective tissues. DPO is very rare in clinical practice. Since, it was reported for the first time by Luschka in 1856, there are no more than 100 patients reported in the world.¹ The pathogenesis of DPO is not completely clear at present, and it has no obvious clinical symptoms. Therefore, it is easily misdiagnosed as other lung diseases. After the onset of DPO, patients present with atypical respiratory symptoms, such as dyspnea and wheezing, and there is no targeted nursing treatment.² In order to improve the understanding of the medical staff on this disease, reduce the misdiagnosis rate, and explore effective nursing methods, the present case is being reported.

CASE REPORT

A 16-year teenager, developed sudden convulsions without obvious cause with limited respiration 11 days back. The family members of the patient applied emergency chest pressure for rescue. After the mental state was restored, the patient presented with chest tightness and shortness

of breath, which gradually aggravated, accompanied by cough and expectoration. Then, the patient was admitted in our hospital.

This study was conducted with approval from the Ethics Committee of the Fifth Central Hospital of Tianjin. Written informed consent was obtained from participant. Chest computed tomography (CT) suggested that in the right pleural cavity, there were broad bands of water-like density shadows, and gas-liquid flat shadows; and a sheet-like increased density shadow could be observed. In the right lung, there were increased multiple patchy and nodular density and calcification shadows. Some lesions had blurred edges. Few quasi-circular low-density lesion could be observed, and the size was 2.7 x 4.8 cm. CT suggested a suspected diagnosis of right pulmonary tuberculosis, right bullae and right pulmonary liquid pneumothorax (Figures 1 and 2). In order to further verify the diagnosis, the patient was healthy previously and had no bad habits. Physical examination showed temperature (T): 37.7°C, pulse (P): 80 of bpm, respiration (R): 20/minute, blood pressure (BP): 130/70 mmHg. He was cooperative, temperature of the conjunctiva was pale; jaundice was negative; no lip cyanosis was observed; the trachea was located in the middle line; the aperture of thorax was symmetrical; the respiratory sounds of the right lung were low, and the respiratory sounds of the right lower lung were absent. Laboratory examinations showed hemoglobin of 76g/L, red blood cell specific volume (HCT): 26.2%, erythrocyte sedimentation rate (ESR) of 49 mm/h, and negativity of anti-tuberculosis antibody. The hydrothorax bacterial culture showed no bacterial growth. No fungus was found in the

*Correspondence to: Tie-Quan Sui, Department of Thoracic Surgery, The Fifth Central Hospital, No. 41, Tanggu Zhejiang Road, Binhai District, Tianjin 300450, China
E-mail: suitiequan@163.com*

Received: July 12, 2018; Revised: April 08, 2019;

Accepted: April 20, 2019

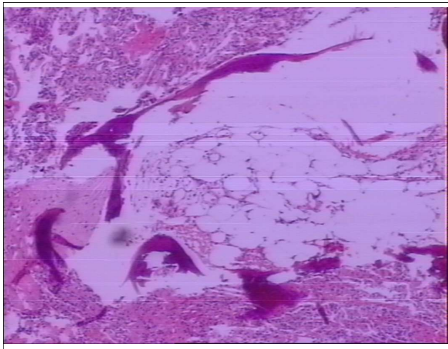


Figure 1: The lower right lung tissue pathological slices.

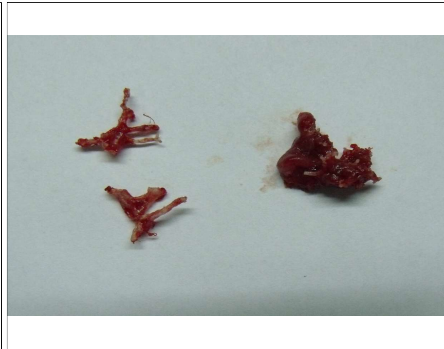

Figure 2: Osteoid in lesions of the lungs.

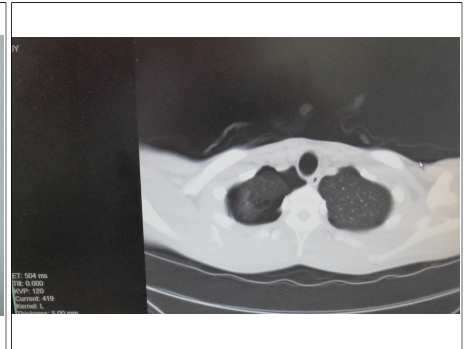

Figure 3: Preoperative chest CT images.

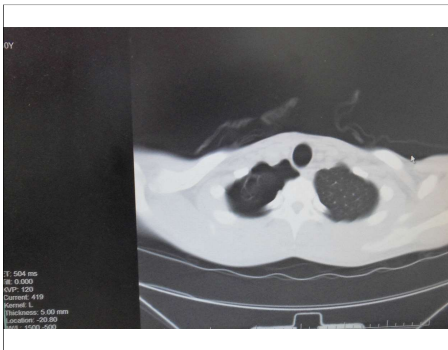

Figure 4: Preoperative chest CT images.

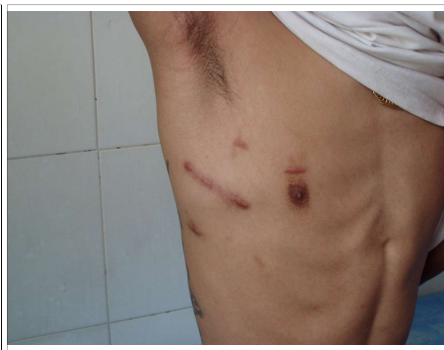

Figure 5: The small incision on the patient's chest underarm.

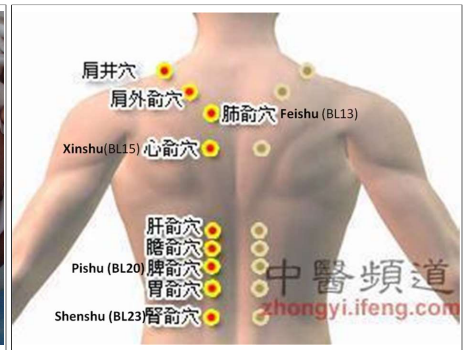


Figure 6: Acupoints from traditional Chinese medicine were commonly used in this article.

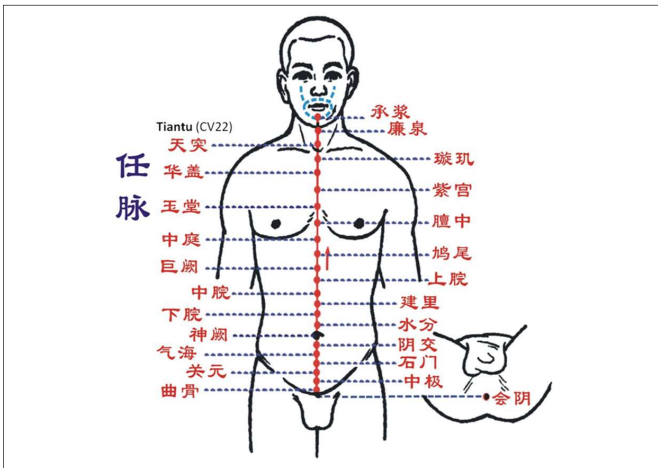


Figure 7: Acupoints from traditional Chinese medicine were commonly used in this article.

hydrothorax smear. Right pleural effusion (a small amount) was found by chest B ultrasound. The patient underwent symptomatic treatment, such as right thoracic closed drainage, blood transfusion, antibiotics, expectorants and protection of pulmonary function. Since the patient's symptoms were not completely consistent with the diagnosis, the nursing method summarised and self-created by the Department of Thoracic Surgery in our hospital, which is the method of sequential acupoint stimulation, was adopted for nursing treatment. At three days of hospitalisation, auscultation

was performed. The patient's right lower lung revealed low respiratory sounds, as well as a few scattered rales. On chest CT, the right hydropneumothorax was significantly reduced, when compared with that at admission; but a large volume of effusion remained in the right lower thoracic cavity. There were lesions in the posterior segment of the right upper lobe, and the dorsal segment and posterior basal segment of the lower lobe. The diagnosis of tuberculosis was not excluded. B-ultrasound-guided right thoracic biopsy was carried out, and a small amount of coagulated blood was withdrawn (Figure 3). In order to further verify the diagnosis, the patient underwent small-incision right exploratory thoracotomy under general anesthesia. During the operation, a small amount of deferent serosanguinous fluid and multiple blood clots were found in the right lower thoracic cavity. There were diffuse thickening and nodular changes in the posterior segment of the right upper lobe, and the dorsal segment and posterior basal segment of the lower lobe of the lungs. A giant cyst was found in the right thoracic cavity. The lesions were hard with osteoid substances and bone-like masses. Some nodules were obtained from the right lower lung for pathology (Figures 4 and 5). In the samples, collapse of the alveoli was found in lung tissues, with mild hyperplasia of interstitial fibrous tissue and a small amount of hemorrhage and scattered macrophages in the alveolar cavities. Multiple antler-like or dendritic, irregular calcification and ossification

lesions were observed. Furthermore, there were some lamellar bone-like masses in some ossification lesions, which contained fatty marrow islands. Mild fibrous thickening was observed on the visceral pleura. The final pathological diagnosis was DPO (dendritic subtype). In the early postoperative period, the nurses in thoracic surgery assisted the patient in sputum excretion and guided the patient to carry out respiratory movement exercises according to the self-created nursing programme. According to the locations of the acupoints marked by the thoracic surgeons (Figures 6 and 7), in the direction of the back-chest and bottom-top, along the line, 5 cm apart from the spine, the Shenshu acupoint was first stimulated. The acupoints were heavily hit by empty palms. Hence, the air in the empty palm impacted the acupoints. The BL43 and Feishu acupoints were the key. Next, the Tiantu acupoint was pressed with the index finger five times, and 20 actions were completed in each round. Lung function was examined after 30 minutes. Blood oxygen saturation (SpO₂) and PCT were detected at the same time. After the operation, the patient recovered well and were followed up. The patient was instructed to receive regular reexaminations.

DISCUSSION

DPO is a lung disease with slow progression. Patients with DPO are usually asymptomatic or only have mild symptoms. The imaging features are characterised by diffuse lung damages. Therefore, it can easily be misdiagnosed as other interstitial lung diseases.³ Targeted professional nursing care has become a challenge in these cases. If the method of nursing treatment is incorrect, it would be difficult to help the patient recover. The etiology of DPO remains unclear. The pathogenesis is usually correlated to chronic diffuse lung disease, mitral stenotic heart disease, or other systemic disorders.⁴ Most patients are accidentally detected on autopsy, and only few patients have been diagnosed by pathological examination of living lung tissues.⁵ There are no clear diagnostic criteria in China. The diagnosis depends mainly on imaging and pathological examinations.

DPO is divided into two subtypes: dendritic and nodular. The characteristic of the dendritic subtype is that the ossification lesions are distributed along the terminal airways in a dendritic arrangement. Occasionally, these lesions invade the alveolar cavities. In the nodular subtype, nodules with clear margins are formed in the surrounding lung tissue or under the membrane of the lungs, and the ossification lesions are located in the alveoli. The lesions of both subtypes are comprised of mature lamellar bone. The bone trabeculae are generally <1 cm, and the periphery of the bone trabeculae has or has no osteoclasts.⁶ The most important difference between these two subtypes is that fat and bone marrow

tissue can be observed in the ossification lesions of most dendritic cases, while fat and bone marrow tissue cannot be observed in most nodular subtype.⁷ The CT manifestations of the nodular subtype are mainly characterised by high density nodule shadows with a diameter of 1-5 mm, which are partially fused or lobulated. The CT manifestations of the dendritic subtype are mainly characterised by highly branched linear non-transparent areas and "coral reef" shadows. Pathological examination of the lung tissue should be performed when a mature bone tissue is found in the lung parenchyma, allowing the diagnosis of DPO to be definitely made.⁸ Multiple antler-like or dendritic irregular calcification lesions and lesions with fatty bone marrow islands could be observed in lung tissues of the pathological section of the patient.

DPO should be distinguished from interstitial pulmonary fibrosis, pulmonary metastatic tumor, bronchiectasis and miliary tuberculosis.⁹ There is presently no effective prevention and treatment for DPO. Search for effective nursing methods for these patients has also become a challenge in clinical work. Thoracic operative procedures would inevitably cause injury to the tissues and organs in the thoracic cavity. In addition, the patients themselves lack preoperative guidance for breathing training. It is easy to induce postoperative complications, such as respiratory dysfunction and pulmonary infection, which impair the effect of the operation,¹⁰ causing adverse effects on pulmonary function. Traditional perioperative professional nursing measures, such as the management of the respiratory tract, observation of the condition and assistance of sputum excretion, cannot meet the need of rapid postoperative rehabilitation for patients with this special disease. It has been pointed out in traditional Chinese medicine that acupoints are the sites of the body where the qi from the meridians and viscera are infused to the body's surface. Hence, stimulating certain acupoints can regulate the viscera, qi and blood through the meridians and collaterals, and accordingly activate the resistance to disease in the body. Based on this theory, it would be summed up that stimulations on Tiantu, Xinshu, Feishu, Dingchuan, BL43, Pishu and Shenshu are acupoints that have good clinical effects in the recovery of pulmonary function after thoracic surgery.⁷ Thus, the sequential acupoint stimulation method was proposed. This new perioperative nursing programme has achieved good curative effect in the perioperative nursing of this special patient. This nursing method can better help patients quickly recover their pulmonary function after the operation, which has high practicability and popularisation value.

Timely diagnosis can help better understand the development and pathogenesis of the disease. Effective nursing methods should be actively explored to find new treatments and nursing programmes.

PATIENTS' CONSENT:

Consent for publication was obtained from every patient whose data are included in this manuscript.

CONFLICT OF INTEREST:

Authors declared no conflict of interest.

AUTHORS' CONTRIBUTION:

ZFY: Conceptualised and designed the study, drafted the initial manuscript, reviewed and revised the manuscript, and approved the final manuscript.

ZFY, JAL: Designed the data collection instruments, collected data, carried out the initial analyses, reviewed and revised the manuscript, and approved the final manuscript.

STQ: Coordinated and supervised data collection, critically reviewed the manuscript for important intellectual content, and approved the final manuscript.

REFERENCES

1. Jaderberg JM, Dunton RF. Rare clinical diagnosis of dendriform pulmonary ossification. *Ann Thorac Surg* 2001; **71**: 2009-11.
2. Mizushina Y, Bando M, Hosono T, Mato N, Nakaya T, Yamasawa H, *et al.* A rare case of asymptomatic diffuse pulmonary ossification detected during a routine health examination. *Intern Med (Online)* 2012; **51**:2923-7.
3. Kinoshita Y, Mizuguchi I, Hidaka K, Ishii H, Watanabe K. Familial diffuse pulmonary ossification: A possible genetic disorder. *Respir Investig* 2017; **55**:79-82.
4. Avsar K, Behr J, Morresi-Hauf A. Diffuse pulmonale ossification. *Pneumologie* 2016; **70**:241-9.
5. Jamjoom L, Meziane M, Renapurkar RD. Dendriform pulmonary ossification: Report of two cases. *Indian J Radiol Imaging* 2013; **23**:15-8.
6. Wang Y, Han JY. Video-assisted thoracoscope for the treatment of 52 cases of spontaneous pneumothorax. *Chinese J End Sur Elec Vis* 2013; **6**:59-61.
7. Marchioni E, Souza AS, Franquet T, Müller NL. Diffuse high-attenuation pulmonary abnormalities: A pattern-oriented diagnostic approach on high resolution CT. *AJR Am J Roentgenol* 2005; **184**:273-82.
8. Bisceglia M, Chiaramonte A, Panniello G, Tucci A, Orcioni GF, Colby TV. Selected case from the Arkadi M. Rywlin international pathology slide series: Diffuse dendriform pulmonary ossification: Report of 2 cases with review of the literature. *Adv Anat Pathol* 2015; **22**:59-68.
9. Roriz D, Inês A, Cristina M, Luisa T, Pedro BS, Filipe CA. Diffuse pulmonary ossification: A case report. *Eur J Radiol Open* 2016; **3**:46-8.
10. Ohtsuki Y, Mori K, Ohnishi H, Enzan H, Iguchi M, Lee GH, *et al.* Investigation of aluminum and iron deposition on metaplastic bones in three patients with diffuse pulmonary ossification. *Med Mol Morphol* 2015; **48**:235-8.

