

Cirroid Aneurysm of the Scalp: A Rare Finding in Neurosurgery

Sir,

Cirroid aneurysm of the scalp is one of the rarest occurrences in neurosurgery. It is an aneurysmal tumor formed by arteriovenous fistula of the arteries and veins of the scalp.¹ Atriovenous malformation (AVM) is formed due to abnormal communication between feeding arteries and draining veins with an absence of intervening capillary bed. It is predominantly congenital, but becomes apparent after a minor trauma, surgery (hair transplant, craniotomies) and scalp vein infusions.² Here, we present a case of cirroid aneurysm in a woman after trauma.

A 23-year female, with no known comorbidities, came to the Neurosurgery Department of the Hospital, with the complaint of swelling on her forehead for 5 years (Figure 1). The swelling was a result of minor trauma to head where she hit her head against a wall. The swelling grew in size with time; it was not associated with a headache, bleeding or signs of rupture. She was otherwise completely healthy and had no significant past clinical history. On examination, the swelling was serpentine shaped, 10 x 1.5 cm extending from vertex to glabella. There was decreased hair growth in the area but no discoloration of the skin. The swelling was superficial, soft, non-tender, non-mobile, but fluctuating and pulsatile. On auscultation, a bruit along with a machinery murmur was heard over the swelling. Vitals were within normal limits and the rest of the examination was unremarkable. The diagnosis of a cirroid aneurysm was made based on findings seen in CT angiogram (Figure 2). The angiogram showed a fistulous communication and the main feeding arteries were found to be superficial temporal and supraorbital arteries. There was no evidence of the involvement of sagittal sinus; however, small communication with calvarial emissary veins was noted. The patient was planned for 'en bloc' resection and the operation was performed by the neurosurgical team of our Hospital. During the operation, a U-shaped incision was applied which exposed the frontal region of the scalp, smaller scalp vessels were cauterised. No major connections with intracranial dural sinuses were found. The major vessels that were ligated and resected were the superficial temporal artery and the supraorbital artery. There were no operative or postoperative complications encountered. The patient showed remarkable recovery and was discharged on account of satisfactory condition.

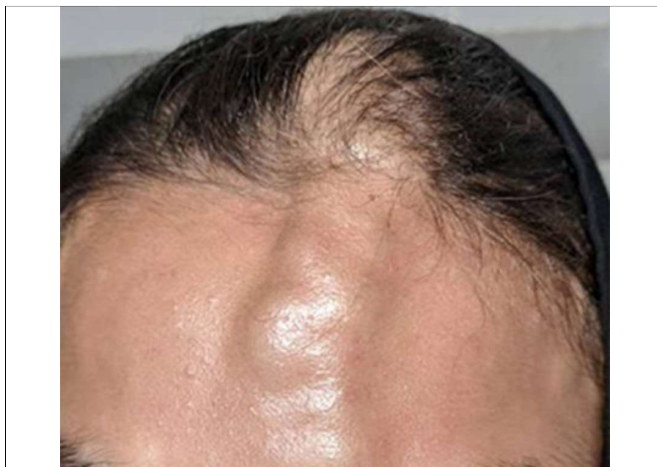

Figure 1: Serpentine swelling noted from vertex to glabella with decreased hair growth in the area.

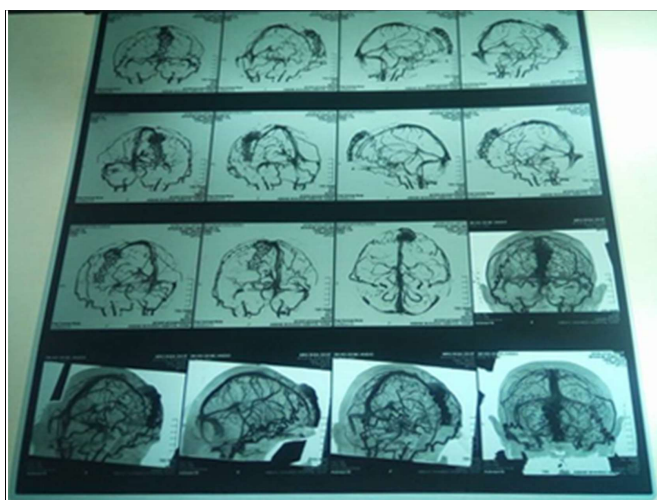


Figure 2: CT angiogram showing connections between different arteries and emissary veins

The symptoms associated with cirroid aneurysm of scalp vary according to the size of the fistula. Common clinical manifestations include loud bruit, pulsatile scalp mass, headache, and tinnitus. If left untreated, there is an increased risk of developing life-threatening complications such as aneurysmal hemorrhage or scalp necrosis.³⁻⁵ The commonest artery involved is the superficial temporal artery, due to its long and twisted course. The different methods of treatment include 'en bloc' resection and primary closure of the lesion, and sclerotherapy in which sodium tetradecyl sulfate is injected into the unwanted vessels with carbon dioxide gas, and the vessel is made to undergo sclerosis. The latter is associated with complications such as thromboembolism, allergy and skin necrosis. Direct puncture endovascular embolisation, using either chemical NBCA, absolute alcohol or mechanical coils, is another effective method widely used for AVM correction and an old

method of ligation of feeding arteries, which is associated with formation of collaterals and recurrence.¹ The most effective surgical method, however, is 'en bloc' resection and the most effective non-surgical method is the percutaneous direct puncture embolisation.

Even after complete surgical resection, a case of recurrence after 18 years has been reported⁵, which is why regular follow-up is advised.

REFERENCES

1. Elkin DC. Cirroid aneurysm of the scalp with the report of an advanced case. *Ann Surg* 1924; **80**:332-40.
2. El Shazly AA, Saoud KM. Results of surgical excision of cirroid aneurysm of the scalp without preoperative interventions. *Asian J Neurosurg* 2012; **7**:191-6.
3. Mohamed WN, Abdullah NN, Muda AS. Scalp arteriovenous malformation: A case report. *Malays J Med Sci* 2008; **15**:55-7.

4. Kohout MP, Hansen M, Pribaz JJ, Mulliken JB. Arteriovenous malformations of the head and neck: natural history and management. *Plast Reconstr Surg* 1998; **102**:643-54.
5. Wilkinson HA. Recurrence of vascular malformation. of the scalp 18 years following excision. Case report. *J Neurosurg* 1971; **34**:435-7.

Asra Ahmed¹, Rama Siddiqui² and Abdul Ali Khan¹

¹ Department of Neurosurgery, Abbasi Shaheed Hospital, Karachi, Pakistan

² Department of Pathology, United Medical and Dental College, Karachi, Pakistan

*Correspondence: Dr. Asra Ahmed, Department of Neurosurgery, Abbasi Shaheed Hospital, Karachi, Pakistan
E-mail: asraahmed94@yahoo.com*

Received: October 11, 2018; Revised: January 04, 2019;

Accepted: January 04, 2019

