

# Idiopathic Dilatation of the Colon in a Nursing Home Resident, with a Suspected Acute Colonic Pseudo-Obstruction (Ogilvie Syndrome)

Mariusz Chabowski<sup>1,2</sup>, Bartosz Bieganski<sup>2</sup>, Jakub Kobecki<sup>2</sup>, Mateusz Szponder<sup>2</sup> and Dariusz Janczak<sup>1,2</sup>

## ABSTRACT

Ogilvie syndrome (acute colonic pseudo-obstruction) represents a clinical condition with symptoms of colonic obstruction without a distinct mechanical factor. The damage to the neural ganglia in the intestinal wall is the most likely etiology. A 62-year man was admitted to the Emergency Department due to acute dyspnea and vomiting. The patient had not defecated for 10 days prior to admission. An angio-CT revealed dilated colon, especially its left part, up to 85 mm with gas inside its lumen. During laparotomy, extremely dilated colon was confirmed with signs of the intestinal wall necrosis. A left sided hemicolectomy was performed. Despite the intensive treatment in the intensive care unit (ICU), the patient died on 3rd day after the surgery. In this case, the acute pseudo-obstruction of the large intestine was recognised late. This is due to overcrowding in this type of institution, overworked staff, and their inability to give individual attention to each patient.

**Key Words:** *Ogilvie syndrome, Acute colonic pseudo-obstruction (ACPO), Colon dilatation, Explorative laparotomy, Hemicolectomy.*

## INTRODUCTION

Ogilvie syndrome, also known as acute colonic pseudo-obstruction, was initially described in 1948 by a British surgeon, William Heneage Ogilvie. He described cases of patients with symptoms of colonic obstruction without any mechanical factors being involved. The specimens revealed tumour that had invaded the intestinal wall with a clear damage to the neural ganglia in the area. This led to the conclusion that the condition is caused by the damage to the neural ganglia in the intestinal wall. Nowadays, it is still considered to be the most likely etiology.<sup>1</sup> A decade after the publication of Sir Ogilvie's paper, Dudley *et al.* described several dozen patients with a similar condition.<sup>2</sup> The number of cases led him to introduce a new classification and to use the term of the acute colonic pseudo-obstruction (ACPO) for the first time.<sup>3</sup> ACPO is a condition in which colon dilatation and ileus is not caused by a mechanical obstacle, infectious or any inflammatory agent.<sup>4</sup> The exact etiology is still unknown, but ACPO is more frequent among people over 60 years, hospitalised with serious chronic diseases or residents of nursing homes. Obesity is a possible contributing factor.<sup>1</sup> It is commonly noted that

patients with ACPO have poor performance status, with a history of operative treatment and metabolic imbalances. The Ogilvie syndrome is most common in certain postoperative periods, such as coronary artery bypass grafting and other cardiothoracic procedures.<sup>1</sup> Orthopedic procedures (like hip and knee replacement and spinal procedures), general surgery (laparoscopic cholecystectomy and hernias), and peripheral vascular treatment are also widely mentioned in the medical literature. ACPO may also occur after cesarean section and kidney transplantation.<sup>5</sup> Dilatation may include part of the colon or even whole large colon together with rectum.<sup>4</sup> The symptoms of Ogilvie syndrome are similar to other conditions with intestinal dilatation such as Hirschsprung disease, megacolon toxicum or chronic intestinal pseudo-obstruction (CIPO). All of these should be taken into consideration during the process of differential diagnosis. A moderate, diffuse abdominal discomfort, constipation, abdominal distension, nausea/vomiting (especially after meals), lack of bowel movement and/or flatulence are seen in the clinical presentation of ACPO.<sup>6</sup> When undiagnosed, the condition may lead to serious complications and even to death.

## CASE REPORT

A 62-year man, resident in a nursing home, was admitted to the Emergency Department. Flatulence and vomiting were the main complaints. During examination, the patient was awake, although the contact was limited, and it was impossible to judge his mental status. Body mass index (BMI) was 30.1. Blood tests of the patient on admission are shown in Table I. Metabolic acidosis was increasing and respiratory failure was developing (Table I). Patient's high hemoglobin (Hb) and hematocrit

<sup>1</sup> Department of Clinical Nursing, Faculty of Health Science, Wrocław Medical University, 5 Bartla Street, 51-618 Wrocław, Poland

<sup>2</sup> Department of Surgery, Fourth Military Teaching Hospital, 5 Weigla Street, 50-981 Wrocław, Poland

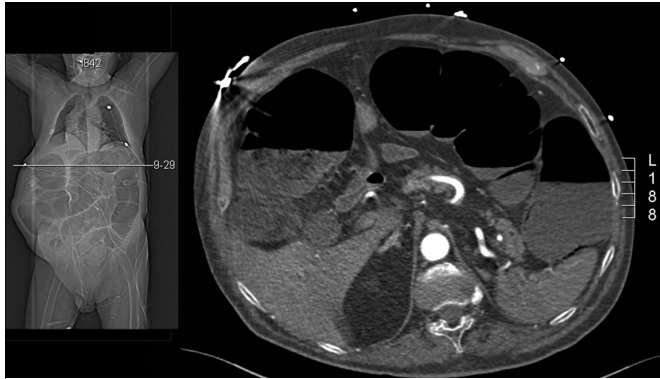
Correspondence: Dr. Mariusz Chabowski, Department of Surgery, Fourth Military Teaching Hospital, 5 Weigla Street, 50-981 Wrocław, Poland

E-mail: mariusz.chabowski@gmail.com

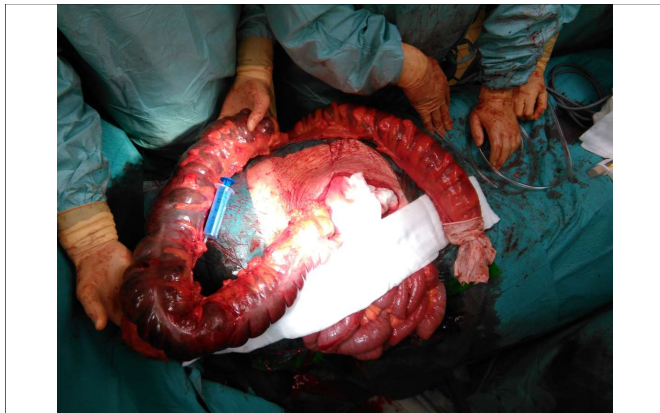
Received: May 14, 2018; Accepted: August 30, 2018

**Table I:** Patient's blood test results at admission.

pH	7.23 (N:7.35-7.45)
pCO <sub>2</sub>	17.3 mmHg (N:34-48)
pO <sub>2</sub>	67 mmHg (N:83-108)
HCO <sub>3</sub> std	11.6 mmol/l (N: 22.5-26.9)
SpO <sub>2</sub>	89.1%
Lactate	21.8 mmol/l (N: 0.5-1.6)
Hemoglobin	21.9 g/dl (N: 14-18)
Hematocrit	66.8% (N:41-52)
Platelet	386 (N: 140-400)



**Figure 1:** Computed tomography angiography scan showing the occlusion of the gastrointestinal tract with extreme dilation of the intestine, which was full of gas in the upper left abdomen.



**Figure 2:** Intraoperative view showing an extreme colon dilatation in comparison with a syringe (20ml).

(Hct) might have been associated with obesity and dehydration combined with developing respiratory distress resulting in relative erythrocytosis. The patient was intubated due to worsening condition. The abdomen was extremely bloated, elevated above the chest level, tender and difficult to palpate. The patient was showing a characteristic O-sign. Peristalsis was decreased during auscultation. Information from the nursing home revealed that the patient had not defecated for 10 days. Eleven years earlier, the patient had undergone surgery for a brain hematoma. Since then, he had been suffering from left hemiplegia and an altered mental state, which required a full time care.

An angio-CT showed occlusion of the gastrointestinal tract with extreme dilation of the intestine, which was full

of gas in the upper left abdomen (Figure 1). The patient was qualified for a surgical treatment. Due to high risk of perforation, increase in inflammatory markers, and the patient's generally worsening condition, surgery was performed during the night shift. Just before the operation, surgeon manually removed large stool masses from the rectum. During a scout laparotomy, extreme colon dilatation was confirmed (Figure 2). The distal part of the transverse colon, the descending colon, the sigmoid colon, and the rectum were visibly necrotic. A left sided hemicolectomy was performed. The spleen was damaged during the procedure and was removed afterwards. The rectum was sealed with a stapler, and a colostomy was placed in the upper left quadrant. A drain was inserted in the rectovesical pouch. Histological examination revealed intestinal wall necrosis with inflammatory cell infiltration of the muscle layer. A diffuse inflammatory reaction was discovered during the examination of the spleen.

After the procedure, the patient was transferred to intensive care unit (ICU) due to his constantly deteriorating general condition. In the ICU, multi-organ failure was observed as the patient was going through a septic shock. An attempt was made to correct fluid and electrolyte disturbances. Antibiotic empiric therapy was begun, as well as catecholamines in response to persistent hypotonia. Due to acute renal failure, renal replacement therapy was performed with continuous haemodiafiltration (CVVHDF) by using an Oxiris filter.

Despite intensive treatment, multi-organ failure continued, and the patient's condition was constantly deteriorating. On the third day after the surgery, patient died.

## DISCUSSION

The patient was admitted to the surgical ward in a poor general condition and a complicated history, as described above. Initially, during the physical examination, the abdominal pain was mild, with peristalsis and tympanic sounds present above the abdominal area. Symptoms of peritoneal irritation (absent in the case described here) or signs of inflammation in additional studies such as fever, leukocytosis or an increase in CRP indicate the possibility of an intestinal perforation or ischaemia.<sup>4</sup> The indicators of inflammation in this case, although high, were not sufficient to confirm the likelihood of perforation due to intestinal distension. However, the lack of symptoms of peritoneal irritation, indicators of inflammation and low specificity of the physical examination, do not mean that there are no complications developing in the abdomen, and they should not weaken the surgeon's vigilance, which was perfectly confirmed in this case.<sup>6,7</sup> The risk of perforation in patients with Ogilvie syndrome is 15%. The mortality rate in case of this complication increases dramatically, even up to 50%, compared to uncomplicated ACPO, where it is 3%.<sup>7,8</sup> That is why, delay between the onset of

symptoms and diagnosis together with effective therapy is so dangerous. The longer it takes, the greater the risk of pathological distention of the intestine, ischaemia and perforation. It has been shown that the most important predictors of these complications are not well defined, but the dynamics of distension and the time, that has passed before a diagnosis is made, are important factors.<sup>6</sup> A study on 400 patients indicated that a widening diameter 14 cm was associated with a double risk of a patient's death and the postponement of intestinal decompression over 7 days increased the risk by up to five times.<sup>7</sup>

Depending on the patient's condition and the severity of the disease, the best method of treatment should be selected. The treatment may be either conservative or invasive. The latter is the colon decompression by using colonoscopic exsufflation and surgery. The conservative treatment should be conducted according to SAGES guidelines - the American Society for Gastrointestinal Endoscopy.<sup>9</sup> This type of treatment should be considered only when there are doubts about the diagnosis, when the patient's condition is stable and the dynamics of changes in the gastrointestinal tract allow the implementation of conservative methods without the risk of perforation.<sup>9</sup> Bearing in mind the importance of time and a close observation of changes in the gastrointestinal tract, conservative methods of treatment should not last longer than 24-48 hours, allowing for a change of procedure in the absence of improvement and further attempts to achieve remission. In patients where conservative treatment has been unsuccessful, who are without symptoms of peritoneal irritation and perforation, a pharmacological treatment with neostigmine is the next method of choice.<sup>6</sup>

The surgical procedure is always the ultimate treatment. An indication in favour of this procedure is lack of success in the conservative and pharmacological procedures, together with a clinical and imaging confirmation of the intestinal perforation or ischaemia.<sup>4</sup> The type of surgical procedure depends on the condition of the colon and the patient.

The most common treatments are a colostomy or a total or subtotal colectomy. Surgery significantly increases the risk of complications and increases mortality from 14-30% to 30-50% in patients undergoing surgery.<sup>4</sup>

In the study patient, due to his difficult history, the onset of symptoms could not be precisely defined. Bearing in

mind the risk benefit analysis, the decision was made to perform surgery, due to drastically worsening condition of the patient. The exploratory laparotomy confirmed the clinical and radiological suspicion of ACPO.

In summary, ACPO in the present case was undoubtedly recognised too late. We argue that the problem was not the delay between the time of diagnosis and therapy, but the time that elapsed from the beginning of the disease until the patient was admitted to the ward. The fact that the patient, who was bedridden and had not defecated for ten days, was not taken for a medical examination throughout the time, can be considered as negligence. This is probably due to the overcrowding in this type of institutions, overworked staff and their inability to give individual attention to each patient. The state of care for elderly patients closely correlates with the financial status of a given country.

## REFERENCES

1. Wells CI, O'Grady G, Bissett IP. Acute colonic pseudo-obstruction: A systematic review of aetiology and mechanisms. *World J Gastroenterol* 2017; **23**:5634-44.
2. Dudley HA, Sinclair IS, McLaren IF, McNair TJ, Newsam JE. Intestinal pseudo-obstruction. *J R Coll Surg Edinb* 1958; **3**:206-17
3. Ribbe M, Ljunggren G, Steel K, Topinkova E, Hawes C, Ikegami N, et al. Nursing homes in 10 nations: A comparison between countries and settings. *Age Ageing* 1997; **26** (Suppl. 2):3-12.
4. Pereira P, Djeudji F, Leduc P, Fanget F, Barth X. Ogilvie's syndrome-acute colonic pseudo-obstruction. *J Visc Surg* 2015; **152**:99-105.
5. Jayaram P, Mohan M, Lindow S, Konje J. Postpartum acute colonic pseudo-obstruction (Ogilvie's syndrome): A systematic review of case reports and case series. *Eur J Obstet Gynecol Reprod Biol* 2017; **214**:145-9.
6. Saunders MD. Acute colonic pseudo-obstruction. *Gastrointest Endosc Clin N Am* 2007; **17**:341-60.
7. Vanek VW, Al-Salti M. Acute pseudo-obstruction of the colon (Ogilvie's syndrome). An analysis of 400 cases. *Dis Colon Rectum* 1986; **29**:203-10
8. Galban D, Baiel JJ. An alternative approach to the terminal management of Ogilvie syndrome. *Case Rep Gastroenterol* 2017; **11**:352-8
9. ASGE standards of practice committee, Harrison ME, Anderson MA, Appalaneni V, Banerjee S, Ben-Menachem T, Cash BD, et al. Guideline: The role of endoscopy in the management of patients with known and suspected colonic obstruction and pseudo-obstruction. *Gastrointest Endosc* 2010; **71**:669-79.

