

# An Unusual Presentation of Langerhans Cell Histiocytosis

Usama Rehman, Zafar Ali, Nadira Mamoon

## ABSTRACT

Langerhans cell histiocytosis (LCH) is a rare entity formerly known as eosinophilic granuloma. It is characterised by clonal multiplication of langerhans cells (LCs) that can occur anywhere in the body, especially in connective tissue of skin, lymph nodes and bone. Although rare, the disorder frequently affects children. A 7-year male child presented with the complaint of swelling at glabella. CT-scan revealed a defect in the middle of both frontal bones with brain herniating out of it. The clinical differential diagnosis included osteomyelitis, Tuberculosis and encephalocele. Fine needle aspiration cytology (FNAC) was performed and diagnosis of LCH was confirmed by typical cytological features, followed by immuno-histochemical staining for CD1a.

**Key Words:** *Langerhans cells. Clonal. Cytology.*

## INTRODUCTION

Langerhans cell histiocytosis (LCH) is a rare disease process of unknown etiology. The disease can manifest in various ways. It has worldwide incidence of approximately 0.5/100,000 children per year, occurring more in the male gender.<sup>1</sup> LCH occurs due to atypical proliferation of the langerhans cells that normally reside in stratum spinosum layers of skin.<sup>2</sup> Common sites include skin, bone, lungs, spleen, liver, bone marrow and hypothalamic pituitary axis. Severity of the condition depends on the site involved. Generally, patients with solitary lesion have localised pain. Patients with disseminated disease involving bone marrow, liver, spleen and lungs may have a spectrum of clinical manifestations and have a worse prognosis.<sup>3</sup>

We present a case of LCH that presented as glabellar swelling, in a 7-year male.

## CASE REPORT

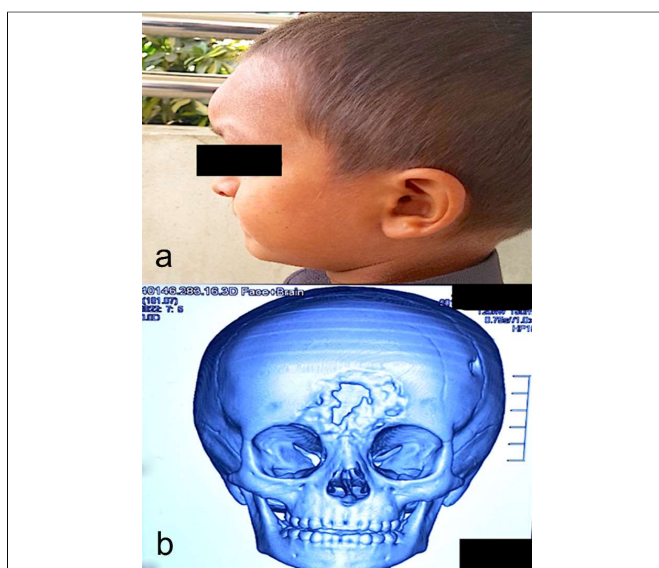
A 7-year male child referred from outside hospital to our department with the complaint of gradually increasing swelling at the glabella over a period of 8 months (Figure 1a). There was history of trauma 7 months back at this site without any associated symptoms, i.e nausea, vomiting, bleeding or loss of consciousness. On examination, swelling was soft, non-tender and measured 3.0 x 3.0 cm. Systemic examination revealed no significant finding. CT-scan brain showed a 2.0 x 1.2 cm defect in the middle of the frontal bone with brain herniating out of the defect (Figure 1b). MRI brain with contrast showed abnormal signals in the frontal sinus.

*Department of Histopathology, Shifa International Hospital, Islamabad.*

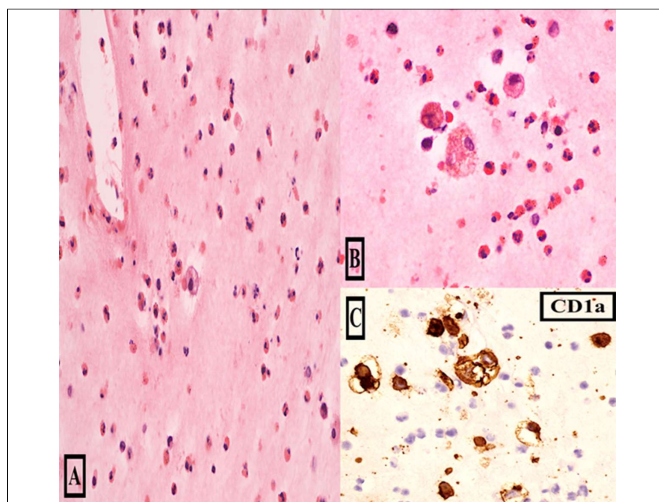
*Correspondence: Dr. Usama Rehman, Department of Histopathology, Shifa International Hospital, Islamabad.*

*E-mail: usama\_rhmn@yahoo.com*

*Received: March 13, 2018; Accepted: May 17, 2018.*



**Figure 1:** (a) Patient with prominent glabella swelling measuring 3.0 cm in diameter, (b) CT-scan brain showing defect in middle of both frontal bones.



**Figure 2:** (a) Photomicrograph of aspirate showing numerous eosinophils and few large cells (PAP stain x 20x), (b) Higher magnification showing the prominent nuclear elongation and grooving of Langerhans cells (PAP stains 40x), (c) Langerhans cells showing positive staining for CD1a (x 40x).

Fine needle aspiration cytology (FNAC) of the swelling revealed approximately 4-5 ml thin clear fluid. Air dried and alcohol fixed slides were stained and cell block prepared. The smears were cellular and showed mixed inflammatory cells comprising mostly of eosinophils. Isolated and clustered histiocytes were also found. These histiocytes showed characteristic nuclear features like enveloping, grooving and multinucleation (Figure 2a).<sup>4</sup> Occasional scattered giant cells were also present. Cell block showed similar morphology. Immunohistochemistry on cell block revealed all large atypical cells being positive for CD1a (Figure 2b). On the basis of all these findings, a final diagnosis of LCH was rendered.

## DISCUSSION

The existence of histiocytic disorders was acknowledged nearly a century ago. Langerhans cells are residents of skin and mucosa and are also known as dendritic cells (antigen-presenting immune cells).<sup>4</sup> Previously, LCH was splitted into Eosinophilic granuloma, Hand-Schüller-Christian disease, and Letterer-Siwe disease, depending on the site and severity.<sup>5</sup> Later, these were found to be the manifestations of a single entity and were merged under the term 'Histiocytosis X'. Most recently, this condition was renamed as LCH after the proposal by Nezelof that these cells are primary source and are involved in the pathophysiology of this disease.<sup>6</sup>

The clinical presentations differs, ranging from mild illness to life-threatening condition. The differential diagnosis also varies and depends upon the clinical presentation and site of involvement. Different organs and systems may be affected by LCH. In the skeletal system, skull and maxillary bones are commonly involved. Mucocutaneous lesions, presenting either as lesional deposits or extension of the disease process from involved bone to contiguous zone have been described.

The diagnosis of LCH can be confirmed on cytology in conjunction with immunohistochemistry for CD1a applied on the cell block. Cytologically, LCH shows langerhans cells with characteristic nuclear features including grooves and inclusions with background of mixed acute on chronic inflammatory cells comprising of eosinophils, lymphocytes, macrophages, neutrophils and giant cells. Eosinophils are more commonly related

to this disease and their number can vary from scarce to abundant in cytology smears. In our case, the differential diagnoses of skull lesions included Ewing's sarcoma, Non-Hodgkin lymphoma, and Osteomyelitis. Cytologically, Ewing's sarcoma and Non-Hodgkin lymphoma are characterised by diffuse monotonous population of small round blue cells, while osteomyelitis shows lymphocytes, neutrophils and plasma cells depending on the stage and severity of disease. Langerhan cells show positivity for S-100, langerlin and CD1a. Our case showed strong cytoplasmic immunopositivity with CD1a and S-100 antigen. Langerlin is not available in our laboratory. Electron microscopy, although rarely used for routine diagnosis, shows birbeck granules in cytoplasm of langerhan cells.

FNAC can be a very useful tool for diagnosing and documenting the extent of disease in multiple or recurrent lesions of LCH. In children, this procedure being minimally invasive, is very helpful for prompt and accurate diagnosis. Cell block preparation, as in our case, is very helpful in reaching a definitive diagnosis and it also helps in excluding other possible differential diagnosis which may pose a challenge.

This case highlights the role of FNAC in the diagnosis of LCH. The cytological features of LCH are highly characteristic to suggest a diagnosis in the appropriate clinical and radiological setting. Immunocytochemistry performed on cell block can obviate the need for the biopsy.

## REFERENCES

1. Yashoda-Devi BK, Rakesh N, Agarwal M. Langerhans cell histiocytosis with oral manifestations: a rare and unusual case report. *J Clin Exp Dent* 2012; e252.
2. Ablu O, Egeler RM, Weitzman S. Langerhans cell histiocytosis: current concepts and treatments. *Cancer Treat Rev* 2010; 354-9.
3. Allen CE, McClain KL. Langerhans cell histiocytosis: a review of past, current and future therapies. *Drugs Today* 2007; 627-44.
4. Kumar N, Sayed S, Vinayak S. Diagnosis of Langerhans cell histiocytosis on fine needle aspiration cytology: a case report and review of the cytology literature. *Pathol Res Int* 2011; 2011.
5. Golai S, Nimbeni B, Patil SD, Kakanur M, Paul S. Langerhans histiocytosis in a child-diagnosed by oral manifestations. *J Clin Diagn Res* 2015; ZD09.
6. Allen CE, Ladisch S, McClain KL. How I treat Langerhans cell histiocytosis. *Blood* 2015; 126:26-35.

.....☆.....