

A Case of Secondary Hypertension due to Giant Hydatid Cyst

Burcin Atak¹, Gulali Aktas¹, M. Zahid Kocak¹, Tuba Duman¹, Edip Erkus¹, Kamil Gurel² and Haluk Savli¹

ABSTRACT

Hydatid cyst is a parasitic infection which causes enormous morbidity and mortality worldwide. The pathogenic organism responsible for hydatid cyst is *Echinococcus granulosus*. Despite the fact that the characteristic cysts of the disease usually occur in liver and lungs, they may also occur in aberrant localisations. Subjects either present with symptoms of infection itself or local complications due to compressive mass effect of the cyst. Here, we report a case of secondary hypertension due to extrinsic compression of the right renal artery by a giant hepatic hydatid cyst. A 78-year woman presented with poorly controlled hypertension. She has been treated for hypertension with an angiotensin converting enzyme inhibitor plus calcium channel blocker for the last 2 years. Imaging studies revealed narrowing of the right renal artery and external compression, caused by a giant hydatid cyst. The giant hydatid cyst was treated by cyst aspiration and alcohol injection. Despite cessation of angiotensin converting enzyme inhibitor plus calcium channel blocker, she remained normotensive on follow-up visits. New onset and resistant hypertension cases in elderly should be carefully evaluated for secondary causes of hypertension, including renovascular conditions. Mass effect of the hydatid cyst disease should be considered in the differential diagnosis.

Key Words: Secondary hypertension, Hydatid cyst, Renal artery compression.

INTRODUCTION

Hydatid cyst is an anthrozoosis, caused by *Echinococci*. *E. granulosus*, *E. multilocularis* and *E. vogeli* are infectious members of *Echinococci* family. *E. granulosus* is the one that develops cysts during infestation, which include uncoloured, odorless, clear liquid, with millions of small larvae called protoscoleces. Hydatid cyst usually occurs in liver (69-80%) and lungs (10-22%). Rare localisations include spleen (1-8%), bone (0,2-3%), kidneys (0,4-3,7%), brain (0,4-1%), heart (0,02-1,1%), peritoneum (2-5,2%), and subcutaneous tissues (1,6%).¹

Reno-vascular hypertension (RVH) is one of the reasons of secondary hypertension and it is responsible for 1-5% of all hypertension cases.² It develops due to a decrease of renal perfusion pressure driven by arteriosclerosis or fibromuscular dysplasia. Elevated renin secretion from ischemic kidney leads to an increase in blood pressure and hypertension.

Here, we report a case of secondary hypertension due to external pressure to the right renal artery by a giant cystic lesion of hepatic hydatidosis.

CASE REPORT

A 78-year woman presented with headache and abdominal discomfort lasting for a week. She complained of a mild

abdominal pain located on the right side of the epigastric region. The pain was not associated with meals. Since the epigastric discomfort has begun, she has been suffering from headache. She has been diagnosed with hypertension 2 years ago and was being treated since then with a combination of Verapamil 180mg + Trandolapril 2 mg. She had been operated for hepatic hydatid cyst 10 years ago. Her family history was not relevant.

On physical examination, systolic/diastolic blood pressure was 170/80 mmHg, respiratory rate was 14 per minute, heart rate was 82/minute and body temperature was 36.9° C. Abdominal tenderness at the right upper quadrant was the only positive finding, rest of the examination revealed normal findings.

Routine serum biochemistry of the patient was in normal range. Serum cortisol at 8 am was normal. Urinary creatinine excretion in 24 hours was in normal range. Urinary metanefrin, catecholamines and cortisol in 24 hours were normal. Plasma renin activity was not increased. A renal artery Doppler ultrasonography was performed to exclude secondary causes. An 11x17 cm complex cystic lesion was found in the neighbourhood of the upper pole of the right kidney (Figure 1). Narrowing of the right renal artery was also noted. A magnetic resonance imaging (MRI) angiography revealed narrowness of the orifice of the right renal artery, and a giant cystic lesion, sized 14x19 cm, which displaced the right kidney inferiorly (Figure 2). Direct hemagglutination test for *E. granulosus* was positive at a titer of 1/320. The patient was referred to interventional radiologist for cyst aspiration. 2400 cc of liquid was aspirated from the cyst and the cyst was washed with saline, and shrinking of the cyst was visualised (Figure 3). Cyst ablation therapy was followed by oral albendazole (10 mg/kg) treatment.

Department of Internal Medicine¹ / Radiology², Abant Izzet Baysal University (AIB), Bolu, Turkey.

Correspondence: Dr. Gulali Aktas, Department of Internal Medicine, Abant Izzet Baysal University (AIB), Golkoy, 14280, Bolu, Turkey.

E-mail: draliaktas@yahoo.com

Received: March 02, 2018; Accepted: June 13, 2018.

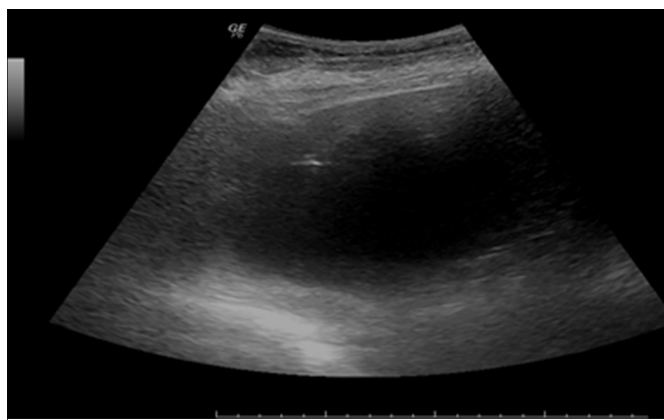


Figure 1: A 15x20 cm giant cyst located under the right side of diaphragm in sonography.

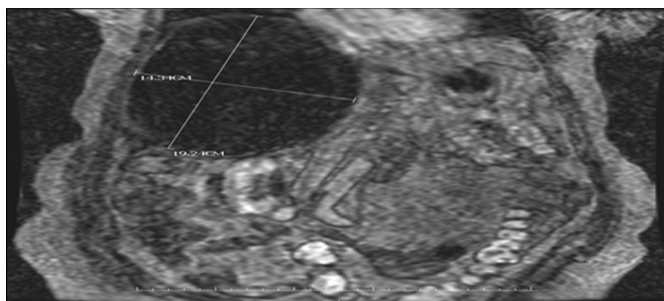


Figure 2: Giant cystic lesion, 143x192 mm in diameter located under the right side of diaphragm (Coronal T1A section after contrast enhancement).

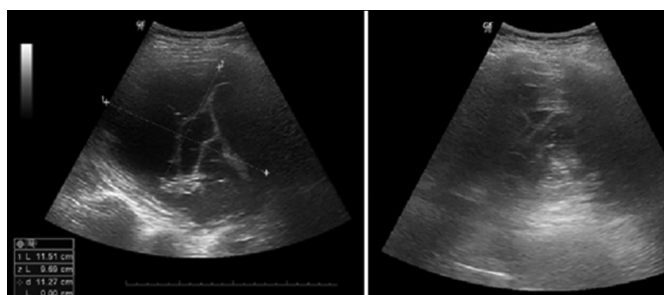


Figure 3: Sonographic appearance of the cyst during (A) and after (B) cyst aspiration.

Abdominal discomfort was relieved after cyst aspiration. She was discharged at 7th day of hospitalisation with full recovery. She remained normotensive at 30th day follow-up visit, without use of any antihypertensive drug.

DISCUSSION

Hydatid cyst is an endemic disease in certain territories of the world. It usually occurs in rural areas where agriculture and animal husbandry are common. Disease often affects young people, and involves liver and lungs. However, other organ involvement may also occur. Although most of the cases are asymptomatic, back pain, abdominal discomfort, and abdominal mass on physical examination are not rare. Complications of hydatid cyst include allergic reactions due to rupture of the cysts, infection of the cysts, and pressure symptoms. The present case was an elderly patient who was

admitted to our clinic due to abdominal discomfort caused by enlarged cysts.

Renovascular conditions are the leading cause of secondary hypertension. Renal artery stenosis is usually caused by fibro-muscular dysplasia in young and by atherosclerosis in the elderly. We included secondary hypertension in differential diagnosis since the case was an elderly person and because of elevated blood pressure despite regular use of two antihypertensive agents. Despite the fact that Doppler sonography showed a narrowing of the right renal artery, MRI angiography was needed to detect external pressure to the right renal artery by an enlarged hepatic hydatid cyst.

E. granulosus can settle in different parts of the body and cause various symptoms, which can lead to misdiagnosis. Therefore, physicians may encounter difficulties in establishing the correct diagnosis. Infective endocarditis,³ abdominal compartment syndrome,⁴ and pulmonary hypertension⁵ are rare presentations of hydatid disease. It can also cause cystic disease in various tissues.^{6,7} Rupture of the cyst may even cause anaphylactic shock. As an unusual presentation, giant hepatic hydatid cyst caused external pressure to the right renal artery in this case so the patient developed secondary hypertension and became normotensive after cyst aspiration. Before this, she was on treatment with two antihypertensive drugs for two years, as a result of delay in diagnosis.

Renovascular hypertension is an important cause of secondary hypertension.⁸ Among rare causes of renovascular hypertension, there exist Takayasu arteritis and paraganglioma.^{9,10} We presented a giant hydatid cyst disease as another rare cause of secondary hypertension, as seen in our case. Since renovascular diseases are curable causes of hypertension, these should be kept in mind during the differential diagnosis in hypertensive cases.

In conclusion, new onset and resistant hypertension cases in the elderly people should be carefully evaluated for secondary causes of hypertension, including renovascular conditions. Mass effect of the cyst of hydatidosis should also be considered in differential diagnosis in endemic areas.

REFERENCES

1. Eckert J, Deplazes P. Biological, epidemiological, and clinical aspects of echinococcosis, a zoonosis of increasing concern. *Clin Microbiol Rev* 2004; **17**:107-35.
2. Charles L, Triscott J, Dobbs B. Secondary hypertension: Discovering the underlying cause. *Am Fam Physician* 2017; **96**:453-61.
3. Gencheva DG, Menchev DN, Penchev DK, Tokmakova MP. An incidental finding of heart echinococcosis in a patient with infective endocarditis: a case report. *Folia Med (Plovdiv)* 2017; **59**:110-3.

4. Moreno Serrano A, Garcia Diaz JJ, Ferrer Marquez M, Moreno Marin P, Fabiano P. A propos of a case: Abdominal compartment syndrome caused by massive hydatid disease. *Rev Esp Enferm Dig* 2016; **108**:110-1.
5. Camporrotondo M, Vrancic M, Piccinini F, Navia D. Surgical treatment of pulmonary hypertension caused by echinococcosis disease. *J Thorac Cardiovasc Surg* 2014; **147**:e15-16.
6. Saadi A, Bouzouita A, Cherif M, Rebai MH, Kerkeni W, Ayed H, *et al.* Retrovesical hydatid cyst: About 4 cases. *Can Urol Assoc J* 2015; **9**:E374-8.
7. Aprea G, Aloia S, Quarto G, Furino E, Amato M, Bianco T, *et al.* Uncommon primary hydatid cyst occupying the adrenal gland space, treated with laparoscopic surgical approach in an old patient. *Open Med (Wars)* 2016; **11**:413-7.
8. Plouin PF, Bax L. Diagnosis and treatment of renal artery stenosis. *Nat Rev Nephrol* 2010; **6**:151-9.
9. Monnier G, Guerard S, Godon P, Van de Walle JP, Brion R. Paraganglioma associated with renal artery stenosis: unusual cause of secondary arterial hypertension. A case report and review of the literature. *Ann Cardiol Angeiol (Paris)* 2000; **49**: 168-73.
10. Zhang X, Xu Y, Chen X, Wang S, Li X, Yan X. Treatment of severe hypertension in a 14-year-old child: Successful blood pressure control with additive administration of captopril, an angiotensin-converting enzyme inhibitor, in a patient with bilateral renovascular hypertension. *Clin Exp Hypertens* 2017; **39**:587-91.

