ORIGINAL ARTICLE

Crigler Massage for Congenital Blockade of Nasolacrimal Duct

Jahanzeb Durrani

Abstract

Objective: To determine the success rate of non-surgical management of congenital nasolacrimal duct obstruction (CNLDO) with Crigler massage in infants below the age of one year.

Study Design: A cross-sectional observational study.

Place and Duration of Study: Department of Ophthalmology at HBS General Hospital, Hazrat Bari Sarkar Medical and Dental College, Islamabad from November 2015 to May 2016.

Methodology: One hundred children with watering of eyes, due to congenital blockage of the distal part of the nasolacrimal duct (at the valve of Hasner), unilateral or bilateral were included in the study. Initially, Crigler massage was advised to all the parents for a period of 1-3 months with practical demonstration and the results were documented every fortnight.

Results: There were 52 infants up to the age of 6 months and 48 infants between 6-12 months, 53% were boys and 47% were girls. Among them, 67% had unilateral complain while 33% were bilaterally affected. At the end of 1-3 months, 90% of the children achieved patency and only 10% of the cases were subjected to Bowman's probing under short anesthesia.

Conclusion: CNLDO mostly resolved through conservative approach by Crigler massage as an initial management, if done consistently. Probing and other surgical procedures should not be considered before the age of 12 months.

Key Words: *Nasolacrimal duct (NLD). Infants. Crigler massage. Nasolacrimal duct obstruction (NLDO). Epiphora. Dacryostenosis. Valve of Hasner. Probing. Dacryo-cysto-rhinostomy (DCR).*

INTRODUCTION

Canalization of the nasolacrimal is usually complete at birth. The duct measures 12 mm in length and opens into the nose through an ostium under the inferior meatus.[1] Presence of membranous obstruction at the lower end of the nasolacrimal duct (Valve of Hasner) occurs roughly in 50% of the newborn (dacryo-stenosis).[2] About 2-6% exhibit the clinical symptoms at 2-4 weeks of age with watering, sticky eyes and rarely swelling over the medial canthal area wherefrom pus can be expressed by finger pressure.[3-5] Of these, approximately one-third have bilateral involvement with no genetic or sex predisposition which causes concern among the parents. Numerous management options are available and can be divided into conservative (non-surgical) and surgical. Conservative options include use of antibiotics and lacrimal sac massage, needed to suppress the mucoid or purulent discharge.[5,6] In doubtful unilateral cases, fluorescein disappearance test (FDT) is helpful which can be performed as an outpatient procedure.

The rationale of this study is to emphasize the simplicity and ease of the conventional procedure. It is only 10% of cases where the obstruction persists, 90% of the cases resolve with Crigler massage within 6 months, especially in unilateral cases. Hence, more invasive intervention is indicated, but never before the age of one year.

It has generally been observed that the parents lack the knowledge of the massaging benefits and they force the ophthalmologists to undertake the surgical procedure,[6] without considering the possible dangers of anesthesia and surgical intervention. Children with persistent obstruction or failure of Crigler massage, beyond the age of one year, should be advised probing.[7-9] If symptoms persist after probing then the procedure should be repeated thrice. Crawford stent can be used to keep the passage patent, but the procedure fails in the long run. Since no such study on the benefits of Crigler massage has been reported in the literature, hence the author has ventured on the subject.

The objective of this study was to determine the success rate of Crigler massage in relieving CNLDO in infants.

METHODOLOGY

The study was conducted from November 2015 to May 2016 at Hazrat Bari Sarkar General Hospital, Islamabad. Infants below the age of one year, presented with watering of eye unilaterally or bilaterally, were included with no gender discrimination. Children with conjunctivitis, ophthalmia neonatorum, glaucoma, congenital anomalies due to punctal or canalicalur

Ophthalmology, Hazrat Bari Sarkar Medical and Dental College Hospital, Islamabad.

Correspondence: Dr. Jahanzeb Durrani, Assistant Professor of Ophthalmology and Visiting Eye Surgeon, Hazrat Bari Sarkar Medical and Dental College Hospital, Islamabad. E-mail: jahanzeb2011@live.co.uk

Received: October 15, 2016; Accepted: March 22, 2017.

atresia , entropion and trichiasis were excluded from the study.

In doubtful unilateral cases, flourescein disappearance test (FDT) was carried out as an outpatient procedure. Such patients were subjected to Crigler massage followed by pressure irrigation (PI) in cases where obstruction was not cleared with massage and / or topical treatment.

In Crigler massage, the parents were advised to do ten downwards stroking, 4 - 5 times daily. We let them go with common antibiotic eye drops like gentamycin 0.3%, 4 - 6 hourly for a longer period till the duct is canalized. Systemic antibiotics were prescribed in acute infections only. Usually the symptoms resolved within 6 months with repeated massage, but in less successful cases they were subjected to Bowman probing under general anesthesia. Surgical intervention was considered around the age of one year, but rarely before the age of 6 months. If symptoms persisted after the probing, the procedure was repeated up to 3 times. In recurrent cases, histopathology of the conjunctival secretions was also carried out. In fact, such cases were deferred till the conjunctival sac was completely aseptic.

Three probes of different calibers were negotiated successfully in the NLD and emerged out from the inferior ostium in the nose. In the presence of tainted blood, the probe was withdrawn and re-introduced carefully in order to avoid any trauma to the passage. After the procedure, the patients were usually discharged after 4 hours with the instructions to carry on Crigler massage at least 4-5 times daily with antibiotic eye drops for 4 weeks. The child was repeatedly observed after one day, one week, 3 weeks and 6 weeks to observe any recurrence of symptoms. If the parents still complained of epiphora, the procedure was repeated once or twice after a month. Finally, in cases of complete failure, the child was registered for dacryo-cysto-rhinostomy (DCR) surgery in due course of time.

RESULTS

One hundred (100) children with congenital blockade of nasolacrimal duct, unilateral or bilateral, were included in the study. There were 52 children up to the age of 6 months and 48 up to the age of 12 months (Figure 1) with mean age of 7 months. Out of them, 53 (53%) were boys and 47 (47%) were girls. Sixty-seven (67%) had unilateral blockade and complained of watering since birth, while 33 (33%) suffered bilateral blockade. According to the history, 70 (70%) of the patients were treated by the general practitioners who prescribed various antibiotics with or without steroids, being relieved of the symptoms temporarily. Parents of 30 (30%) patients consulted ophthalmologists and did not follow the treatment as instructed. None of the parents carried out proper massaging of the NLD with regularity.

Figure 1: BNLD before massage.

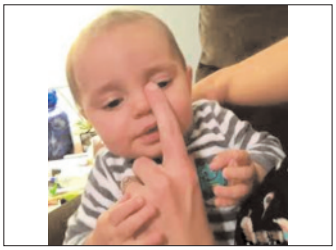

Figure 2: Method of massaging.

The parents were given proper instructions and training how to carry out massaging, 4 - 5 times a day (Figure 2). They were re-examined after every 3 weeks to notice any improvement of symptoms. Those cases who did not get relief, were advised to carry on further massaging for a period not more than 3 months. During this period, 90 (90%) of the children had the resolution of the symptoms with massage by the end of 3 months and only 6 (6%) required probing.

DISCUSSION

During embryonic development, the canalization of nasolacrimal apparatus is usually complete by birth.[9] However, membranous obstruction occurs up to 70% of the neonates (dacryo-stenosis) at the level valve of Hasner. However, it is only 2-5% of newborns, exhibit the clinical symptoms of nasolacrimal duct obstruction.[10] Studies have reported spontaneous resolution of the obstruction with conservative (non-surgical) management.

Clinically, infants present with epiphora which develops within 6 weeks of birth or may be earlier and the parents report of pussy discharge, recurrent conjunctivitis, crusting of the eyelids, and a swelling over the medial canthal area, expressing pus on pressure.[11-13] In this study, 52% of the children reported positive symptoms between the age of 1-6 months and 48% between the age of 6-12 months; and the time of onset of symptoms were invariable within 1 month after birth.

Previous work suggests that the nasolacrimal ducts are encountered with a normal burden of tears within the first few days of life.[14,15] Peterson *et al*. studied the natural course of congenital nasolacrimal obstruction in 50 infants and found that 44 infants had spontaneous resolution with conservative management.[13] They recommended the conservative treatment to be carried out for 6 - 8 months in the absence of congenital mucocele or any other pathology of nasal mucosa. In this study, only those cases were inducted which presented the obstruction at the lower end of the NLD. Cases with nasal pathology were excluded.

In 1923, Crigler described a technique of putting digital pressure over the nasolacrimal sac, rupturing the

membranous obstruction at the valve of Hasner. He reported 100% success with his technique during a 7-year period, but he did not indicate the size of his clinical series. In the present studies, 96 (96%) had the resolution of the symptoms at the end of 1-3 months, only 4 children required probing.

Nelson *et al*. reported a cure rate of upto 94.6% in 203 cases of congenital nasolacrimal duct obstruction by one year of age using a similar technique of Crigler massage,[16] which exactly co-related with this study.[6] Paul *et al*. reported a success rate of 87% in 55 patients within a period of 16 months with conservative therapy consisting of massage with topical antibiotic eye drops.[11] Many ophthalmologists insist that nasolacrimal duct obstruction should be managed conservatively whenever possible, as the majority will spontaneously open by 3-8 months of age.[15,17]

Miller *et al*. in 1700 cases introduced the concept of probing and irrigation, which was an exciting new method to evaluate the abnormality of lacrimal drainage system.[17] Ekinciler *et al*. performed pressure irrigation (PI) on his cases, where obstruction was not cleared with massage and/or topical treatment.[3] They reported that among the remaining 48 patients that did not benefit from massage, relief was obtained in 30 cases by PI. They added that PI should be attempted before probing in all patients.[18,19] It is interesting that very few investigators have advocated the use of PI. The author did not encourage PI in the outpatient department except in cases where Bowman probing was used with increasing caliber. Most of the cases responded well with the first engagement and we used the normal irrigation of the duct with saline to ensure the patency of the duct.

Crigler massage – a non-surgical management with antibiotic drops – resolved the symptoms in 75% of eyes within 6 months, but less successful with bilateral NLDO.[10] Children with persistent obstruction beyond one year of age are referred for probing, but rarely considered before the age of 6 months.[16,18] Only 4 cases persisted symptoms after probing and irrigation, hence the procedure was repeated.

The author did not encounter any complication of probing in any case like failure of the procedure, creation of false passage and bleeding or infection. This study lays more stress on the need of non-surgical and conservative management through repeated Crigler massage up to the age of 12 months with antibiotic drops and regular consultation by an ophthalmologist.

CONCLUSION

Congenital NLDO is a common problem in almost 5% of infants, which resolves spontaneously with Crigler massage in a high success rate. Probing or surgical procedures should not be considered prematurely before 6 months of age.

REFERENCES

1. Paul TO, Shepard R. Congenital nasolacrimal duct obstruction: natural history and the timing of optimal intervention. *J Pediatr Ophthalmol Strabismus* 1994: **31**:362-7.
2. MacEwen CJ, Young JD. Epiphora during the first year of life. *Eye (Lond)* 1991; **5** (Pt5):596.
3. Ekinciler OF, Dogan H, Tathsen N, Karakucuk S. Congenital nasolacrimal duct obstruction in Kayseri, Turkey. *Turk J Pediatr* 1994: **36**:21-33.
4. Hawre MJ. The dacryolithiasis syndrome. *Ophthal Plast Reconstr Surg* 1988; **4**:87-90.
5. Tucker N, Chow D, Stockl F, Codere F, Burnier M. Clinically suspectd primary acquired nasolacrimal duct obstruction: clinicopathologic review of 150 patients. *Ophthalmology* 1997: **104**:1881886.
6. Bartley GB, Acquired lacrimal drainage obstruction: An etiologic classification system, case reports, and a review of the literature. Part 1. *Ophthal Plast Recontructr Surg* 1992; **8**:217-42. Part 3. *Ophthal Plast Recontructr Surg* 1993; **9**:11-26.
7. Maini R, MacEwen CJ, Young JD. The natural history of epiphora in childhood. *Eye (Lond)* 1998; **12**:669.
8. Paul TO. Medical management of congenital nasolacrimal duct obstruction. *J Pediatr Ophthalmol Strabismus* 1985: **22**: 68-70.
9. Casady DR, Meyer, Simon JW, Stasior GO, Zabal-Ratner H. Stepwise treatment paradigm for congenital nasolacrimal duct obstruction. *Ophthal Plast Reconstructr Surg* 2006; **22**: 243-7.
10. MacEwen CJ, Young JDH. The fluorescein disappearance test (FDT): An evaluation of its use in infants. *J Pediatr Ophthalmol Strabismus* 1991; **28**:302-5.
11. Paul TO, Shepard R. Congenital nasolacrimal duct obstruction: Natural history and the timing of optimal intervention. *J Pediatr Ophthalmol Strabismus* 1994: **31**:362-7.
12. Frick KD, Hariharan L, Repka MX. Cost of effectiveness of 2 approaches to managing nasolacrimal duct obstruction in infants; The importance of the spontaneous resolution rate. *Arch Ophthalmol* 2011; **129**:603.
13. Pediatric eye disease investigator group. Resolution of congenital nasolacrimal duct obstruction with nonsurgical management. *Arch Ophthalmol* 2012; **130**:730.
14. Resolution of congenital nasolacrimal duct obstruction with nonsurgical management. *Arch Ophthalmol* 2012; **130**: 730-4.
15. Takahashi Y, Kakizaki H, Chan WO. Management of congenital nasolacrimal duct obstruction. *Act Ophthalmol* 2009; 21.
16. Nelson LB, Calhoun JH, Menduke H. Medical management of congenital nasocrimal duct obstruction. *Ophthalmology* 1985; **92**:1187-90.
17. Miller AM, Chandler DL, Repka MX. Office probing for

treatment of nasolacrimal duct obstruction in infants. *J AAPOS.* 2014; **18**:26-30.

18. Ziai S, Gilberg SM, Mawn LA. Pathogenesis of lacrimal canaliculiar laceration Jordan *Ophthal Plast Reconstructr Sur* 2008; **24**:394-8.
19. Repka MX, Chandlaer DI, Holms JM. Paediatric eye disease investigator group. Balloon catheter dilatation and nasolcrimal duct intubation for treatment of nasolacrimal duct obstruction after failed probing. *Arch Ophthalmol* 2009; **127**:633-9.