

# Tuberculosis and Crohn's Disease Revisited

Ibrahim Koral Onal<sup>1</sup>, Murat Kekilli<sup>2</sup>, Alpaslan Tanoglu<sup>3</sup>, Harun Erdal<sup>1</sup>, Mehmet Ibis<sup>1</sup> and Mehmet Arhan<sup>1</sup>

## ABSTRACT

Crohn's Disease (CD) and Intestinal Tuberculosis (ITB) share confusingly similar clinical, endoscopic, radiological and pathological manifestations. There is no simple test for differentiating ITB from CD. Although there are a number of sensitive and specific parameters for distinguishing between CD and ITB, the differential diagnosis still remains challenging and both clinical suspicion and appropriate clinical and laboratory studies are required to establish the diagnosis. Correct diagnosis is crucial because the therapy strategies of the two diseases are dramatically different. Treatment of ITB with immunosuppressive agents would lead to worsening of the patients' condition. Likewise, unnecessary antituberculosis therapy would delay the treatment of CD. Another important consideration is the risk of reactivation TB in patients with inflammatory bowel diseases which has been significantly increased following the widespread use of anti-Tumor Necrosis Factor Alpha (TNF- $\alpha$ ) therapy. The majority of reactivation cases are extrapulmonary or disseminated TB. And it is widely recommended that patients with IBD who are to receive TNF inhibitor therapy should be screened for evidence of latent TB. This paper mainly reviews current literature on differential diagnosis between CD and ITB, and summarizes strategies to reduce the TB risk among candidates for TNF antagonist therapy in this specific patient population.

**Key Words:** Crohn's disease. Humanized monoclonal antibodies. Interferon gamma release tests. Latent tuberculosis. Ulcerative colitis.

## INTRODUCTION

Inflammatory Bowel Disease (IBD) comprises Crohn's Disease (CD) and Ulcerative Colitis (UC), both disorders of unknown etiology are characterized by chronic or relapsing immune activation and inflammation within the Gastrointestinal (GI) tract. The two major forms of IBD share many clinical and epidemiologic characteristics, suggesting that underlying causes may be similar. The incidence and prevalence of IBD are highest in westernized nations.<sup>1-3</sup> Although there are few epidemiologic data from developing countries, the incidence and prevalence of IBD are increasing with time and in different regions around the World.<sup>3</sup>

Tuberculosis (TB) is one of the most expanded and the most lethal diseases in human history. One-third of the world's population are infected with TB. Although the rate of new TB cases and TB mortality rate had been significantly reduced since 1990, the level of active TB disease in the community is still high and the number of

TB deaths is unacceptably large given that most are preventable.<sup>4</sup> The African and European regions and half of the high-burden-countries are currently not on track to achieve the mortality and prevalence targets.<sup>4</sup>

Considering the fact that IBD and TB remain global health problems it is not unusual to encounter the coexistence of these two disease entities. And the risk of reactivation of tuberculosis has been significantly increased following the widespread use of anti-Tumor Necrosis Factor Alpha (TNF- $\alpha$ ) therapy,<sup>5,6</sup> currently the most potent treatment to achieve clinical remission and mucosal healing in patients with IBD.<sup>7</sup> Another important consideration is the differential diagnosis between two entities. TB can have various clinical presentations<sup>8,9</sup> and it can involve any organ system in the body including gastrointestinal (GI) tract.<sup>10</sup> Differentiating CD from Intestinal TB (ITB) often challenges clinicians and correct diagnosis is crucial because the therapy strategies of the two diseases are entirely different. Treatment of ITB with immunosuppressive agents would lead to worsening of the patients' condition. Likewise, unnecessary antituberculosis therapy would delay the treatment of CD.

This paper mainly reviews current literature on differential diagnosis between CD and ITB, and summarizes strategies to reduce the TB risk among candidates for TNF antagonist therapy in this specific patient population.

**Differentiation between CD and ITB:** Current clinical research demonstrates that CD and ITB share confusingly similar clinical, endoscopic, and pathological manifestations so much that it becomes difficult to differentiate between them. The rate of misdiagnosis

<sup>1</sup> Department of Gastroenterology, Gazi University Medical School, 06560 Ankara, Turkey.

<sup>2</sup> Department of Gastroenterology, Ankara Education and Research Hospital, 06340 Ankara, Turkey.

<sup>3</sup> Department of Gastroenterology, Gulhane Military Medical Academy, Haydarpasa Training Hospital, 34668 Uskudar, Turkey.

Correspondence: Dr. Ibrahim Koral Onal, Associate Professor of Gastroenterology, Department of Gastroenterology, Gazi University Medical School, Gazi Universitesi Hastanesi, Besevler, 06560 Ankara, Turkey.

E-mail: koralonal@yahoo.com

Received: October 11, 2014; Accepted: May 13, 2015.

between the two reaches 50% - 70% in some series.<sup>11,12</sup> Up to now, there is still no simple test for differentiating ITB from CD.<sup>13</sup> Although there are a number of sensitive and specific parameters for distinguishing between CD and ITB, the differential diagnosis still remains challenging and both clinical suspicion and appropriate clinical and laboratory studies are required to establish the correct diagnosis.<sup>13</sup> Herein the authors summarize the features in differentiating CD from ITB with respect to each diagnostic parameter and then present diagnostic models developed by a combination of various distinguishing features.

**Clinical features:** The duration of symptoms of CD is generally more than 9 months and longer than that of ITB.<sup>13-15</sup> A previous history of surgery including appendectomy is in favor of CD.<sup>13</sup> Constitutional symptoms such as fever and weight loss are common in both diseases. Night sweat was more frequently reported in patients with ITB than in patients with CD.<sup>10,13</sup> Abdominal pain and a change in bowel habits are observed in both CD and ITB but constipation is more common in ITB<sup>13,14</sup> while diarrhea<sup>13,14</sup> and hematochezia are more commonly seen in CD.<sup>10,13</sup> Patients with CD are more likely to have fistula<sup>10</sup> and perianal disease.<sup>13,14</sup> Extra-intestinal manifestations are more common in patients with CD<sup>13,14</sup> but they can also be seen in a third of patients with ITB.<sup>15</sup>

**Endoscopy:** Endoscopic features of ITB are similar to CD; both may have ulcerations, pseudopolyps, luminal narrowing and strictures.<sup>14</sup> Although a fixed-open ileocecal valve is more characteristic of ITB<sup>10,13</sup> the ileocecal region is the most common site affected in either condition, and colonoscopy with retrograde intubation of the ileum is the essential procedure. Isolated involvement of the ileo-cecal region is not typical for CD and inflammation of the terminal ileum usually coexists. As in CD, ITB may involve any part of GI tract but proximal GI tract and distal colonic segments are more commonly affected in CD. In recent comparative studies, rectum,<sup>13,14</sup> sigmoid colon,<sup>13,14</sup> and jejunum<sup>14</sup> were more commonly involved in patients with CD than in patients with ITB. The type of ulceration could also be helpful in distinguishing between these two diseases. Aphthous<sup>13,14,16</sup> or longitudinal<sup>14</sup> ulcerations and cobblestoning of the mucosa<sup>10,13,14,16</sup> support the diagnosis of CD while transverse ulcers,<sup>10,13,16</sup> nodularity<sup>11,13</sup> and hypertrophic lesions resembling masses<sup>11,13,16</sup> are more characteristic of ITB.

**Radiology:** Barium studies and Computed Tomography (CT) can provide diagnostic clues to the correct diagnosis apart from the above-mentioned differences in distribution of disease and type of ulceration. Barium studies demonstrate short and concentric strictures with prestenotic dilatation in ITB but long and eccentric strictures in CD.<sup>17</sup> And the proximal bowel above the

inflamed and strictured segment may not be dilated in CD if there is no coexistent fibrosis. Cobblestoning, perforation and fistula are more characteristic of CD. CT can identify changes in the bowel wall and mesentery which could provide additional discriminating features for the identification of intestinal TB from Crohn's disease.<sup>18</sup> Mural thickening and lymphadenopathy are commonly seen in both diseases but CD has a wall thickening with stratification (i.e., visualization of two or three layers of the bowel wall) while exophytic soft tissue masses and larger lymph nodes (> 1.5 cm) with central necrosis are suggestive of ITB.<sup>18</sup> Some mesenteric thickening occurs in ITB but intense hypervascularity of the mesentery described as the "comb sign" is seen only in CD.<sup>18,19</sup>

**Blood tests:** The following are laboratory abnormalities common to both conditions: anemia, thrombocytosis, leucocytosis, hypoalbuminemia, raised erythrocyte sedimentation rate and C-reactive protein. Since the late 1980s, anti-*Saccharomyces cerevisiae* antibody (ASCA) has been recognized as a specific serologic marker of CD and it has been suggested as a potential marker to differentiate possible IBD cases.<sup>20-22</sup> ASCA positivity was 7% in patients with ITB vs 49% in patients with CD in one series,<sup>22</sup> but this result was not confirmed by other studies which showed that almost half of the patients with ITB were ASCA-positive.<sup>23,24</sup>

Interferon Gamma Release Assays (IGRA) are based on the principle that the T cells of individuals exposed to *Mycobacterium tuberculosis* (MTB) will produce Interferon gamma (IFN $\gamma$ ) when they are re-challenged with mycobacterial antigens contained within the test kit.<sup>25</sup> There are two commercial blood based assays, the QuantiFERON-TB Gold (QFT) in tube (Cellestis Limited, Carnegie, Australia) and T-SPOT.TB (Oxford Immunotec, Oxford, UK).<sup>25</sup> These tests have originally been introduced for the diagnosis of latent TB infection but Kim *et al.* evaluated the clinical utility of IGRA in the differential diagnosis of ITB and CD.<sup>26</sup> In this study the diagnostic validity of QFT in ITB had a 67% sensitivity, 90% specificity, 87% positive predictive value, and 73% negative predictive value.<sup>26</sup> There was no difference in these parameters between the QFT and tuberculin skin test (TST). But the likelihood ratio for a positive QFT was higher than a positive TST in the diagnosis of ITB (7.1 and 4.4, respectively). The authors concluded that the QFT may have a supplementary role in the differential diagnosis between ITB and CD.<sup>26</sup> Li *et al.* reported that T-SPOT.TB (Hazard ratio 7.0, 95%CI: 1.9 - 25.7) was a good predictor for ITB diagnosis.<sup>27</sup> The sensitivity, specificity, positive predictive value, negative predictive value of T-SPOT.TB were 84.2%, 75.4%, 50.0%, and 94.2% respectively.<sup>27</sup> The results of some other studies were compatible with these findings.<sup>10,13</sup>

**Microbiology:** Definitive diagnosis of ITB is made by identification of the organism in tissue by direct

visualization with an acid-fast stain, by culture of resected tissue, or by a Polymerase Chain Reaction (PCR) assay. But it is still challenging to diagnose ITB because of limitations of these tests. Acid-Fast Bacilli (AFB) stained by Ziehl-Neelsen are present in less than 30% of cases.<sup>28</sup> The biopsy culture for MTB is time consuming (3 - 8 weeks are required for positive culture) and the accuracy of the results ranges from 25% to 35%.<sup>29</sup> TB PCR analysis of endoscopic biopsy specimens or surgical specimens can provide a rapid diagnosis within 3 days.<sup>30</sup> PCR assay has a specificity of up to 95%<sup>31</sup> and an accuracy of 82.6%<sup>29</sup> for diagnosing ITB. But this technique needs to be improved for better sensitivity. PCR analysis of fecal samples of patients with ITB has been useful in small studies,<sup>32</sup> but need validation in larger numbers of patients.

**Histopathology:** Both ITB and CD are granulomatous disorders but differences in the appearance of the granulomas and some other histological features can help distinguish between these two conditions.<sup>14</sup> The granulomas in patients with ITB are significantly larger and tend to be more confluent than in those with CD.<sup>14,16,33,34</sup> In ITB there is a higher number of granulomas per section and granulomas are more frequently located in the submucosa or in granulation tissue.<sup>14,16</sup> Features that favor a diagnosis of CD on

mucosal biopsies include infrequent (< 5), small (< 200 µm in size) granulomas that are poorly organized and discrete or isolated.<sup>17</sup> The presence of focally enhanced colitis supports the diagnosis of CD whereas caseation necrosis should make one think about ITB.<sup>14,16</sup> The above is summarized in Table I.

**Others:** Anti-TB medication trial was frequently used to diagnose TB<sup>8</sup> and to differentiate between ITB and CD<sup>12</sup> in countries with a high prevalence of TB. But every effort is strongly recommended to reach to a diagnosis before starting empirical treatment because of potential side effects of anti-TB drugs and a risk of delay in the diagnosis of CD. Although laparoscopy can be helpful in diagnosing peritoneal TB, it has almost no role in ITB because isolated involvement areas of the small bowel can be reached and biopsied by the availability of single- and double-balloon enteroscopy. Regarding the evaluation of mucosal biopsies several novel immunohistochemical markers have been suggested to aid in the differential diagnosis of ITB and CD. Syndecan-1 (SDC1) and its endo-beta-D-glucuronidase Heparanase (HPA) are implicated in the maintenance of intestinal barrier function. Zhang *et al.* showed that SDC1 was significantly decreased in mucosa and increased in serum, whereas HPA level in both were elevated in patients with CD.<sup>35</sup> Such alterations were

**Table I:** Differential diagnosis between intestinal tuberculosis and Crohn's disease.

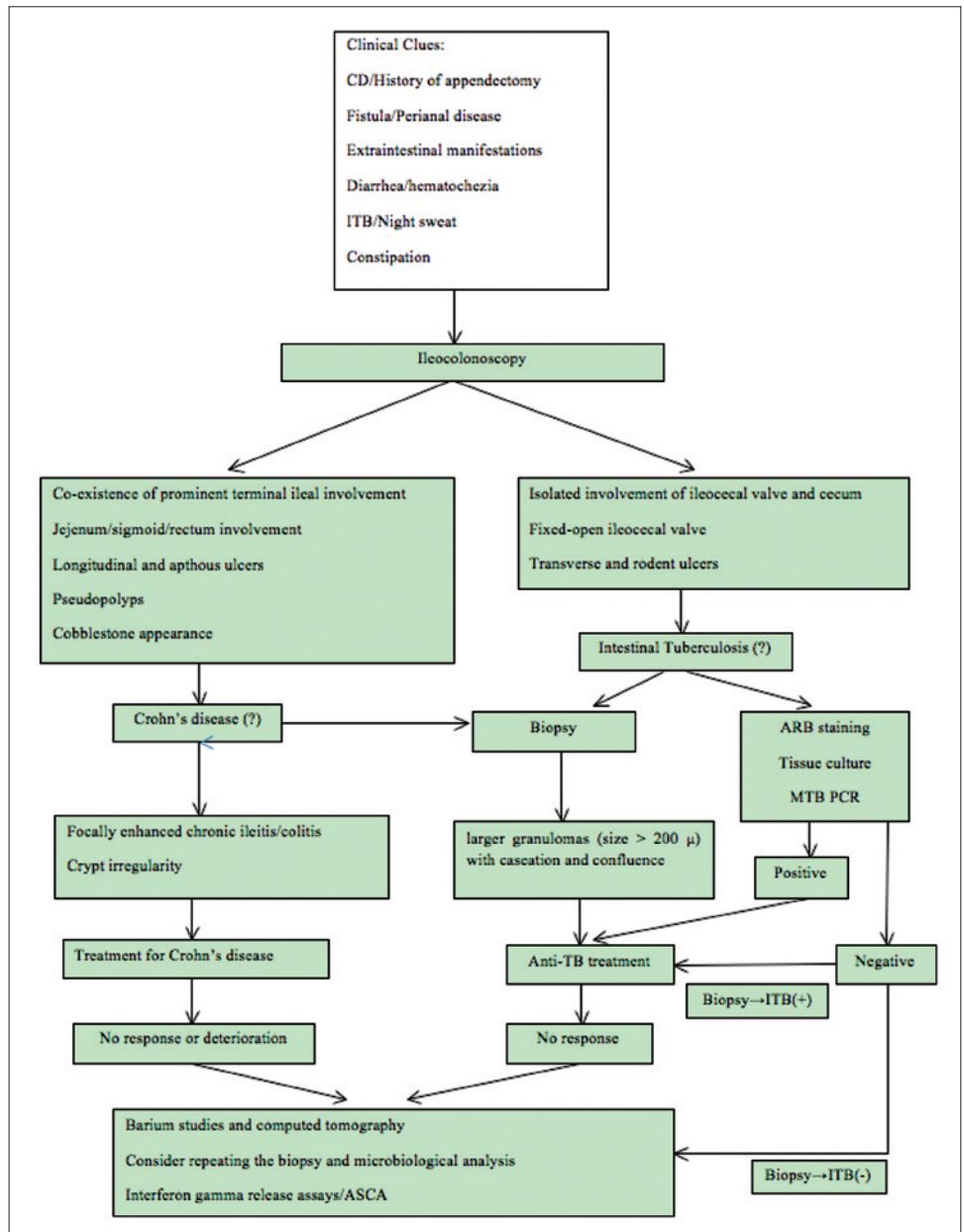
Variable	Intestinal tuberculosis	Crohn's disease
Patient's characteristics and clinical symptoms	Night sweat Constipation	Longer disease duration History of appendectomy Diarrhea Hematochezia Fistula Perianal disease Extra-intestinal manifestations
The site of involvement	Isolated involvement of ileo-cecal area without terminal ileitis Patulous ileocecal valve Involvement of less than four segments	Jejunum Sigmoid colon Rectum Anorectal lesions
Endoscopy	Transverse ulcers Nodularity Hypertrophic lesions resembling masses	Longitudinal ulcers Longitudinal ulcers Aphthous ulcers Cobble-stoning of the mucosa
Radiology	Short and concentric strictures with prestenotic dilatation Exophytic soft tissue masses and larger lymph nodes with central necrosis	Wall thickening with stratification Cobble-stoning Perforation Fistula Intense hypervascularity in the adjacent mesentery
Blood tests	IGRA positivity	ASCA positivity
Histopathology	Granulomas Larger More confluent Submucosal Higher number Caseation necrosis	Focally enhanced colitis

Various features that are more commonly observed in one of these two disease entities. Relevant references are mentioned in the text. ASCA = Anti-Saccharomyces cerevisiae antibody; IGRA = Interferon gamma release assays.

associated with clinicopathological features representing disease activity and injury severity and were not available in functional bowel disorder and ITB groups.<sup>35</sup> In another study immunohistochemical staining of biopsy specimens with anti-VP-M660-targeting the 38-kDa antigen of *Mycobacterium tuberculosis* was found to have 73% sensitivity and 93% specificity for establishing an earlier differentiation of TB from CD.<sup>36</sup> Further studies are needed to confirm the relevant findings.<sup>35,36</sup>

**Diagnostic models:** Several diagnostic models were developed by a combination of various distinguishing features mentioned above. Makharia *et al.* calculated a score by using the following parameters: weight loss as a predictor of ITB and focally enhanced colitis, involvement of sigmoid colon and blood in stool as predictors of CD.<sup>14</sup> The overall discriminating ability of this model was 89.2%.<sup>14</sup> Lee *et al.* reported that their diagnosis was correct in 87.5% of patients when the diagnosis was made on the basis of four features, namely anorectal lesions, longitudinal ulcers, aphthous ulcers and cobble-stoning for CD and involvement of less than four segments, patulous ileocecal valve, transverse ulcers, and pseudopolyps for ITB.<sup>16</sup> Yu *et al.* included night sweats and granuloma for ITB and longitudinal ulcers for CD in their final equation and they could correctly discriminate 86% of the total subjects.<sup>10</sup> Li *et al.* suggested that various endoscopic features can be helpful in the differential diagnosis of CD and ITB.<sup>13</sup> They included several endoscopic features in their model: rectum involved lesions, longitudinal ulcer and cobble-stone appearance for CD while fixed-open ileocecal valve, transverse ulcer, and rodent ulcer for ITB.<sup>13</sup> The accuracy of their equation was 82.5%. An algorithm is proposed for the differential diagnosis between ITB and CD in Figure 1. Regarding all these diagnostic models further multi-center validation studies with large samples sizes are required.

**Tuberculosis in anti-TNF alpha treated patients:** TNF plays a critical role in the host response to infection and it is essential for granuloma formation that is responsible for sequestration of MTB.<sup>37</sup> Therefore, drugs that inhibit TNF activity may interfere with the ability to maintain someone who has latent TB. Anti-TNF- $\alpha$  therapy is associated with a 5-fold increased risk of reactivation in the first 52 weeks after initiation of therapy.<sup>5,38</sup> The majority of reactivation cases are extrapulmonary or disseminated TB.<sup>39-41</sup> Given the significant morbidity and mortality associated with TB reactivation, it is widely recommended that patients with IBD who are to receive TNF inhibitor therapy should be screened for evidence of latent TB.<sup>40,41</sup> Screening led to significant reductions



**Figure 1:** proposed algorithm for the differential diagnosis between Crohn's disease and intestinal tuberculosis. ITB: Intestinal tuberculosis; ASCA: Anti-Saccharomyces cerevisiae antibody; MTB: *Mycobacterium tuberculosis*; PCR: Polymerase chain reaction.

in the incidence of TB reactivation in the setting of TNF inhibitor therapy<sup>40-42</sup> although several patients were reported to develop TB despite initial negative latent TB screening.<sup>6</sup> In fact reactivation TB can still be observed in a group of patients with IBD on anti-TNF- $\alpha$  therapy despite chemoprophylaxis.<sup>43</sup>

A number of national guidelines have been generated to deal with latent infection with MTB before treatment with TNF antagonists;<sup>42,44-46</sup> but there is still no global consensus in many aspects of screening such as the use and interpretation of TST, IGRA and the indications for preventive treatment.

TST has a poor specificity and it is inadequate to assess evidence of latent infection with MTB in BCG-vaccinated patients and patients with low pre-test risk of TB infection. IGRAs have increased sensitivity and specificity and indeterminate results are less frequent.<sup>47</sup> They are also strongly correlated with risk factors for TB.<sup>47,48</sup> On the other hand, further longitudinal studies are needed to estimate the risk for progression to TB after IGRA-based diagnosis of latent infection with MTB in patients undergoing therapy with TNF antagonists.

National guidelines agree that every patient considered for TNF antagonist therapy should be screened for evidence of active and latent TB infection.<sup>48</sup> A chest radiograph should be obtained together with either a tuberculin skin test or an IGRA.<sup>48</sup> Preventive chemotherapy should be administered in case of a history of past exposure or untreated TB even when tests for latent infection are negative. Preventive chemotherapy regimens vary and include 6 or 9 months with isoniazid, 3 months of rifampicin plus isoniazid, and 4 months of rifampicin.<sup>48</sup> There is no consensus on the minimum duration of preventive chemotherapy before initiating TNF antagonist. Three weeks may be sufficient whereas some authors recommend that preventive chemotherapy should be completed before the first dose of TNF antagonist.<sup>48</sup>

## CONCLUSION

It is of great importance to differentiate between CD and ITB. Although various clinical, endoscopic, radiological, and histological features may aid in the differential diagnosis the most important point is having a high index of clinical and endoscopic suspicion in the high risk population in a proper geographical context. In this review, a diagnostic algorithm was proposed based on selective valuable parameters. A concerning common adverse event of TNF antagonist therapies is the reactivation of latent infection with MTB. TB screening and preventive chemotherapy for all individuals with latent infection with MTB should become the standard of care for all individuals undergoing TNF antagonist therapies.

## REFERENCES

- Spencer RJ. Etiology and epidemiology of ulcerative colitis. *Can J Surg* 1974; **17**:414-5.
- Edwards CN, Griffith SG, Hennis AJ, Hambleton IR. Inflammatory bowel disease: incidence, prevalence, and disease characteristics in Barbados, West Indies. *Inflamm Bowel Dis* 2008; **14**:1419-24.
- Molodecky NA, Soon IS, Rabi DM, Ghali WA, Ferris M, Chernoff G, *et al.* Increasing incidence and prevalence of the inflammatory bowel diseases with time, based on systematic review. *Gastroenterology* 2012; **142**:46-54.
- WHO. Global tuberculosis report 2013. Geneva: *World Health Organization*; 2013
- Gómez-Reino JJ, Carmona L, Valverde VR, Mola EM, Montero MD. Treatment of rheumatoid arthritis with tumor necrosis factor inhibitors may predispose to significant increase in tuberculosis risk: a multicenter active-surveillance report. *Arthritis Rheum* 2003; **48**:2122-7.
- Jauregui-Amezaga A, Turon F, Ordás I, Gallego M, Feu F, Ricart E, *et al.* Risk of developing tuberculosis under anti-TNF treatment despite latent infection screening. *J Crohns Colitis* 2013; **7**:208-12.
- van Assche G, Vermeire S, Rutgeerts P. Mucosal healing and anti-TNFs in IBD. *Curr Drug Targets* 2010; **11**:227-33.
- Onal IK, Cankurtaran M, Cakar M, Halil M, Ulger Z, Dogu BB, *et al.* Fever of unknown origin: what is remarkable in the elderly in a developing country? *J Infect* 2006; **52**:399-404.
- Onal IK, Ersoy O, Aydinli M, Yonem O, Harmanci O, Sokmensuer C, *et al.* Hepatic granuloma in Turkish adults: a report of 13 cases. *Eur J Intern Med* 2008; **19**:527-30.
- Yu H, Liu Y, Wang Y, Peng L, Li A, Zhang Y. Clinical, endoscopic and histological differentiations between Crohn's disease and intestinal tuberculosis. *Digestion* 2012; **85**:202-9.
- Epstein D, Watermeyer G, Kirsch R. Review article: the diagnosis and management of Crohn's disease in populations with high-risk rates for tuberculosis. *Aliment Pharmacol Ther* 2007; **25**:1373-88.
- Jayanthi V, Robinson RJ, Malathi S, Rani B, Balambal R, Chari S, *et al.* Does Crohn's disease need differentiation from tuberculosis? *J Gastroenterol Hepatol* 1996; **11**:183-6.
- Li X, Liu X, Zou Y, Ouyang C, Wu X, Zhou M, *et al.* Predictors of clinical and endoscopic findings in differentiating Crohn's disease from intestinal tuberculosis. *Dig Dis Sci* 2011; **56**:188-96.
- Makharia GK, Srivastava S, Das P, Goswami P, Singh U, Tripathi M, *et al.* Clinical, endoscopic, and histological differentiations between Crohn's disease and intestinal tuberculosis. *Am J Gastroenterol* 2010; **105**:642-51.
- Hou JK, El-Serag H, Thirumurthi S. Distribution and manifestations of inflammatory bowel disease in Asians, Hispanics, and African Americans: a systematic review. *Am J Gastroenterol* 2009; **104**:2100-9.
- Lee YJ, Yang SK, Byeon JS, Myung SJ, Chang HS, Hong SS, *et al.* Analysis of colonoscopic findings in the differential diagnosis between intestinal tuberculosis and Crohn's disease. *Endoscopy* 2006; **38**:592-7.
- Pulimood AB, Amarapurkar DN, Ghoshal U, Phillip M, Pai CG, Reddy DN, *et al.* Differentiation of Crohn's disease from

- intestinal tuberculosis in India in 2010. *World J Gastroenterol* 2011; **17**:433-43.
18. Makanjuola D. Is it Crohn's disease or intestinal tuberculosis? CT analysis. *Eur J Radiol* 1998; **28**:55-61.
  19. Meyers MA, McGuire PV. Spiral CT demonstration of hypervascularity in Crohn's disease: "vascular jejunization of the ileum" or the "comb sign". *Abdom Imaging* 2000; **20**:327-32.
  20. Main J, McKenzie H, Yeaman GR, Kerr MA, Robson D, Pennington CR, et al. Antibody to *Saccharomyces cerevisiae* (bakers' yeast) in Crohn's disease. *BMJ* 1988; **297**:1105-6.
  21. Ruemmele FM, Targan SR, Levy G, Dubinsky M, Braun J, Seidman EG. Diagnostic accuracy of serological assays in pediatric inflammatory bowel disease. *Gastroenterology* 1998; **115**:822-9.
  22. Kim BG, Kim YS, Kim JS, Jung HC, Song IS. Diagnostic role of anti-*Saccharomyces cerevisiae* mannan antibodies combined with anti-neutrophil cytoplasmic antibodies in patients with inflammatory bowel disease. *Dis Colon Rectum* 2002; **45**:1062-9.
  23. Ghoshal UC, Ghoshal U, Singh H, Tiwari S. Anti-*Saccharomyces cerevisiae* antibody is not useful to differentiate between Crohn's disease and intestinal tuberculosis in India. *J Postgrad Med* 2007; **53**:166-70.
  24. Makharria GK, Sachdev V, Gupta R, Lal S, Pandey RM. Anti-*Saccharomyces cerevisiae* antibody does not differentiate between Crohn's disease and intestinal tuberculosis. *Dig Dis Sci* 2007; **52**:33-9.
  25. Centers for disease control, prevention. Interferon-gamma release assays (IGRAs) - blood tests for TB infection (fact sheet) [Internet]. 2012-01-02, Available from: <http://www.cdc.gov/tb/publications/factsheets/testing/IGRA.pdf>
  26. Kim BJ, Choi YS, Jang BI, Park YS, Kim WH, Kim YS, et al. Prospective evaluation of the clinical utility of interferon- $\gamma$  assay in the differential diagnosis of intestinal tuberculosis and Crohn's disease. *Inflamm Bowel Dis* 2011; **17**:1308-13.
  27. Li Y, Zhang LF, Liu XQ, Wang L, Wang X. The role of *in vitro* interferon- $\gamma$ -release assay in differentiating intestinal tuberculosis from Crohn's disease in China. *J Crohns Colitis* 2012; **6**:317-23.
  28. Dilauro S, Crum-Cianflone NF. Ileitis: when it is not Crohn's disease. *Curr Gastroenterol Rep* 2010; **12**:249-58.
  29. Amarapurkar DN, Patel ND, Rane PS. Diagnosis of Crohn's disease in India where tuberculosis is widely prevalent. *World J Gastroenterol* 2008; **14**:741-6.
  30. Li JY, Lo ST, Ng CS. Molecular detection of *Mycobacterium tuberculosis* in tissues showing granulomatous inflammation without demonstrable acid-fast bacilli. *Diagn Mol Pathol* 2000; **9**:67-74.
  31. Amarapurkar DN, Patel ND, Amarapurkar AD, Agal S, Baigal R, Gupte P. Tissue polymerase chain reaction in diagnosis of intestinal tuberculosis and Crohn's disease. *J Assoc Physicians India* 2004; **52**:863-7.
  32. Balamurugan R, Venkataraman S, John KR, Ramakrishna BS. PCR amplification of the IS6110 insertion element of *Mycobacterium tuberculosis* in fecal samples from patients with intestinal tuberculosis. *J Clin Microbiol* 2006; **44**:1884-6.
  33. Pulimood AB, Peter S, Ramakrishna B, Chacko A, Jeyamani R, Jeyaseelan L, et al. Segmental colonoscopic biopsies in the differentiation of ileocolic tuberculosis from Crohn's disease. *J Gastroenterol Hepatol* 2005; **20**:688-96.
  34. Pulimood AB, Ramakrishna BS, Kurian G, Peter S, Patra S, Mathan VI, et al. Endoscopic mucosal biopsies are useful in distinguishing granulomatous colitis due to Crohn's disease from tuberculosis. *Gut* 1999; **45**:537-41.
  35. Zhang S, Qing Q, Wang Q, Xu J, Zhi F, Park PW, et al. Syndecan-1 and heparanase: potential markers for activity evaluation and differential diagnosis of Crohn's disease. *Inflamm Bowel Dis* 2013; **19**:1025-33.
  36. Ince AT, Günes P, Senates E, Sezikli M, Tiftikçi A, Ovünç O. Can an immunohistochemistry method differentiate intestinal tuberculosis from Crohn's disease in biopsy specimens? *Dig Dis Sci* 2011; **56**:1165-70.
  37. Kindler V, Sappino AP, Grau GE, Piguet PF, Vassalli P. The inducing role of tumor necrosis factor in the development of bactericidal granulomas during BCG infection. *Cell* 1989; **56**:731-40.
  38. Afif W, Loftus EV. Safety profile of IBD therapeutics: infectious risks. *Med Clin North Am* 2010; **94**:115-33.
  39. Raval A, Akhavan-Toyserkani G, Brinker A, Avigan M. Brief communication: characteristics of spontaneous cases of tuberculosis associated with infliximab. *Ann Intern Med* 2007; **147**:699-702.
  40. Targownik LE, Bernstein CN. Infectious and malignant complications of TNF inhibitor therapy in IBD. *Am J Gastroenterol* 2013; **108**:1835-42.
  41. Dave M, Purohit T, Razonable R, Loftus EV Jr. Opportunistic infections due to inflammatory bowel disease therapy. *Inflamm Bowel Dis* 2014; **20**:196-212.
  42. Carmona L, Gómez-Reino JJ, Rodríguez-Valverde V, Montero D, Pascual-Gómez E, Mola EM, et al. Effectiveness of recommendations to prevent reactivation of latent tuberculosis infection in patients treated with tumor necrosis factor antagonists. *Arthritis Rheum* 2005; **52**:1766-72.
  43. Sighetlidis L, Settas L, Spyrtatos D, Chloros D, Patakas D. Tuberculosis in patients receiving anti-TNF agents despite chemoprophylaxis. *Int J Tuberc Lung Dis* 2006; **10**:1127-32.
  44. British Thoracic Society Standards of Care Committee. BTS recommendations for assessing risk and for managing *Mycobacterium tuberculosis* infection and disease in patients due to start anti-TNF-alpha treatment. *Thorax* 2005; **60**:800-5.
  45. Mariette X, Salmon D. French guidelines for diagnosis and treating latent and active tuberculosis in patients with RA treated with TNF blockers. *Ann Rheum Dis* 2003; **62**:791.
  46. Valesini G, Montecucco C, Cutolo M. Recommendations for the use of biologic (TNF-alpha blocking) agents in the treatment of rheumatoid arthritis in Italy. *Clin Exp Rheumatol* 2006; **24**:413-23.
  47. Mariette X, Baron G, Tubach F, Lioté F, Combe B, Miceli-Richard C, et al. Influence of replacing tuberculin skin test with *ex vivo* interferon  $\gamma$  release assays on decision to administer prophylactic antituberculosis antibiotics before anti-TNF therapy. *Ann Rheum Dis* 2012; **71**:1783-90.
  48. Solovic I, Sester M, Gomez-Reino JJ, Rieder HL, Ehlers S, Milburn HJ, et al. The risk of tuberculosis related to tumour necrosis factor antagonist therapies: a TBNET consensus statement. *Eur Respir J* 2010; **36**:1185-206.

