CASE REPORT

Orf with Unusual Features

Moizza Tahir[1], Nasser Rashid Dar[1], Jauhar Mumtaz[2], Irfan Anwar[1] and Sajid Mustafvi[3]

Abstract

We describe a case of Orf in an immunocompetent man with no history of direct contact with farm animals. The patient presented with numerous large lesions on hands and feet including a lesion in the subungual area. Later on multiple lesions with more bizarre morphology developed on the trunk. The diagnosis was suspected on clinical appearance of the lesion and confirmed later by histopathology. We consider contact with contaminated soil as the possible source of infection as virus can survive in pastures. Awareness of unusual clinical patterns of known entities is important to avoid unnecessary interventions.

Key Words: *Orf. Subungual Orf. Disseminated Orf.*

INTRODUCTION

Orf, also known as ecthyma contagiosum, is caused by *Parapoxvirus*. It is a zoonotic disease that causes sore mouth in animals and orf in humans. Transmission from cats has also been described.[1] The virus can survive on farm material and ground for months to years. The clinical picture is usually of a solitary lesion that heals in 4 - 6 weeks. Multiple and disseminated lesions are rarely seen.[2] Clinical signs are typical, though electron microscopy, histology and PCR are the most accurate laboratory approach for confirmation of the disease.[3]

We report a case with numerous large and atypical lesions with possibility of viremia or autoinoculation.

CASE REPORT

A 58 years old male reported in dermatology OPD for multiple erythematous lesions on hands and feet for 3 weeks. Three lesions initially appeared on the dorsum of left hand at the base of ring finger, over dorsum of left little finger and right ankle (Figure 1). Few days later, he noticed similar lesion in the subungual region of left ring finger (Figure 2), palmar aspect of the right index finger, dorsal aspect of the right hand and a verrucous lesion on the extensor surface of left arm. Patient did not have fever, malaise or arthralgia. He denied any history of local trauma, farming or contact with animals. He was a civil engineer by occupation and was recently working on a field project at a high way where he had to frequently come in contact with soil. His past history for any dermatological disease and medical illness or drug intake was unremarkable.

On examination, individual lesion was an erythematous nodule surmounted by a flat topped hemorrhagic pustule with a central crust which was surrounded by an erythematous zone. They ranged in size from 2 to 4 centimeter. Regional lymph nodes were not enlarged. Rest of the cutaneous and systemic examination was unremarkable. On the basis of the morphology of the lesion, a provisional diagnosis of orf was made keeping cowpox, anthrax, tularemia, primary inoculation tuberculosis, atypical mycobacteria infection and sporotrichosis as differentials. Histopathology of a skin biopsy specimen showed necrosis of the superficial layers of epidermis along with eosinophilic cytoplasmic inclusions of keratinocytes and epidermal cell vacuolation. There was an infiltration of lymphocytes, macrophages

Figure 1: Lesion on hand and foot.

Figure 2: Subungal lesion.

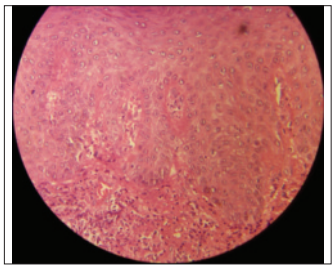

Figure 3: Mononuclear infiltrate in dermis 10 x Eosinophilic inclusion in epidermis 40x.

Figure 4: Giant lesion on hand (dorsal surface).

[1] *Department of Dermatology, Combined Military Hospital, Rawalpindi.*
[2] *Department of Dermatology, Combined Military Hospital, Abbottabad.*
[3] *Classified Medical Specialist, Combined Military Hospital, Rawalpindi.*

Correspondence: Maj. Dr. Moizza Tahir, Department of Dermatology, Combined Military Hospital, Rawalpindi.
E-mail: drmoizzatahir@yahoo.com

Received: January 01, 2013; Accepted: March 04, 2014.

and neutrophils in dermis and epidermis (Figure 3). These changes confirmed the diagnosis of Orf. Blood chemistries were normal and serology for HIV was negative.

The patient was explained the benign and self-limiting nature of the disease and was only prescribed topical antiseptics. Ten days later, he developed three discrete lesions on his back. The lesions on hands and feet became larger and bizarre before self-regression. Histology of the back lesion was similar to the earlier lesions. All the lesions gradually healed over next 6 weeks.

DISCUSSION

Diagnosis of orf is based on history of contact with animals or contaminated material on the background of clinically suspicious lesions. This case was unique as there was no history of animal contact or occupational exposure and contact with contaminated soil was the only possibility.

This patient had multiple large atypical and verrucous lesions. Giant and atypical lesions in immuno-compromised have been described.[4] Similar lesions may be seen in immunocompetent cases.[5] This patient developed second eruption of multiple lesions on the back, 3 - 4 weeks later. Bullous pemphigoid like lesions have been described following orf,[6] but the secondary eruption seen in this patient was of orf as confirmed by the histopathology of this patient. Recurrent eruptions have been described in immunocompromised hosts.[7] The possibility of viremia in immunocompromised patients is there but this patient was immunocompetent.[8] Blood PCR is required for its confirmation but this facility was not available with us. The possibility of autoinoculation can also be considered as a cause of this secondary lesion considering his subungual lesion.

This case of Orf presenting with multiple large and disseminated lesions resulted from contact with contaminated soil. The patient was immunocompetent and secondary dissemination was seen. To the best of authors' knowledge, subungual lesions in orf as seen in this patient have not been documented before.

Diagnosis of Orf should be considered in suspicious lesions even if there is no history of contact with animals. Widespread lesions on different exposed anatomical regions should bring the possibility of exposure to contaminated soil as transmission through contaminated non-living material has been described.[9] The lesions usually resolve completely in a month without any treatment.[10]

Awareness of unusual clinical patterns of known entities is important to avoid unnecessary interventions.

REFERENCES

1. Frandsen J, Enslow M, Bowen AR. Orf *parapoxvirus* infection from a cat scratch. *Dermatol Line J* 2011; **17**:9.
2. Sasmaz S, Uzel M, Sener S, Ucmak H. Rare presentation of human orf as multiple lesions. *J Dermatol* 2011; **38**:825-6.
3. Hosamani M, Scagliarini A, Bhanuprakash V, McInnes CJ, Singh RK. Orf: an update on current research and future perspectives. *Expert Rev Anti Infect Ther* 2009; **7**:879-93.
4. Stead JW, Henry CM, Simpson RH. Rare case of auto-inoculation of orf. *Br J Gen Pract* 1992; **42**:395-6.
5. Pether JV, Guerrier CJ, Jones SM. Giant orf in a normal individual. *Br J Dermatol* 1986; **115**:497-9.
6. White KP, Zedek DC, White WL, Simpson EL, Hester E, Morrison L, *et al.* Orf-induced immunobullous disease: a distinct autoimmune blistering disorder. *J Am Acad Dermatol* 2008; **58**:49-55. Epub 2007 Oct 4.
7. Ara M, Zaballos P, Sánchez, M, Querol I, Zubiri ML, Simal E, *et al.* Giant and recurrent orf virus infection in a renal transplant recipient treated with imiquimod. *J Am Acad Dermatol* 2008; **58**:S39-40.
8. DermNet NZ Trust. Website of New Zealand dermatological society incorporated [Internet]. [cited 2014 Feb 16]. Available from: http:// www.dermnetnz.org /viral/orf.html
9. Hawayek LH. Orf clinical presentation [Internet]. 2013. [cited2014 Feb 16]. Available from: http://emedicine.medscape.com/article/1133450-clinical#a0218
10. Steinhart B. Orf in humans: dramatic but benign. *CJEM* 2005; **7**:417-9.