

Facial Nerve Morbidity Following Surgery for Benign Parotid Tumours

Mohammad Ayub Musani¹, Abbas Zafar², Zahid Suhail¹, Shoukat Malik³ and Daud Mirza⁴

ABSTRACT

Objective: To determine the frequency and severity of facial nerve dysfunction following surgery for benign parotid gland tumours.

Study Design: A case series.

Place and Duration of Study: ENT Department, Karachi Medical and Dental College and Abbasi Shaheed Hospital and Ziauddin University Hospital, from 1990 to 2010.

Methodology: Data was collected of all patients who were surgically managed for benign parotid tumours from 1990 to 2010. Data was reviewed for presentation of tumour, age and gender of the patient, site of tumour, nature and morphology of the tumour, primary or recurrent, surgical procedure adopted and the complications of the surgery especially the facial nerve dysfunction, its severity, complete or partial paresis and transient or permanent and time of recovery. Results were described as frequency percentages.

Results: Out of 235 patients, 159 (67.65%) were female and 76 (32.35%) were male. Age ranged from 18 to 70 years. Pleomorphic adenoma was the most common tumour (n=194, 82.6%), followed by Warthin's tumour. Superficial parotidectomy was done in 188 cases and extended parotidectomy in 47 cases. In the immediate postoperative period facial nerve function was normal in 169 (72%) patients and nerve dysfunction was observed in 66 (28%) patients. Complete paresis involving all the branches of facial nerve was seen in 25 (10.6%) patients and 41 (17.4%) patients were having incomplete dysfunction. Of these, 62 (26.3%) recovered and 04 (1.7%) had permanent facial nerve dysfunction. Marginal mandibular branch of facial nerve was involved in 57 (86.3%) cases.

Conclusion: The frequency of temporary and permanent facial nerve dysfunction was 26.3% and 1.7% respectively in 235 consecutive parotidectomies for benign parotid gland tumours. Higher frequency of facial nerve dysfunction was found in recurrent and deep lobe tumours.

Key Words: Parotid gland tumours. Parotidectomy. Facial nerve dysfunction.

INTRODUCTION

Salivary gland tumours represent about 3% of all and 5% of head and neck tumours.¹ About 80% of these tumours arise in the parotid gland, 10% in the submandibular and remaining 10% are distributed in the sublingual and minor salivary glands.²

Parotid is the major salivary gland having the superficial and deep lobe with facial nerve running between the two lobes.³ The facial nerve after emerging from the stylomastoid foramen runs for a short distance before entering into the parotid gland at its posteromedial surface.⁴ In the parotid gland, the nerve divides into two major trunks; temporo-zygomatic and cervico-facial,

which in turn divide into terminal branches within the parotid gland.

Benign tumours are more common in parotid gland, making about 80% of all and 80% of these are pleomorphic adenoma, followed by Warthin's tumour and monomorphic adenoma.⁵ Superficial lobe is the main site where about 80% of tumours arise.⁶ Sudden increase in size, pain or facial palsy are ominous signs and signifies malignancy, tuberculosis or sarcoidosis.⁷

Treatment of choice for these benign parotid tumours is surgery; superficial parotidectomy for tumours arising from the superficial lobe and total parotidectomy with preservation of facial nerve for recurrent tumours and tumours arising from the deep lobe.⁸ As the facial nerve and its branches are in intimate relation with the parotid gland, its trauma is the major concern in parotid surgery.⁹ Its identification, protection and preservation is the key to successful parotid surgery.^{9,10}

The risk of facial nerve trauma during surgery increases for recurrent tumours and in total parotidectomy, where deep lobe is also removed. The most common complication of parotid surgery is facial nerve palsy, particularly of the marginal mandibular nerve.¹¹

¹ Department of ENT, Karachi Medical and Dental College, Karachi.

² Department of ENT, Ziauddin University Hospital, Karachi.

³ Department of ENT / Oral Pathology⁴, Bahria Medical University, Karachi.

Correspondence: Dr. Mohammad Ayub Musani, B-599, Block 13, F. B. Area, Karachi.

E-mail: ayubmusani@yahoo.com

Received: June 03, 2013; Accepted: May 06, 2014.

Transient nerve weakness following parotidectomy is not an uncommon event, however, recovery is expected in most cases within 6 months after surgery.⁹ The incidence of nerve palsy is higher in total parotidectomy than in superficial parotidectomy, which may be related to stretch injury or as a result of surgical trauma to *vasa nervosum*. Neuropraxia is reported in about 8 - 46% of benign parotid surgeries. Marginal mandibular nerve is the branch most commonly damaged during parotid surgeries.¹¹

The factors affecting the frequency of facial nerve trauma during surgery are surgical skill, method of identification of facial nerve and the use of facial nerve stimulator.

The aim of this study was to document the frequency and nature of facial nerve dysfunction following surgical treatment of benign parotid tumours in the setup.

METHODOLOGY

This study was carried out at the ENT Department of Karachi Medical and Dental College and Abbasi Shaheed Hospital and Ziauddin University Hospital, Karachi, from 1990 to 2010. Clinical data of all patients was collected who had undergone surgery for benign parotid gland tumours during this period and reviewed for site and morphological pattern, presentation, age and gender distribution, primary or recurrent, surgical procedure and complications, particularly the facial nerve dysfunction. Antegrade method was used for nerve identification in most of the cases except in some recurrent tumours and difficult cases, where retrograde method was used. Nerve stimulator was not used.

The nature/severity of facial nerve dysfunction was assessed in term of its nature, transient or permanent, complete or incomplete, branches involved and recovery. The average follow-up was two years.

Statistical Package for Social Sciences (SPSS) software version 15 was used for all data analysis. Frequency and percentages were given for proportion or categorical variables.

RESULTS

Out of 235 patients, 159 (67.65%) were female and 76 (32.35%) were male with female to male ratio of 2:1. Age ranged from 18 to 70 years with mean age of 34 years. Pleomorphic adenoma was the most common tumour, (194 cases 82.6%) followed by Warthin's tumour in 21 cases (8.9%, Figure 1). Out of 194 pleomorphic adenoma, 138 (71%) were found in female and 56 (29%) cases in male. Superficial lobe was the site of involvement in 191 (81%) and 44 (19%) cases were found to be arising from the deep lobe. Of these, 23 cases were recurrent tumours and 08 cases had anatomical variation of facial nerve. Superficial

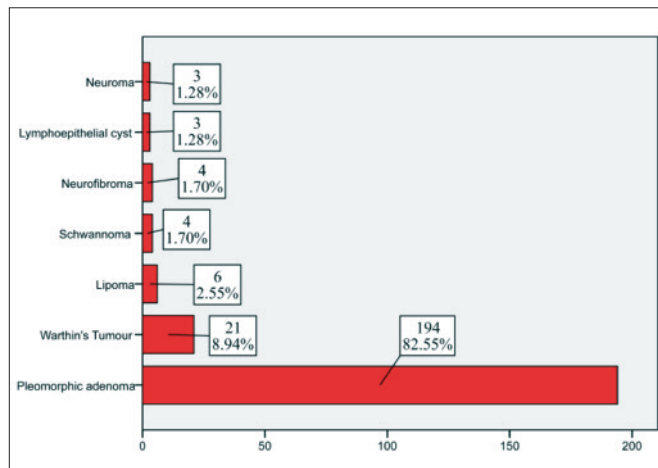


Figure 1: Morphological pattern of parotid gland tumours.

Table I: Surgical procedures and frequency of facial nerve palsy.

	Frequency	Percent	Frequency of nerve palsy
Valid superficial parotidectomy	188	80.0	43 (23%)
Total parotidectomy	47	20.0	23 (49%)
Total	235	100.0	66 patients

parotidectomy was done in 188 cases and extended parotidectomy in 47 cases. Frequency of facial nerve palsy in each group is given in Table I.

In the immediate postoperative period, facial nerve function was normal in 169 (72%) patients and nerve dysfunction was observed in 66 (28%) patients. Complete paresis involving all the branches of facial nerve was seen in 25 (10.6%) patients and 41 (17.4%) patients were having incomplete dysfunction.

Marginal mandibular branch of facial nerve was involved in 57 (86.3%) of cases. Of these, 62 (26.3%) recovered except 04 (1.7%) patients, who had permanent facial nerve dysfunction. Two patients each had marginal mandibular branch and complete facial palsy.

DISCUSSION

Complications of parotid surgery are diverse but the facial nerve damage or dysfunction is the major concern in parotid surgery and complete excision with minimal damage to nerve is one of the primary objective.⁸

In this study of 235 patients, female dominates with female to male ratio of 2:1 and the mean age was 34 years. The same female to male ratio of 2:1 was found by Awan whereas Rehman in his study reported F:M of 1.4:1 and the mean age of 40 years.^{12,13}

Pleomorphic adenoma was the most common tumour and about 80% were arising from the superficial lobe. This is in accordance with local and international literature which report pleomorphic adenoma of 75 - 85% and involvement of superficial lobe in about 70 - 90%.^{5,6,14}

Nouraei found only 42% of pleomorphic adenoma and 30% Warthin's tumours in his study, higher than reported in other studies.^{6,15,16}

In this study, facial nerve function immediately after surgery, was normal in 72% of cases and facial nerve dysfunction was observed in 28%. Rehman observed 26.6% temporary facial weakness in his series of parotidectomies,¹³ compared to 27% observed by Ellingson *et al.*, Ramadan observed 34% transient facial weakness.¹⁷ Adeyoma *et al.*¹⁸ observed it in 30% of cases, Nouraei *et al.*¹⁵ observed transient weakness in 40% of cases and Gaillard *et al.* in 42%.¹⁹ On the contrary, El-Shakhs *et al.*⁴ observed temporary facial palsy in only 16.6% of parotidectomies and his 84% cases were normal after surgery and so were 18.5% by Malik and Bova.^{20,21} Surprisingly, the frequency of temporary facial weakness was quite low about 8% in a big series of 934 parotidectomies at the university of Erlangen Germany between 2000-2008.²²

Frequency of permanent facial palsy in our series was 1.7% whereas in other studies it ranges from 2% to 10% and 11%.^{10,15,16,20,22} However, Gaillard *et al.* found no facial weakness after 6 months in his study of 131 benign parotid surgeries.¹⁹ It is in accordance with the literature which shows 0 - 10% rate of permanent facial weakness.²³

Frequency of facial nerve dysfunction both temporary and permanent was lower in superficial parotidectomy 23% as compared to total parotidectomy 49% and recurrent tumours 65%. Same high frequency of 71% for total parotidectomy was observed by Rehman,¹³ 40% by Ramadan¹⁷ and 60.5% by Gaillard.¹⁹ Recurrent benign tumour surgery was also associated with a high frequency of facial weakness by these authors ranging from 37 to 50%.^{4,17}

Marginal mandibular branch was the most common nerve involved in 86.3% of cases. In the study by Rehman, marginal mandibular nerve was involved in 90% of cases and zygomatic in 54% of cases.¹³

There have been many theories trying to explain the facial nerve dysfunction after its anatomical preservation in parotid surgery. This may be due to mechanical trauma such as crushing, compression and stretching during surgery or due to the ischemic injury as a result of nerve dissection from its surrounding. Dulguerov *et al.* concluded that nerve stretching may be the most probable etiology of facial nerve dysfunction after its anatomical preservation.²⁴

Frequency of facial nerve dysfunction may also be related to the technique of nerve identification, but recent evidences suggest no difference in the rate of temporary and permanent nerve dysfunction between antegrade and retrograde techniques.²⁵

CONCLUSION

Pleomorphic adenoma was the most common benign tumour and superficial lobe was the main site harbouring these tumours. The frequency of temporary and permanent facial nerve dysfunction is 62 (26.3%) and 4 (1.7%) respectively in 235 consecutive parotidectomies for benign parotid gland tumours. High incidence of facial nerve dysfunction is found in recurrent and deep lobe tumours. Low incidence of facial nerve dysfunction was found in superficial lobe pleomorphic adenoma. Nerve monitoring is not necessary except in recurrent tumours.

REFERENCES

- Musani MA. Morphological pattern of parotid gland tumours. *J Coll Physicians Surg Pak* 2008; **18**:274-7.
- Mistry D, Sood S. Benign salivary tumours. *CME Bulletin. Otolaryngol Head Neck Surg* 2004; **8**:49-52.
- Watkinson J, Gilbert RW, editors. *Stell and Maran's text book of head and neck surgery and oncology*. 5th ed. London: *Hodder Arnold*; 2012.
- El-Shakhs S, Khalil Y, Al-Bosraty H. Facial nerve preservation in total parotidectomy for parotid tumours. *Menoufia Med J* 2007; **20**:152-62.
- Glesson M, Cawson R, editors. *Scott-Brown's otorhinolaryngology, head and neck surgery*. 7th ed. London: *Hodder Arnold*; 2008.
- Obaid MA, Yousuf A. Surgical management of epithelial parotid tumours. *J Coll Physicians Surg Pak* 2004; **14**:394-9.
- Locati LD, Prott FJ, Gatta G, McGurk M, Licitra L. Major and minor salivary glands tumours. *Crit Rev Oncol Hematol* 2003; **45**:215-25.
- O'Brien. Current management of benign parotid tumours - the role of limited superficial parotidectomy. *Head Neck* 2003; **25**:946-52.
- O'Regan B, Bharadwaj G, Bhopal S, Cook V. Facial nerve morbidity after retrograde nerve dissection in parotid surgery for benign disease: a 10 years prospective observational study. *Br J Oral Maxillofac Surg* 2007; **45**: 101-7.
- O'Regan B, Bharadwaj G, Elders A. Techniques for dissection of the facial nerve in benign parotid surgery: a cross speciality survey of oral and maxillofacial and ear, nose and throat surgeons. *Br J Oral Maxillofac Surg* 2008; **46**:564-6.
- Marchese-Ragona R, De Fillipis C, Marioni G, Stafferi A. Treatment of complications of parotid gland surgery. *Acta Otolaryngol Ital* 2005; **25**:174-8.
- Awan MS, Ahmad Z. Diagnostic value of fine needle aspiration cytology in parotid tumours. *JPMA* 2004; **54**:617-9.
- Rahman MA, Alam MM, Joarder AH. Study of nerve injury in parotid gland surgery. *Nepalese J ENT Head Neck Surg* 2011; **2**:17-9.
- Van Lierop AC, Fagan JJ. Parotidectomy in Cape Town: a review of pathology and management. *S Afr J Surg* 2007; **45**: 96-98.
- Nouraei SA, Ismail Y, Ferguson MS, McLean NR, Milner RH,

- Thomson PJ, *et al.* Analysis of complications following surgical treatment of benign parotid disease. *ANZ J Surg* 2008; **78**: 134-8.
16. Shashinder S, Tang IP, Velayutham P, Prepageran N, Gopala KG, Kuljit S, *et al.* A review of parotid tumours and their management: a ten years experience. *Med J Malaysia* 2009; **64**:31-3.
17. Ramadan MM. Facial nerve morbidity following parotid surgery. *Suez Canal Univ Med J* 2003; **6**:29-34.
18. Adeyemo WL, Taiwo OA, Somefun OA, Olasoji HO, Ndukwe KC, Fashina AA, *et al.* A survey of facial nerve dissection techniques in benign parotid surgery among maxillofacial and ear, nose and throat surgeons in Nigeria. *Niger J Clin Prac* 2011; **14**:83-7.
19. Gaillard C, Périé S, Susini B, St Guily JL. Facial nerve dysfunction after parotidectomy: the role of local factors. *Laryngoscope* 2005; **115**:287-91.
20. Malik KA. Parotid gland tumours: a six years' experience. *Pak J Surg* 2007; **23**:133-5.
21. Bova R, Saylor A, Coman WB. Parotidectomy: review of treatment and outcomes. *ANZ J Surg* 2004; **74**:563-8.
22. Klintworth N. Postoperative complications after extracapsular dissection of benign parotid lesions with particular reference to facial nerve function. *Laryngoscope* 2010; **120**:484-90.
23. Guntinas-Lichius O. Pleomorphic adenoma of parotid gland: a 13 years experience of consequent management by lateral or total parotidectomy. *Eur Arch Otorhinolaryngol* 2004; **261**: 143-6.
24. Dulguerov P, Marchal F, Lehmann W. Postoperative facial nerve paralysis: possible etiological factors and results with routine facial nerve monitoring. *Laryngoscope* 1999; **109**:754-62.
25. Mahmood K, Williams GS, Morgan N. Postparotidectomy facial nerve paralysis: peripheral versus proximal identification. *B-ENT* 2010; **6**:117-21.

