

# Outcomes of Silicone Oil Removal

Shakir Zafar, Syeda Aisha Bokhari, Zeeshan Kamil, Munira Shakir, Syed Fawad Rizvi and Ghulam Mustafa Memon

## ABSTRACT

**Objective:** To evaluate the outcome and complications of removal of silicone oil after pars plana vitrectomy.

**Study Design:** Case series.

**Place and Duration of Study:** Layton Rahmatullah Benevolent Trust (L.R.B.T), Free Base Eye Hospital, Karachi, from February 2008 to January 2011.

**Methodology:** Ninety five eyes of 95 patients with a history of undergoing three-port pars plana vitrectomy were included in this study that subsequently underwent removal of silicone oil. Silicone oil was removed after ophthalmoscopically determining retina attachment or when the duration of silicone oil tamponade was atleast of 6 months. Patients were followed for a period of 12 months.

**Results:** Retinal re-detachment was seen in 19 (20%) out of 95 eyes, vitreous haemorrhage in 2 (2.1%) out of 95 eyes, corneal decompensation in 6 (6.3%) out of 95 eyes, hypotony in 7 (7.3%) out of 95 eyes, phthisis bulbi in 2 (2.1%) out of 95 eyes and lens opacification in 9 (9.4%) out of 95 eyes.

**Conclusion:** In this study, silicone oil removal resulted in various complications among which retinal re-detachment was the most frequent.

**Key Words:** Complications. Proliferative vitreoretinopathy. Silicone oil removal. Tractional retinal detachment.

## INTRODUCTION

Silicone does not occur naturally in free form, in its combined form it accounts for about 25% of the earth's crust. Silicone compounds are unique materials both in terms of the chemistry and in their wide range of useful applications. Silicone in combination with organic compounds provides unique properties that function over a wide temperature range, making the silicone based products less temperature sensitive than most organic surfactants.<sup>1</sup>

Silicone oil is used in vitreoretinal surgery to provide long-term internal tamponade in cases of complicated retinal detachment. It is generally removed after 3 months if the retina is attached and also must be removed upon the development of oil emulsification, keratopathy, secondary glaucoma or cataract.<sup>2</sup> The incidence of oil related complications has been constantly reduced by the development of highly viscous and highly purified oils as well as by refined operating techniques.<sup>3</sup>

Combined with vitreoretinal surgery, silicon oil injection has become a standard technique and improves the prognosis of complex retinal detachment associated with proliferative vitreoretinopathy, giant retinal tears, proliferative diabetic retinopathy, or ocular trauma. Compared with sulphur hexafluoride gas (SF6) as an

intraocular tamponade for the management of retinal detachment, eyes treated with silicone oil were more likely to be successfully re-attached, to achieve a better visual acuity, and to have fewer postoperative complications, particularly cataract, glaucoma, and keratopathy.<sup>4</sup>

The rationale of this study was to report the outcomes of removal of silicone oil in a series of patients in a tertiary care hospital.

The objective of the study was to evaluate the outcome and complications of removal of silicone oil after pars plana vitrectomy.

## METHODOLOGY

The records of 95 eyes of 95 consecutive patients who underwent silicone oil removal between February 2008 to January 2011 were reviewed. This study was approved by hospital ethical review committee. All surgeries were done by a pair of surgeon (SZ and MS). Patients with pseudohypopyon, un-controlled intraocular pressure and attached retina for more than 2 years were included. Patients with PVR grade-C, optic atrophy and total retinal detachment were excluded. Criteria to remove the silicone oil were a completely attached retina as determined ophthalmoscopically, and the duration of silicone oil tamponade was at least 6 months.

The data acquisition was performed by two investigators (SAB and ZK) independently of the surgeon, whereas, proforma from the patients was gathered by resident medical officer (GMM). The study was conducted under the supervision of hospital incharge (SFR). In all patients, silicone oil with a viscosity of 1000 centistokes was used. Depending on the intraoperative situation,

*Department of Ophthalmology, Layton Rahmatullah Benevolent Trust (L.R.B.T), Free Base Eye Hospital, Karachi.*

*Correspondence: Dr. Shakir Zafar, House No. 61, LRBT Free Eye Hospital, Korengi 2 1/2, Karachi.*

*E-mail: drshakirzafar@yahoo.com*

*Received: July 07, 2012; Accepted: March 19, 2013.*

additional procedures performed during pars plana vitrectomy included use of an encircling band, membrane peeling, endo-drainage of subretinal fluid, use of perfluorocarbon liquids, endolaser coagulation, cryopexy, relaxing retinotomies, and cataract surgery. All patients were observed for complications for next 12 months.

The statistical analysis of the data was done by the software Statistical Package for Social Sciences (SPSS) version 17. Descriptive statistics was calculated in terms of mean, standard deviation, minimum, maximum and range. Mean and standard deviation were calculated for quantitative variable like age of the patients. Frequency and percentage were calculated for gender, route of removal of silicone oil, complications and indications of retinal detachment surgery.

**RESULTS**

This series included 50 (52.6%) male patients and 45 (47.4%) female patients. The mean age was 39.10 ± 10.26 years ranging from 21 to 60 years. Indications for pars plana vitrectomy were tractional retinal detachment secondary to diabetic retinopathy in 58 (61.1%) eyes, and proliferative vitreoretinopathy of grade-C or D in 37 (38.9%) eyes. Silicone oil was removed via pars plana sclerotomies in 87 (91.5%) eyes. Two pars plana ports were made; one at 6 O'clock position and the other at 12 O'clock. The 6 O'clock port was used for irrigation whereas the superior port was used for silicone oil removal. In the remaining 8 (8.5%) eyes, which were aphakic, silicone oil was removed through the pupil. Silicone oil removal was performed under general anaesthesia in 9 (9.5%) of eyes, and under local anaesthesia in 86 (90.5%) of eyes.

Out of 95 eyes undergoing silicone oil removal, a total of 19 (20%) developed a retinal re-detachment after silicone oil removal (Figure 1a). The cause of re-detachment included development of anterior proliferative vitreoretinopathy due to traction and new retinal breaks in 11 out of 19 (57.8%) eyes; re-proliferations behind the equator with tractional retinal detachment in 3 out of 19 (15.7%) eyes; tractional retinal

detachment secondary to new proliferations in diabetic eyes in 5 out of 19 (26.3%, Figure 1b). Among these 19 patients with re-detachment, 11 (57.8%) presented with re-detachment within first week postoperatively, 5 (26.3%) eyes presented within 4 weeks postoperatively, and 3 (15.7%) eyes presented within 8 weeks post-operatively. All 19 eyes were re-operated. In 15 eyes revision surgery consisted of re-vitrectomy, retinectomy, membrane peeling with replacement of 5000 cs silicone oil. Re-vitrectomy with temporary perfluorocarbon instillation and intraocular gas injection was successfully performed in 3 eyes, whereas, cryotherapy and additional scleral buckling were performed in 2 eyes.

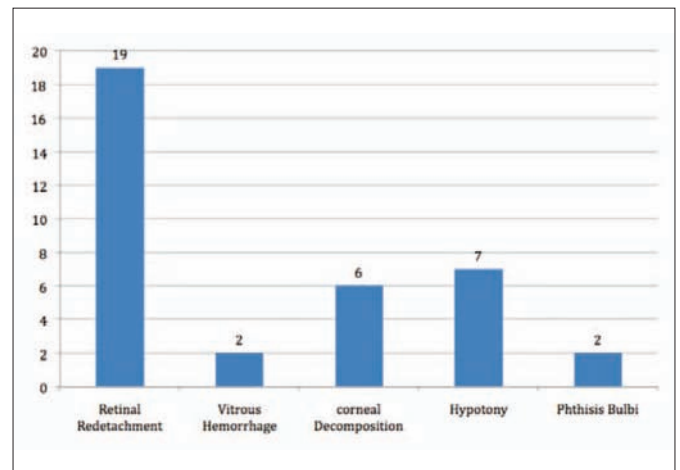
Cataract formation was observed in 9 (9.4%) out of 95 eyes, mostly within the first 6 months. All eyes underwent cataract extraction and implantation of posterior chamber lens.

Corneal decompensation was seen in 6 (6.3%) of 95 eyes (Figure 1c), because the oil had entered the anterior chamber and had been in contact with the corneal endothelium. All these patients were treated with penetrating keratoplasty, later on.

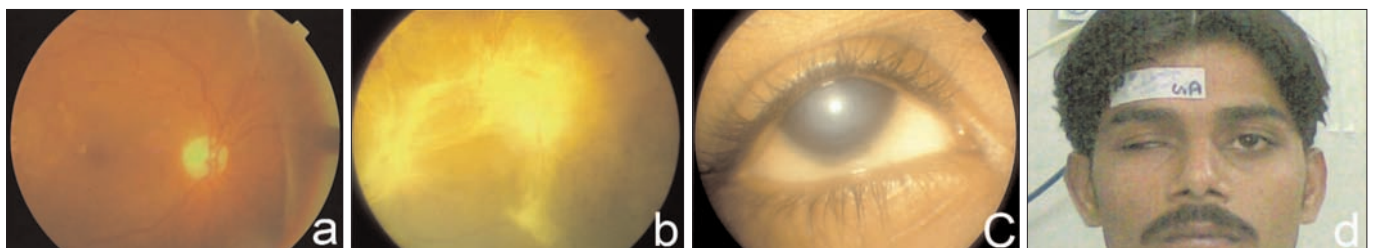
Postoperative hypotony (< 8 mmHg) occurred in 7 out of 95 (7.3%). In 2 eyes, it was accompanied by massive fibrin exudation with IOP below 5 mmHg. In 5 out of 7 eyes, IOP returned to normal within 10 days. Two out of 7 (28.5%) eyes became phthisic soon after oil removal (Figure 1d), out of which one eye subsequently underwent enucleation with orbital implant.

**Table I:** Age (n = 95).

Variable	Mean	SD	Minimum	Maximum	Range
Age (years)	39.10	10.26	21	60	39



**Figure 2:** Distribution of complications (n = 95).



**Figure 1:** Photographs of various complications; (a) Re-retinal detachment; (b) PVR secondary to new proliferation in diabetic eyes, (c) corneal decompensation, (d) phthisis bulbi.

Vitreous haemorrhage was observed in one eye (2.1%). Distribution of complications is illustrated in Figure 2.

## DISCUSSION

Silicone oil has been used in the treatment of complex retinal detachments for many years.<sup>5</sup> However, many authors have reported postoperative anterior segments complications, such as cataract, glaucoma, and keratopathy even after successful re-attachment of the retina.<sup>6</sup> The possibility of toxic effect of silicone oil on the retina remains controversial.<sup>7</sup> When silicone oil has been used in conjunction with vitrectomy, it can subsequently be removed easily via the pars plana in phakic eyes or via the limbus in aphakic eyes. It has been suggested that many complications may be prevented or their progression arrested when the silicone oil is removed a few weeks or months after surgery.<sup>8</sup> There are few reports detailing the effects of removing it either as a prophylactic measure or as a part of the management of established complications.<sup>9</sup>

There is no definitive agreement on the appropriate time period and indication of silicone oil removal. However, the rate of retinal re-detachment after silicone oil removal varies widely and appears to correlate with the underlying disease process and its severity. The literature on strategies of silicone oil removal, the rate of complications, and thus the risk-benefit ratio is scant.<sup>10</sup> Therefore, for silicone oil removal, we rely on personal experience and the rare studies of silicone oil removal.

The reported incidence of re-detachment varies between 0% and 32%.<sup>11,12</sup> This variation is most probably due to marked differences in the number of eyes studied, the duration of follow-up after silicone oil removal, and the underlying diseases. Anatomical success after silicone oil removal, defined as complete retinal attachment was achieved in 76 (80%) out of 95 eyes in this study, whereas, retinal re-detachment after silicone oil removal was seen in the remaining 20%. Falkner reported 17.4% cases of re-detachment after silicone oil removal in their study.<sup>13</sup> Darakhshanda reported 38% re-detachment after silicone oil removal.<sup>14</sup> In another study, the reported rate of re-detachment after silicone oil removal was 25.3%.<sup>15</sup> Scholda reported 20.5% cases of retinal detachment in their study.<sup>16</sup> Pavlovic commented that eyes with completely attached retinas, the risk of complication and re-detachment after silicone oil removal is relatively low.<sup>17</sup> Lens changes were observed in 9.4% of eyes in this study, whereas Scholda reported 36.7% lens opacification after silicone oil removal.<sup>16</sup> Nawrocki *et al.* found a cataract rate of 44.4%.<sup>18</sup> Gonvers found a cataract rate of 78%.<sup>19</sup>

Rates of hypotony were reported between 5% and 51.4% in the literature.<sup>11,13</sup> In this study, postoperative hypotony (IOP < 8 mmHg) was found in 7.3% of eyes, in which, 2 (2%) eyes ended up in phthisis. Falkner also reported phthisis in 0.9% of eyes in his study.<sup>13</sup> Bassat

*et al.* reported 2 out of 67 eyes were hypotonous after silicone oil removal.<sup>20</sup> Literature review revealed rates of keratopathy in the range of 4.5 – 63%.<sup>11,13</sup> Scholda reported 8.4% of keratopathy in his study.<sup>16</sup> In the current study, keratopathy was observed in 6.3% of eyes. Vitreous haemorrhage was seen in 2.1% cases in this study. Falkner reported 4.3% cases of vitreous haemorrhage.<sup>13</sup>

## CONCLUSION

The occurrence of oil related complications has led to the tendency of its removal after a certain filling period, but various studies including the current one have reported different complications associated with silicone oil removal which included retinal re-detachment in higher percentage.

## REFERENCES

- O'Lenick AJ. Basic silicone chemistry: a review [Internet]. 1999. Available from: [http://www.siliconespectator.com/articles/Silicone\\_Spectator\\_January\\_2009.pdf](http://www.siliconespectator.com/articles/Silicone_Spectator_January_2009.pdf)
- Nagpal M, Videkar R, Mehrotra N. Hybrid technique for silicone oil removal. *Retina Today* 2011; **36**:40.
- Scholda C, Egger S, Lakits A, Haddad R. Silicone oil removal: results, risks and complications. *Acta Ophthalmol Scand* 1997; **75**:695-9.
- Lucke K, Strobel B, Foerster M, Laqua H. Secondary glaucoma after silicone oil surgery. *Klin Monbl Augenheilkd* 1990; **196**:205-9.
- Cibis PA, Becker B, Okun E, Canaan S. The use of liquid silicone in retinal detachment surgery. *Arch Ophthalmol* 1962; **68**:590-9.
- Haut J, Ullern M, Chermet M, Van Effenterre G. Complications of intraocular injections of silicone combined with vitrectomy. *Ophthalmologica* 1980; **180**:29-35.
- Ober RR, Blanks JC, Ogden TE, Pickford M, Minckler DS, Ryan SJ. Experimental retinal tolerance to liquid silicone. *Retina* 1983; **3**:77-85.
- Leaver PK, Cooling RJ, Feretis EB, Lean JS, McLeod D. Vitrectomy and fluid/silicone-oil exchange for giant retinal tears: results at six months. *Br J Ophthalmol* 1984; **68**:432-8.
- Cairns JD, Anand N. Combined vitrectomy, intraocular microsurgery and liquid silicone in the treatment of proliferative vitreoretinopathy. *Aust J Ophthalmol* 1984; **12**:133-8.
- Kampik A, Gandorfer A. Silicone oil removal strategies. *Semin Ophthalmol* 2000; **15**:88-91.
- Azen SP, Scott IU, Flynn HW Jr, Lai MY, Topping TM, Benati L, *et al.* Silicone oil in the repair of complex retinal detachments. A prospective observational multicentre study. *Ophthalmology* 1998; **105**:1587-97.
- Scholda C, Egger S, Lakits A, Walch K, von Eckardstein E, Biowski R. Retinal detachment after silicone oil removal. *Acta Ophthalmol Scand* 2000; **78**:182-6.
- Falkner CI, Binder S, Kruger A. Outcome after silicone oil removal. *Br J Ophthalmol* 2001; **85**:1324-7.
- Darakhshanda K, Ghayoor I. Outcome of silicone oil removal in eyes undergoing 3-port pars plana vitrectomy. *Pak J Ophthalmol* 2011; **27**:17-20.

15. Jonas JB, Knorr HL, Rank RM, Budde WM. Retinal redetachment after removal of intraocular silicone oil tamponade. *Br J Ophthalmol* 2001; **85**:1203-7.
16. Scholda C, Egger S, Lakits A, Haddad R. Silicone oil removal: results, risks and complications. *Acta Ophthalmol Scand* 1997; **75**:695-9.
17. Pavlovic S, Dick B, Schmidt KG, Tomic Z, Latinovic S. Long-term outcome after silicone oil removal. *Ophthalmologie* 1995; **92**:672-6.
18. Nawrocki J, Ghoraba H, Gabel VP. Problems with silicone oil removal. A study of 63 consecutive cases. *Ophthalmologie* 1993; **90**:258-63.
19. Gonvers M. Temporary silicone oil tamponade in the management of retinal detachment with proliferative vitreoretinopathy. *Am J Ophthalmol* 1985; **100**:239-45.
20. Bassat IB, Desatnik H, Alhalel A, Treister G, Moisseiev J. Reduced rate of retinal detachment following silicone oil removal. *Retina* 2000; **20**:597-603.

