

Wilkie's Syndrome

Abdul Rehman, Aisha Saeed, Tauseef Shaukat, Kashif Jamil, Amjad H. Zaidi and Kamran Abdullah

ABSTRACT

Wilkie's syndrome is a rare variant of small intestinal obstruction resulting from compression of third part of the duodenum by the superior mesenteric artery. A girl 15 years of age, presented with postprandial abdominal pain, bilious vomiting and weight loss. Radiological imaging revealed vascular duodenal compression which was relieved by timely surgical intervention.

Key words: *Wilkie's syndrome. Superior mesenteric artery syndrome. Aortomesenteric syndrome. Mesentery root syndrome. Vascular duodenal compression. Anorexia nervosa.*

INTRODUCTION

Wilkie's Syndrome is an uncommon cause of upper small gut obstruction resulting from entrapment and compression of third part of the duodenum between the superior mesenteric artery ventrally and the abdominal aorta dorsally at the level of third lumbar vertebra.¹ This syndrome is also known as superior mesenteric artery syndrome, aortomesenteric syndrome, mesenteric root syndrome, chronic duodenal ileus, vascular duodenal compression or cast syndrome. Since its first comprehensive description by Wilkie in 1927,² only few cases have been reported in the medical literature. Because of its rarity and non-pathognomonic symptomatology, it can pose a diagnostic dilemma to an unwary clinician.

This report describes its occurrence in a teen aged girl with anorexia nervosa.

CASE REPORT

A 15-year old girl, known case of anorexia nervosa, presented with history of postprandial upper abdominal pain, anorexia, bilious vomiting, constipation and progressive weight loss of four months duration. Her symptoms were characteristically aggravated by lying supine after eating and were relieved by adopting the left lateral decubitus position. She had repeated hospitalization with no improvement. Her general physical examination revealed cachexia, pallor, koilonychia and mild pitting pedal edema while systemic examination was unremarkable. The abdomen was scaphoid and mildly tender in the epigastrium with no guarding or rigidity. No mass or visceromegaly was

palpable. Bowel sounds and digital rectal examination were normal. Laboratory workup disclosed iron-deficiency anemia, hypoalbuminemia, hyponatremia, hypokalemia, pre-renal azotemia and metabolic alkalosis. Plain abdominal radiographs were inconclusive. Abdominal ultrasonography and gastroscopy apart from showing gastroduodenal dilatation did not depict any underlying aetiological factor. Barium meal study displayed gastroduodenal dilatation, a vertical cut-off at the level of third part of the duodenum (Figure 1), transient hold-up of the contrast in the proximal gastroduodenal segment with to and fro motion on fluoroscopy and gradual escape into the jejunum over a period of 12-24 hours (Figure 2). These radiological findings were highly suggestive of Wilkie's syndrome, which was confirmed by contrast-enhanced CT abdomen.

On failure of conservative measures to improve her condition, she was explored through a midline laparotomy incision. Peroperative findings included extrinsic compression over third part of the duodenum by the superior mesenteric artery with moderate degree of proximal gastroduodenal dilatation, acute narrowing of the aortomesenteric angle with complete absence of the retroperitoneal fat, and a stout suspensory ligament of Trietz causing sharp posterosuperior pulling of the duodenojejunal flexure. Third and fourth parts of the duodenum were thoroughly mobilized along with division of the ligament of Trietz to release the duodenojejunal flexure (Strong's operation). Postoperative barium films showed a free passage of the contrast into the jejunum (Figure 3). She made an uneventful recovery and was discharged on the 5th postoperative day. She gained about 4 kg weight within a couple of weeks.

DISCUSSION

Wilkie's syndrome is a rare clinical entity comprising 0.1% of the cases of small intestinal obstruction. Eight out of ten patients are thin and majority of them are between the ages of 10 and 40 years. Females are affected twice as often as males.³

Department of General Surgery, Pakistan Atomic Energy Commission (PAEC), General Hospital, Islamabad.

Correspondence: *Dr. Abdul Rehman, House No. 537, Street No. 18, Chaklala Scheme-3, Rawalpindi-46000.*

E-mail: surgeonarehman@yahoo.com

Received October 25, 2008; accepted July 10, 2010.

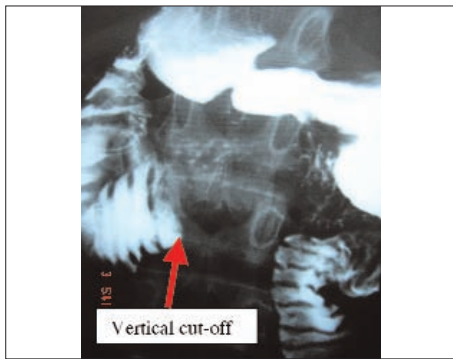


Figure 1: Pre-operative barium X-rays showing vertical cut-off over third part of the duodenum.

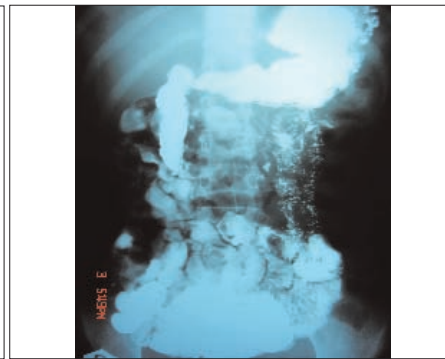


Figure 2: Pre-operative barium X-rays showing hold-up of the contrast in the gastroduodenal segment 12 hours after ingestion of barium.

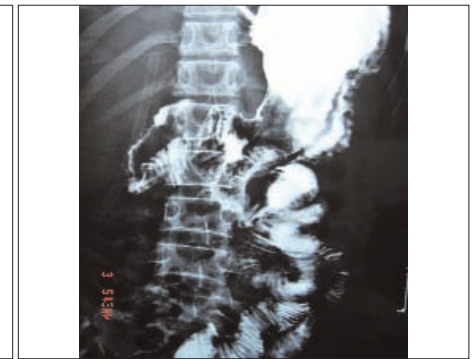

Figure 3: Postoperative barium X-rays showing free passage of the contrast into the jejunum after Strong's operation.

Anatomically, the superior mesenteric artery arises from ventral aspect of the abdominal aorta at an angle of 45°. 1-3 This aortomesenteric angle contains left renal vein, uncinate process of the pancreas and third part of the duodenum. The duodenum is held in that angle by the ligament of Trietz and is cushioned by the retroperitoneal fat and lymphatics. Any condition that causes narrowing of the aortomesenteric angle by depleting of the retroperitoneal fat may precipitate the vascular duodenal compression. Some well-known predisposing conditions include anorexia nervosa, malabsorption syndrome, drug-addiction, AIDS, malignant cachexia, and hypercatabolic states like polytrauma, major surgery, extensive burn, and invasive sepsis. 4-6

Clinical features of Wilkie's syndrome are entirely vague and non-specific. The most prominent symptoms are post-prandial abdominal pain (59%), nausea (40%), vomiting (50%), early satiety (32%), and anorexia (18%). These symptoms are aggravated by lying supine after eating and are relieved by assuming the left lateral decubitus, prone or knee-chest position. The symptoms are also relieved by elevating root of the mesentery by Haynes' manoeuvre (which is the pressure exerted below the umbilicus in cephalad and dorsal direction). Due to fear of precipitation of symptoms after eating, many patients develop complete aversion to food which, in turn, causes more speedy weight loss and duodenal compression, thus spurring the vicious cycle. 7

The diagnosis of Wilkie's syndrome is made by the process of exclusion. Delay in the diagnosis may prove fatal secondary to dehydration, electrolyte imbalance, malnutrition or even duodenal perforation. Plain abdominal radiographs, ultrasonography and upper gastrointestinal endoscopy add little to reach the diagnosis. However, barium meal study is highly specific in pinpointing the diagnosis in majority of the cases (95%). The characteristic radiological findings suggestive of Wilkie's syndrome (Haynes' criteria) include: 1) dilatation of first and second parts of the duodenum with or without gastric dilatation; 2) abrupt vertical cut-off over third part of the duodenum; 3) transient hold-up of the contrast in the gastroduodenal segment with to and fro motion; and

4) quick distal escape of the contrast on assuming the left lateral position. In equivocal cases, contrast-enhanced CT abdomen provides a definite answer. 1,3,5,8

The management of Wilkie's syndrome consists of removal of underlying aetiological factor, fluid resuscitation, replenishment of electrolyte deficits, gastroduodenal decompression, gastric acid suppression by H2-blockers or proton pump inhibitors and nutritional supplementation with or without parenteral nutrition to improve the body weight. These conservative measures are successful in about two-third of the cases (66%). 6 Surgical intervention should seriously be contemplated when conservative measures fail to improve the symptoms, when symptoms are incapacitating, there is rapid weight loss, persistent intolerance to oral feeds, marked proximal gastroduodenal dilatation or associated peptic ulcer disease. 1,5,9

The nature of surgery depends upon the severity of duodenal compression and extent of proximal gastroduodenal dilatation. If there is mild to moderate gastroduodenal dilatation, then mobilization of third and fourth parts of the duodenum along with division of the ligament of Trietz allows downward fall of the duodenum by at least two fingers breadth which is quite sufficient to ease out the symptoms of Wilkie's syndrome (Strong's operation). 5,6,9 If uncertainty exists regarding adequacy of the duodenal mobilization in relieving the symptoms or there is apprehension about postoperative recurrence of the symptoms, then third and fourth parts of the duodenum and the duodenojejunal flexure should be coaxed out of the aortomesenteric angle and brought on right side of the superior mesenteric vessels for complete resolution the symptoms. Being simple and less invasive, Strong's operation is met with a success rate of 80%. 5,6,9 On the other hand, presence of marked gastroduodenal dilatation necessitates performance of duodenojejunostomy between dilated second part of the duodenum and a loop of the jejunum just distal to the duodenojejunal flexure. Although more invasive, it is a highly effective operation having a success rate of 100% and a zero recurrence. Strong's operation and duodenojejunostomy are also being performed laparoscopically. 9,10

Because of its rarity and vague clinical manifestations, Wilkie's syndrome should always be kept in mind whenever confronted with an asthenic, malnourished or psychiatric patient suffering from intestinal obstruction.

REFERENCES

1. Niaz Z, Chaudhry FA, Gardezi JR. Superior mesenteric artery syndrome: an uncommon cause of upper intestinal obstruction. *J Coll Physicians Surg Pak* 2006; **16**:666-8.
2. Park JH, Lee SH, Park DH, Park JY, Park SH, Chung IK, *et al*. Superior mesenteric artery syndrome. *J Vasc Interv Radiol* 2008; **67**:348-50.
3. Karrer FM, Jones SA. Superior mesenteric artery syndrome [Internet]. [updated 16 Jul 2006]. Available from: <http://emedicine.medscape.com/article/932220-overview>
4. Plesa A, Constantinescu C, Crumpie F, Cotea E. Superior mesenteric artery syndrome: an unusual cause of intestinal obstruction. *J Gastrointestin Liver Dis* 2006; **15**:69-72.
5. Welsch T, Buchler MW, Kienle P. Recalling superior mesenteric artery syndrome. *Dig Surg* 2007; **24**:149-56.
6. Jawad NH, Abdulla Al-Sanae, Wafa'a Al-Qabandi. Superior mesenteric artery syndrome: an uncommon cause of intestinal obstruction: report of two cases and review of literature. *Kuwait Med J* 2006; **38**:241-4.
7. Biank V, Werlin S. Superior mesenteric artery syndrome in children: a 20-year experience. *J Pediatr Gastroenterol Nutr* 2006; **42**:522-5.
8. Unal B, Aktas A, Kemal G, Bilgili Y, Gulter S, Daphan C, *et al*. Superior mesenteric artery syndrome: CT and ultrasonography findings. *Diagn Interv Radiol* 2005; **11**:90-5.
9. Jain R. Superior mesenteric artery syndrome. *Curr Treatment Options Gastroenterol* 2007; **10**:24-7.
10. Jo JB, Song KY, Park CH. Laparoscopic duodenojejunostomy for superior mesenteric artery syndrome: report of a case. *Surg Laparosc Endosc Percut Tech* 2008; **18**:213-5.

