

# Gastropleural Fistula: An Unusual Sequel of Blunt Chest Trauma

Muhammad Sultan Muzaffar, Bilal Umair, Asif Asghar, Mujahid Zulfiqar Ali,  
Muhammad Shoaib Hanif and \*Daud Kamal

## ABSTRACT

In the October 2005 Earthquake in mountainous Azad Kashmir and adjacent areas in Pakistan, a young female sustained crush injury chest and upper abdomen. She remained hospitalized with lower chest pain. All initial investigations were normal and she was discharged symptom-free on conservative management. Six months later, she developed acute left sided chest pain and dyspnoea. Provisional diagnosis of empyema was made on X-ray, and tube thoracostomy was done. Diagnostic VATS revealed gastropleural fistula secondary to necrosis of herniated stomach. Resection of necrosed stomach, repair of diaphragm and decortication and transthoracic repair with lower thoracoplasty two months later was performed but both were unsuccessful. After another 02 months, a Roux-en-Y gastrojejunostomy at fistula site was fashioned which proved curative.

**Key words:** *Gastropleural fistula. Chest pain. Blunt chest trauma. Crush injury. Earthquake. Gastrojejunostomy.*

## INTRODUCTION

Pleura may develop a fistulous communication with any of the cavities near it.<sup>1</sup> Gastropleural fistula is a rare such communications. It is a sequel of trauma which may take upto 24 years before presentation.<sup>2</sup> It may close spontaneously or take an unpredictably intractable course.

The presently reported case is also a late presentation of gastropleural fistula following crush injury to thorax and abdomen.

## CASE REPORT

In October 2005 Earthquake, hitting the Northern Areas of Pakistan, a 24-year-old pregnant female got buried under the rubble of her house and sustained crush injury to the left sided chest and abdomen. Her son was trapped under the chest. The boy died of the compression and she aborted later on. The rescued lady remained admitted at a peripheral hospital with vague pain in lower chest. The investigations did not reveal any abnormality and she was discharged symptom-free after conservative management with analgesics.

Six months later, she developed acute pain in the epigastrium and left lower chest associated with vomiting and dyspnoea. On physical examination, she was haemodynamically stable but found to be tender in epigastrium. The left lower chest exhibited signs of

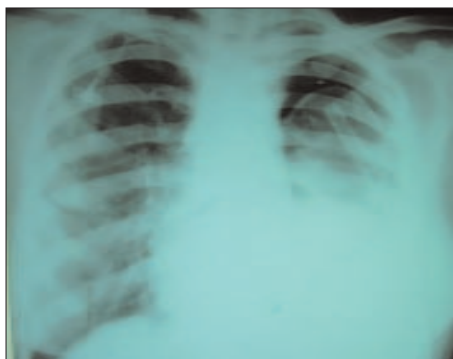hydropneumothorax and lung collapse. The X-ray chest revealed left sided hydropneumothorax with loculations (Figure 1). Chest intubation was performed and purulent fluid was drained. A night before diagnostic VAT (Video Assisted Thoracoscopy), she developed drainage of ingesta in the chest tube. On diagnostic VAT, the lower left chest cavity was found to be filled with thick fibrinous peel, food particles and gangrenous tissue. Methylene blue was injected down the esophagus, through the nasogastric tube to locate the site of leakage, which could not be verified. The procedure was then converted to formal exploratory thoracotomy. A defect of the size of 4 x 5 cm was found in the left hemidiaphragm through which fundus and more than 50% of the body of the stomach had herniated into the pleural cavity (Figure 2). The herniated portion had necrosed and was the cause of leakage of ingesta. Alongside this was a thick pleural peel with multiple loculations of empyema. After resection, only 20% of stomach remained which was fashioned into a tube. Thorough debridement followed by primary repair of the stomach and diaphragm at healthy margins, decortication of the chest cavity and feeding jejunostomy were performed. She developed a recurrence. A Claggett window was fashioned in order to facilitate the drainage. The wounds were managed conservatively.

The second thoracotomy was performed two months later and a graft of intercostal muscle flap was placed over the gastric repair. The residual pleural space was obliterated by thoracoplasty. The fistula recurred but this time the track did not connect to the pleural cavity and was below the diaphragm. Conservative trial was again given for about 2 months for the track to close and inflammation to settle but it remained unsuccessful. Laparotomy was performed and fistula track was excised. Considering the young age, the oesophagus

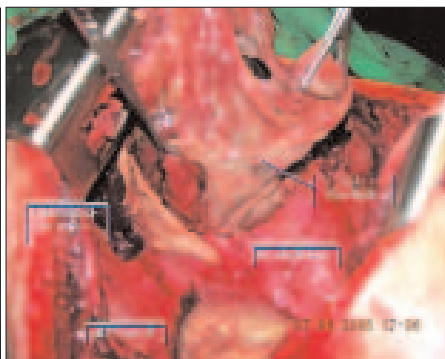
*Department of Thoracic Surgery/Surgery\*, Combined Military Hospital, Rawalpindi.*

**Correspondence:** *Dr. Birg. Muhammad Sultan Muzaffar,  
110-Tamaz-ud-Din Road, Rawalpindi.  
E-mail: muzaffarsultan@hotmail.com*

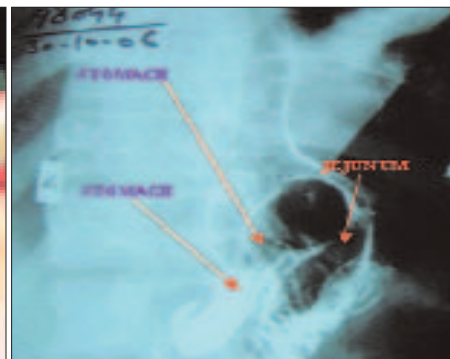
*Received March 11, 2008; accepted March 6, 2009.*



**Figure 1:** X-ray at presentation showing loculated fluid in left hemithorax with chest tube in position.



**Figure 2:** Thoracotomy showing necrosed stomach herniating from diaphragm.



**Figure 3:** Contrast study after final successful repair showing Roux-en-Y gastrojejunostomy.

and remaining stomach was saved and a Roux-en-Y gastrojejunostomy was performed and the defect in stomach was closed by application of the end of jejunum (Figure 3). During recovery, she had wound dehiscence and minor leakage from anastomotic site, which were managed conservatively. The procedure proved curative with final healing.

### DISCUSSION

Anteroposterior compression of the chest most commonly tears the unsupported left hemidiaphragm. Ruptured diaphragm starts swallowing the stomach into the chest, due to the negative intrapleural pressure. This herniated stomach may necrose because of strangulation that results in gastropleural fistula formation. Even if the necrosis does not occur, the wall of the stomach thins out, resultantly the repair becomes difficult. Acute onset left lower chest and epigastric pain along with vomiting are the commonest symptoms, while presence of ingesta in the chest drain is almost diagnostic. Chest radiograph reveals left sided pleural effusion but barium meal will always define the fistula. The management of this high output upper GI fistula is tricky, moreover, gastric acid spillage into left pleural cavity is one phenomenon which always demands early surgical intervention to counter the septic load.

In this patient, it was the initial blunt chest trauma which led to the rupture of diaphragm and either the stomach herniation was missed at her first hospitalization in post-earthquake days. Alternatively, the herniation may have developed later on due to the persistent negative pressure of the chest cavity sucking the stomach inside the chest. By the time she presented, her stomach had already necrosed with formation of gastropleural fistula. The interval between trauma and formation of gastropleural fistula is variable but once diagnosed, the disease is a surgical emergency.

The commonest etiology of the condition is gastric malignancy, mostly lymphomas, invading the left hemidiaphragm.<sup>3</sup> Others include perforation of gastric ulcer into left pleural cavity, post left sided pneumo-

nectomy that appears to disturb the suspensory mechanics of sub-diaphragmatic structures, iatrogenic due to NG tube and external trauma causing rupture of left hemidiaphragm.<sup>4-6</sup> Patients with traumatic gastropleural fistulas have almost similar clinical progression as observed in this case.<sup>1,2,7,8</sup>

These cases are managed by surgery, either emergency or delayed, undertaken by thoracic, thoracoabdominal or abdominal approach. The early failures in this patient can in part be due to the empyema associated with the gastropleural fistula and the already inflamed gastric wall. However, in the subsequent repair, sufficient time was given for the inflammation to settle and the empyema by fashioning a Claggett window. The decortication and thoracoplasty to reduce pleural space and repair of the gastric fistula was partially successful because the empyema did not recur and the fistulous track this time remained below the diaphragm. It was a high output fistula in which conservative approach has minimal role. Ample time was given for the inflammatory process to settle down before the next procedure. In the third repair, Roux-en-Y gastrojejunostomy was fashioned keeping in view the high output nature of the gastric fistula. This remained successful showing that surgical repair is the only definitive treatment. Prognosis depends upon delay from diagnosis to surgical intervention.

### REFERENCES

1. Melamed M, Barker WL, Langston HT. Unusual pleural fistulas. *Am J Roentgenology* 1974; **120**:876-82.
2. Karacan O, Savas S, Akcay S, Turk E, Harman A. Gastropleural fistula as a delayed complication of blunt abdominal trauma: spontaneous closure of the lesion. *Internet J Gastroenterol* 2003; **2**:1-6.
3. Adachi Y, Sato Y, Yasui H, Nishmiura S, Tanimura A, Yuasa H, et al. Gastropleural fistula derived from malignant lymphoma. *J Gastroenterol* 2002; **37**:1052-6.

4. Yasuko A. Gastropleural fistula due to perforated gastric ulcer. *Nippon Kokyuki Gakkai Zasshi* 2006; **44**:620-4.
5. Takeda S, Funaki S, Yumiba T, Ohno K. Gastropleural fistula due to gastric perforation after lobectomy for lung cancer. *Interact Cardiovasc Thorac Surg* 2005; **4**:420-2.
6. Bini A, Grazia M, Petrella F, Stella F, Bazzochi R. Spontaneous biliopneumothorax (thoracobilia) following gastropleural fistula due to stomach perforation by nasogastric tube. *Ann Thorac Surg* 2004; **78**:339-41.
7. McFarlane ME, Martin A. Traumatic gastropleural fistula. *West Indian Med J* 2004; **53**:428-9.
8. Schwab RJ, Jarvik JG. Tension pneumothorax secondary to a gastropleural fistula in a traumatic diaphragmatic hernia. *Chest* 1991; **99**:247-9.

