

Tuberculosis of Transverse Testicular Ectopic Testis Associated with Persistent Mullerian Duct Syndrome

Nandlal Kella¹, Prem Kumar Rathi² and Mohammad Ali Qureshi¹

ABSTRACT

A 10-month-old male infant presented with bilateral inguinal hernia and left un-descended testis. During right herniotomy, both gonads were found on same side with mullerian duct structures. On naked eye examination, both gonads were normal looking. Excision of mullerian duct remnant and fixation of ectopic testis was made. Histopathological examination revealed that gonads were testicles. Presence of multiple granulomas composed of Langhans cells and epithelioid cells in ectopic testicle suggested tuberculosis. Patient was kept on antituberculous therapy and was on regular follow-up without any complication.

Key words: *Genitourinary tuberculosis. Testis. Transverse testicular ectopia. Persistent Mullerian duct syndrome.*

INTRODUCTION

Genital tract tuberculosis is uncommon before puberty and testicular tuberculosis in children is rarely found. Common routes for tuberculous genital infection in males are local infiltration, hematogenous and retrograde infection from posterior urethra to testis.¹ Presentation of genital tract tuberculosis in boys varies from asymptomatic, epididymitis, epididymo-orchitis and testicular swelling.

Transverse Testicular Ectopia (TTE), an extremely rare anomaly, is a deviation of testicular descent resulting in unilateral location of both testes.² Persistent Mullerian Duct Syndrome (PMDS) is characterized by retention of Mullerian duct derivatives (uterus, vagina and fallopian tube) in a patient, otherwise normally virilized usually with inguinal hernia or cryptorchidism.³

We are reporting a unique case having multiple problems of PMDS, transverse testicular ectopia and tuberculosis of ectopic testis.

CASE REPORT

A 10-month-old male infant presented with congenital bilateral inguinal hernia and left un-descended testis at the Department of Pediatric Surgery at Liaquat University Hospital, Hyderabad. There was no history of failure to thrive, fever, cough or urinary problems. Parents were healthy and had no chronic illness. On

physical examination, baby was healthy with reducible bilateral inguinal hernia and impalpable left testis, while right testis was normal in location. Examination of chest and abdomen was unremarkable. Complete blood count, erythrocytes sedimentation rate and X-ray chest were normal.

Ultrasonography of genitalia showed right testis 1.3 x 0.7cm in size and left testis was not visible, while abdominal ultrasound was insignificant and could not detect the Mullerian duct structures. During right herniotomy, both gonads appeared on right side with Mullerian duct structures (Figure 1). Both gonads were normal in appearance, while the ectopic testis was smaller in size. Left vas deferens was attached with uterus, while right vas and vessels were separate. Longitudinal biopsies of both gonads were taken and sent for histopathology. Bilateral herniotomy was performed, Mullerian duct structures were excised and left ectopic testis fixed trans-septally in left hemiscrotum. Histopathological report showed that gonads were testes. There were multiple granulomas composed of Langhans giant cells and epithelioid cells in ectopic testis, which were suggestive of tuberculosis of ectopic testis (Figure 2). After this unusual finding, urine was sent for acid fast bacilli, which was negative. Patient was kept on three drugs antituberculous therapy consisting

*Department of Pediatric Surgery¹/General Surgery²,
Liaquat University of Medical and Health Sciences (LUMHS),
Jamshoro, Hyderabad.*

Correspondence: *Dr.Nandlal Kella, H.No. 22-B, Al-Meeran
Town, Behind Citizen Plaza, Qasimabad, Hyderabad.
E-mail: nckella@yahoo.com*

Received August 23, 2007; accepted March 04, 2008.

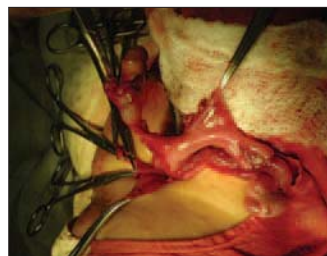


Figure 1: Persistent mullerian duct structures and transverse testicular ectopia.

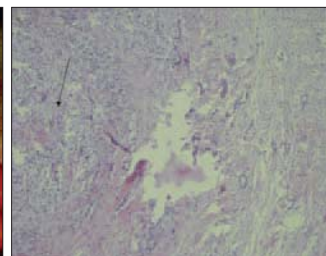


Figure 2: Tuberculous granuloma in the gonads.

of Rifampicin, Isoniazid and Pyrazinamide. Patient is on regular follow-up without any problem.

DISCUSSION

Transverse testicular ectopia is an uncommon anatomical abnormality in which both gonads migrate towards same hemiscrotum. Around 100 cases have been reported in literature. It has been divided into 3 types based on the presence of various associated anomalies, (1) inguinal hernia alone (40-50%); (2) persistent or rudimentary Mullerian duct structures (30%); and (3) other anomalies without Mullerian remnant (inguinal hernia, hypospadias, pseudo-hermaphroditism and scrotal abnormalities, (20%).^{2,3}

Persistent Mullerian duct syndrome is a rare inherited defect of sexual differentiation characterized by failure of regression of Mullerian ducts in males. Approximately, 150 cases have been reported in literature.⁴ In affected individual, uterus and tubes are present because of defective synthesis or action of anti-Mullerian hormone. Actual incidence and prevalence of PMDS in general population is unknown.

Extra-pulmonary tuberculosis constitutes approximately 15-20% of all cases of tuberculosis in immunocompetent cases, while genitourinary tuberculosis constitutes only 8-10% of them.⁵ Tuberculosis of transverse testicular ectopic testis is extremely rare¹ and association of PMDS and tuberculosis of transverse testicular ectopic testis, as was in this case, could not be traced even after intense literature search.

In children, genital tuberculosis is usually the manifestation of quiescent or active pulmonary tuberculosis or generalized tuberculosis. Tuberculosis of male genital tract is extremely uncommon in pediatric population, even in endemic areas. This is because the average time interval between the development of primary lesion and genital manifestation is rarely less than 5 years and usually more than 10 years.⁶ Genital tuberculosis may present in isolation as reported by Milleneria *et al.*,⁷ which is same in this case. Testicular involvement is usually due to local spread from epididymis, retrograde infection from prostatic urethra, lymphatic spread and early or late hematogenous dissemination. Cabral *et al.*⁸ reported that a higher frequency of isolated lesions in children favoured the possibility of hematological spread of infection, while adults seem to develop tuberculous epididymo-orchitis as a result of spread from urinary tract. Lymphatic spread, although has not been observed significant in clinical setting, but has been shown to be of importance in experimental animals.

It is believed that intact tunica vaginalis in TB testis (as in this case) indicates retrograde spread from epididymis and distorted tunica is a result of direct tuberculous extension of epididymis.⁹ It is likely that primary site of infection in our case might be inactive pulmonary lesion and hematogenous spread led to genital involvement.

Presentation of genital tuberculosis is variable such as; asymptomatic (as in this case), testicular swelling or urinary manifestation.¹⁰ Histopathology is the best tool for diagnosis of genitourinary tuberculosis, while presence of acid fast bacilli in urine is a perfect diagnostic method, but they are uncommonly detected. In this case, histopathology favoured the tuberculosis. Treatment of genital tuberculosis is antituberculous regimen consisting of Rifampicin, Isoniazid and Pyrazinamide, was given to the patient.

Genital tuberculosis is rare in children though it may affect the transverse testicular ectopic testis without clinical signs and symptoms. Histopathology, in case of PMDS and transverse testicular ectopia, may be worthwhile in gonadal diagnosis as well as to detect other rare pathology.

REFERENCES

1. Debnath PR, Tripathi R, Agarwal LD, Malik E, Sharma SB. Tuberculosis in transverse testicular ectopic testis, a diagnostic dilemma: case report. *Indian J Tuberc* 2006; **53**:27-9.
2. Sarin YK, Nagdeev NG. Transverse testicular ectopia. *Indian Pediatr* 2005; **42**:293-4.
3. Kella N, Rathi PK, Memon S, Ahuja P, Memon SA. Persistent mullerian duct syndrome with transverse testicular ectopia. *J Coll Physicians Surg Pak* 2005; **15**:119-20.
4. Shamim M. Persistent Mullerian duct syndrome with transverse testicular ectopia presenting in an irreducible inguinal hernia. *J Pak Med Assoc* 2007; **57**:421-3.
5. Sharma SK, Mohan A. Extra-pulmonary tuberculosis. *Indian J Med Res* 2004; **120**: 316-53.
6. Madan N, Chopra K, Jain V. Tuberculous epididymo-orchitis in a three-year-old child. *Indian J Tuberc* 1994; **41**:101-3.
7. Milleneria J. Tuberculous epididymitis in an infant. *S Afr Med J* 1982; **57**:76-8.
8. Cabral DA, Johnson HW, Coleman GU, Nigro M, Speert DP. Tuberculous epididymitis as a cause of testicular pseudomalignancy in two young children. *Pediatr Infect Dis* 1985; **4**: 59-62.
9. Riehle RA Jr, Jayaraman K. Tuberculosis of testis. *Urology* 1982; **20**: 43-6.
10. Joual A, Rabii R, Guessous H, Benjelloun M, el Mrini M, Benjelloun S. Isolated testicular tuberculosis: report of a case. *Ann Urol (Paris)* 2000; **34**:192-4.

.....★.....