

# Sigmoid Sinus Thrombosis with Cerebellar Tuberculous Abscess: A Rare Case of Chronic Headache with Vision Loss

Ahmed Tanjimul Islam, Kafil Uddin, Ahmed Ali, Pijush Kumar Kundu, Munzur Alahi and Mukul Kumar Sarkar

*Department of Neurology, Rajshahi Medical College Hospital, Rajshahi, Bangladesh*

## ABSTRACT

Cerebral venous sinus thrombosis (CVST) is a rare form of brain stroke which is often misdiagnosed. We present a case of CVST due to cerebellar tuberculous abscess. A 41-year female patient was admitted with chronic occipital headache, diminished vision, and fever. The initial brain CT scan was negative, but subsequent imaging (MRI with MRV) showed cerebellar abscess with sigmoid sinus thrombosis. Fundoscopy revealed bilateral optic atrophy. Marked improvement (subjective and objective) was noted after 4 weeks with anti-tuberculosis chemotherapy and anticoagulants. Vision loss was irreversible due to optic atrophy. The case is extremely rare due to the location, rare causative organism (tuberculosis) and complex clinical presentation (occipital headache with vision loss).

**Key Words:** *Cerebral venous sinus thrombosis, Cerebellar abscess, Tuberculosis, Headache, Vision loss.*

**How to cite this article:** Islam AT, Uddin K, Ali A, Kundu PK, Alahi M, Sarkar MK. Sigmoid sinus thrombosis with cerebellar tuberculous abscess: a rare case of chronic headache with vision loss. *J Coll Physicians Surg Pak* 2019; **29** (Supplement 2):S109-S111.

## INTRODUCTION

Cerebral venous sinus thrombosis (CVST) is a rare disease comprising only 0.5-1% of stroke.<sup>1</sup> Initial presentation of CVST can be non-specific with various signs and symptoms.<sup>2</sup>

Due to rarity of the disease and various presentations, CVST is often underdiagnosed or misdiagnosed by the physicians. Headache is the commonest presentation in CVST.<sup>3</sup> Seizures, unilateral or bilateral hemiparesis and papilledema are the other presentations commonly found in CVST.<sup>2,3</sup> Commonest etiologies are oral contraceptive pills (OCP), pregnancy, puerperium, dehydration and infections.<sup>3</sup> However, more than half of the CVST patients can have multiple risk factors and etiologies.<sup>3</sup>

Previously, very few cases of sigmoid sinus thrombosis are reported.<sup>4-6</sup> Infectious organisms, as etiological factors, were found only in 6-12% CVST cases.<sup>6</sup> Tuberculosis (TB) had never been reported as an infectious agent for CVST, previously. Very few cases reported vision loss in CVST, previously.<sup>5,6</sup> Therefore, we present this rare case of sigmoid sinus thrombosis due to tuberculosis, presenting with headache and vision loss.

## CASE REPORT

A 41-year female normotensive and non-diabetic patient presented with headache and fever for 6 months with

dimness of vision for 2 months. No history of TB contact or exposure was obtained. The headache was continuous, moderate in intensity, hampering her regular activities, more marked in the occipital region, radiated towards neck and was associated with nausea. The fever was intermittent, low-grade and partially relieved by taking acetaminophen.

Nine months back, she was diagnosed by a general physician (GP) as left-sided chronic suppurative otitis media (CSOM) and was treated conservatively with antibiotics and pain killers. After that, the ear discharge was cured but she had developed headache which was more marked in the occipital region; moderate initially, and severe later.

Physical examination revealed positive findings in eyes bilaterally with visual acuity of 6/18, loss of color vision and horizontal nystagmus in both the eyes. No abnormality was detected on examination of pupil, eye movements, and other cranial nerves. Normal vital signs with normal other neurological examination (other cranial nerves, focal signs, motor, sensory and cerebellar signs) were noted. The patient was pale-looking with temperature of 99.4°F. Other general and systemic examinations revealed no abnormality. Ophthalmoscopic examination (fundoscopy) revealed optic atrophy (secondary atrophy) due to chronic bilateral papilloedema (Grade 3).

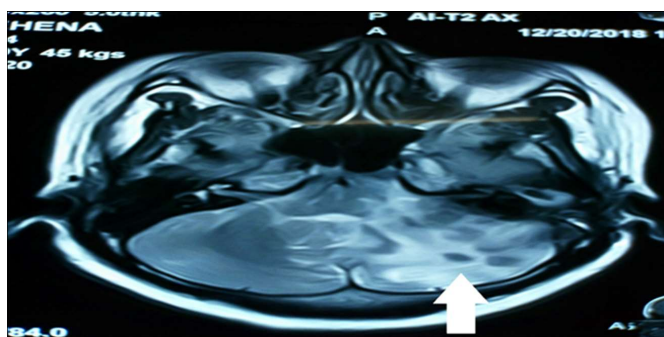
Routine investigations revealed mild anemia (Hemoglobin of 9.5 gm/dl), high ESR (90 mm in 1st hr) and high C-reactive protein (14 mg/l). The hypercoagulability profile (Prothrombin time, INR, APTT, homocystine, protein C, protein S, anti-thrombin and lupus screening) was found within normal limits. Initial brain computed tomography (CT) scan done within 6 months of symptom onset was

*Correspondence to: Dr. Ahmed Tanjimul Islam, Department of Neurology, Rajshahi Medical College Hospital, Rajshahi, 6000, Bangladesh*

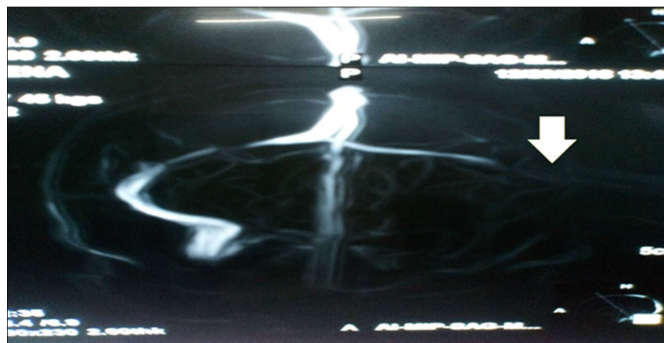
*E-mail: droveosomch@gmail.com*

*Received: February 06, 2019; Revised: July 09, 2019;*

*Accepted: July 20, 2019*



**Figure 1:** MRI of brain (T1 with contrast) showing abscess in the cerebellum (left lobe).



**Figure 2:** MRV of brain showing absent flow void in left sigmoid sinus, indicating sigmoid sinus thrombosis (white arrow).

found normal. Magnetic resonance imaging (MRI) of brain and magnetic resonance venography (MRV) was performed for further brain imaging workup. MRI showed cerebellar abscess in left lobe (Figure 1) and MRV revealed significant venous flow obstruction in the left sided sigmoid sinus (Figure 2). FNAC (fine needle aspiration cytology) from left mastoid bone revealed caseating granulomatous inflammation (tuberculosis). Mycobacterium TB (MTB) target DNA was detected (high range) and rifampicin target DNA (resistance) was not detected on gene expert (pus).

CVST of left sigmoid sinus due to infection (TB) was diagnosed. Anti-TB chemotherapy (2 months Initial phase with 4 fixed drug regimen followed by 10 months continuation phase with 2 fixed drug regimen) was started according to category 1 national guideline anti-TB protocol. Anticoagulant (enoxaparin 1 mg/kg subcutaneous followed by oral warfarin) was started and headache was cured after 3 weeks without pain-killers. Follow-up international normalized ratio (INR) was between 2 and 3. Headache, fever and other symptoms improved significantly within 4 weeks. There was no significant improvement in vision due to bilateral optic atrophy (chronic papilledema). Follow-up MRV after 4 weeks revealed significantly improved flow in left sigmoid sinus.

### DISCUSSION

As CVST is a rare cause of stroke, physicians have a difficulty in diagnosis, which leads to delay in diagnosis.

The median delay from initial symptom to diagnosis is seven days.<sup>2,3</sup> High clinical suspicion is extremely important for the early diagnosis of CVST. Routine blood work-up and brain imaging studies (preferably MRI with MRV) are helpful to diagnose CVST location, etiology and to exclude the other differential diagnoses.<sup>7</sup>

CT scan of brain is the commonest imaging done in the hospital setting which can detect CVST.<sup>7</sup> However in 10-40% cases, CT scan brain may fail to detect CVST.<sup>7,8</sup> MRI is more sensitive for CVST than CT scan.<sup>8</sup> Absence of normal flow void in T1 and T2 image is the commonest finding in all CVST cases.<sup>8</sup> MRV gives the most accurate finding in CVST to find location of blockage.<sup>7,8</sup> Commonest cause for CVST is pro-thrombotic condition.<sup>9</sup> So, routine blood tests for coagulation need to be done (factor V Leiden, protein C, S, anti cardiolipin and lupus anticoagulants).

For management of CVST, the cause should be treated first. However, in 10-15% of cases no specific cause is detected.<sup>10</sup> Chemotherapy for infection and an anti-coagulant (subcutaneous enoxaparin or oral warfarin) is the ultimate choice for the management of thrombosis.<sup>10</sup> In clinical practice, CVST due to infection is rare; and with TB, makes this case an extremely rare one. Anti-TB chemotherapy is given for at least one year in cerebral TB 2 (Anti-TB national guideline, category 1). Duration of anticoagulant treatment is selected by provoked, non-provoked and recurrence of thrombosis incidence. For provoked (infectious) thrombosis 6 to 12 months anti-coagulant therapy is chosen.<sup>5,10</sup> INR 2-3 is the preferred range for this anti-coagulant therapy.<sup>10</sup>

As CVST is a rare and severe disease, the physicians should have a high degree of suspicion to diagnose it in the early stage. A routine laboratory and image workup is necessary to make an early diagnosis (with risk factor and etiology). MRI with MRV is the best modality to diagnose and follow-up cerebral thrombosis. Blood analysis and cytological workup will confirm the infectious organism. This CVST case in rare location (sigmoid sinus) with rare organism (TB) and atypical presentation makes it imperative to investigate it with all clinical, laboratory, imaging and cytological methods for proper management.

### PATIENT'S CONSENT:

Consent has been taken and signed from the patient.

### CONFLICT OF INTEREST:

Authors declared no conflict of interest.

### AUTHORS' CONTRIBUTION:

ATI: Concept of the manuscript, study design, literature search, manuscript writing, patient follow-up.

KU: Study design, literature search, data collection.

AA: Concept of the manuscript, statistical analysis, manuscript revision

PKK: Study design, manuscript writing, manuscript revision.

MA: Stastical analysis, manuscript revision.

MKS: Literature search, manuscript revision.

## REFERENCES

1. Bousser MG, Ferro JM. Cerebral venous thrombosis: An update. *Lancet Neurol* 2007; **6**:162-70.
2. Filippidis A, Kapsalaki E, Patramani G, Fountas KN. Cerebral venous sinus thrombosis: Review of the demographics, pathophysiology, current diagnosis and treatment. *Neurosurg Focus* 2009; **27**:E3.
3. Stam J. Thrombosis of the cerebral veins and sinuses. *N Engl J Med* 2005; **352**:1791-8.
4. Bradley DT, Hashisaki GT, Mason JC. Otogenic sigmoid sinus thrombosis: What is the role of anticoagulation?. *Laryngoscope* 2002; **112**:1726-9.
5. Scherer A, Jea A. Pediatric otogenic sigmoid sinus thrombosis: Case report and literature reappraisal. *Glob Pediatr Health* 2017; **4**:2333794X17738837.
6. Ulanovski D, Yacobovich J, Komreich L, Raveh E. Pediatric otogenic sigmoid sinus thrombosis: 12-year experience. *Int J Pediatr Otorhinolaryngol* 2014; **78**:930-3.
7. Walecki J, Mruk B, Nawrocka-Laskus E, Piliszek A, Przelaskowski A, Sklinda K. Neuroimaging of cerebral venous thrombosis (CVT) – old dilemma and the new diagnostic methods. *Pol J Radiol* 2015; **80**:368-73.
8. Alshoabi SA. Cerebral venous sinus thrombosis: A diagnostic challenge in a rare presentation. *Brain Circ* 2017; **3**:227-3.
9. Ferro JM, Canhão P, Stam J, Bousser MG, Barinagarrementeria F. ISCVT Investigators. Prognosis of cerebral vein and dural sinus thrombosis: Results of the International study on cerebral vein and dural sinus thrombosis (ISCVT). *Stroke* 2004; **35**:664-70.
10. Saposnik G, Barinagarrementeria F, Brown RD Jr, Bushnell CD, Cucchiara B, Cushman M, *et al*. Diagnosis and management of cerebral venous thrombosis: A statement for healthcare professionals from the American Heart Association/American Stroke Association. *Stroke* 2011; **42**:1158-92.

