

Hydatid Cyst of the Pancreas Mimicking Neoplasm

Hady Khoshmohabat¹, Javad Akhavan Moqadam², Saeedeh Zienab Sohrabi³,
 Mohammad Hosein Kalantar Motamedi¹ and Taghi Azizi³

ABSTRACT

Hydatid disease is a cyclozoonotic infection caused by the cestode genus *Echinococcus*. It occurs throughout the world and is especially common in sheep- and cattle-raising regions of Africa, Australia, New Zealand, India, the Middle East, South America, and the Mediterranean. The incidence of humans infected with hydatid disease is approximately 1-2:1000. It is higher in rural areas. Infection occurs via ingestion of infected meat. Hydatidosis is caused by sheep and cattle ingesting tapeworm eggs in dog feces. These eggs hatch in the duodenum and invade the liver, lungs, or bones of sheep and cattle. Humans are infected by ingesting the infected meat from these animals. In the organs, the embryo transforms into a cyst, which develops the germinal epithelium that produces capsules, larval forms, and eventually the infectious scolices. Although hydatid cyst of the pancreas is rare, it must be considered in the differential diagnosis of pancreatic lesions. We present a rare case.

Key Words: *Hydatid disease. Pancreas. Echinococcus. Cyst.*

INTRODUCTION

Hydatid cysts may develop in almost any organ of the body. It is very rare in the pancreas. It has been reported to affect the pancreas in only 0.1 - 2% of patients with hydatid disease.³ Hydatidosis is an endemic disease caused by *Echinococcus granulosus*. The eggs of the worm being excreted in the feces of infected dogs.⁴

Intermediate hosts are usually cows, sheeps and pigs, whereas human beings are accidental intermediate hosts. After ingestion, eggs hatch in the jejunum. Larvae enter the portal system through intestinal mucosa. The final destination in 50% of cases are the liver followed by lungs, spleen, bone and brain; very rarely the breast, muscles and pancreas get involved.⁵ Substantiating a precise diagnosis clinically may be difficult and thus, must be confirmed by histopathology.

CASE REPORT

A 33 years old woman presented with abdominal discomfort of 4 months duration and weight loss (8 kg in 6 months). On physical examination, there was a palpable non-tender mass in left upper quadrant. Abdominal sonography suggested a retroperitoneal mixed echo-mass in the left lateral area of the epigastrium. CT scan revealed an 8 cm multiloculated mass in the pancreas. A cystic adenocarcinoma or hydatid cyst were included in the differential diagnosis

(Figure 1A). All laboratory studies were normal except CA19-9 which was increased (3 µg/dL with reference range 0 - 19). On abdominal exploration, we found a mass in the distal portion of the pancreas with dense adhesion to the stomach and the large bowel. Distal pancreatectomy with splenectomy was done. Histopathologic findings revealed a well defined creamy whitish mass measuring 11 x 7 x 3 cm. The external surface was smooth. On opening the sample, a multiloculated cyst was seen which contained clear fluid. Wall thickness was 4 mm. This cyst was attached to pancreas and with fibrous adhesion to the spleen. (Figure 1B). The microscopic examination revealed a typical hydatid cyst which contained some scolices with hooklets (Figure 1C).

DISCUSSION

Hydatid cysts of the pancreas although rare, must be considered in the differential diagnosis of pancreatic and peripancreatic cysts. Clinical presentation of hydatid disease of the pancreas is the result of pressure by the cyst on adjacent structures. Signs and symptoms depend on the size and anatomical location of the cyst. The location of the hydatid cyst in the pancreas is variable (50% are at the head, 35% within the corpus and 15% in the tail of the organ).⁴

Cyst in the head of the pancreas may cause obstructive jaundice⁵, acute pancreatitis,⁶ and recurrent acute or chronic pancreatitis.⁷ Cyst located in body can be asymptomatic or can present as only an abdominal lump.⁴ Portal hypertension has also been reported due to a pancreatic hydatid cyst.⁸

A specific diagnosis is seldom made pre-operatively unless hydatid disease is suspected⁸ and modern serology tests are positive.

Department of Trauma Research Center¹ / Surgery² /
 Pathology³, Baqiyatallah University of Medical Sciences,
 Tehran, IR Iran.

Correspondence: Prof. Mohammad Hosein Kalantar Motamedi,
 Shariati-Roumi Bridge Sharifimanesh No. 34, Apt 17, Tehran, Iran.
 E-mail: motamedical@lycos.com

Received: May 18, 2011; Accepted: August 30, 2013.

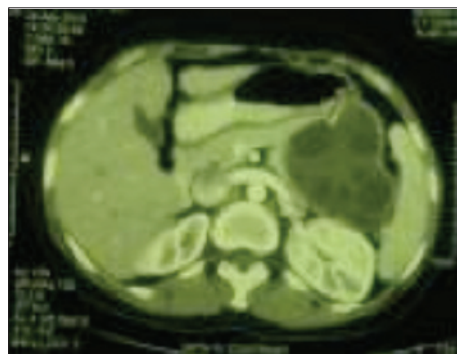


Figure 1(A): CT scan: a multiloculated mass in distal of pancreas(arrow).

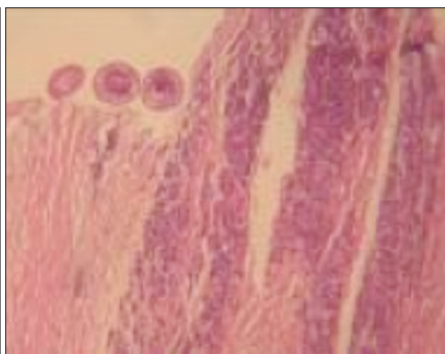


Figure 1(B): Wall of hydatid cyst attached to pancreatic tissue (H & E x 10).

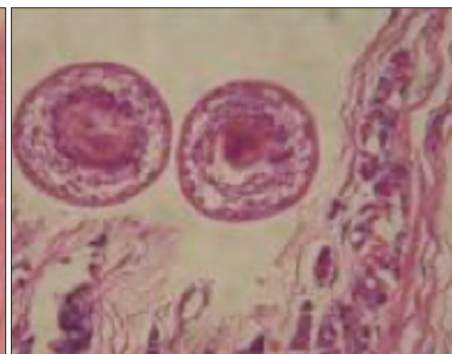


Figure 1(C): Scolices of *Echinococcus* with hooklets (H & E x 40).

Tests are positive in up to 80% of abdominal hydatid cysts. It has been recommended to obtain a fine needle aspiration biopsy for definite diagnosis and for appropriate treatment planning.⁹ However, peritoneal dissemination of viable parasitic scoleces may occur. If the lesion is malignant, percutaneous CT or ultrasound-guided needle aspiration carries the potential risk of peritoneal dissemination of neoplastic cells. Current definitive treatment of hydatid disease is surgical excision.⁸

Surgical management of the pancreatic hydatid cyst is dependent upon the location of the hydatid cyst and communication with pancreatic duct. Pericystectomy (total or partial) with drainage of the residual cavity (mostly omental packing) may be the technique of choice.^{4,10} Provided there is no communication between the cyst cavity and the bile or pancreatic ducts, scolical agents-most common hypertonic (20%) saline-10 are injected into the cyst contents before complete excision of the cyst. However, if the cyst is located close to vital anatomical structures, removal of cyst contents with or without partial cystectomy is the preferred treatment.⁸

If there is a known pancreatic fistula before surgery (during pre-operative cholangiography)⁹ or a communication between the cyst and pancreatic or biliary ducts seen during operation, cystoenterostomy is done; cystogastrostomy is more frequent,¹⁰ although Roux-en-Y pancreaticojejunostomy is advised in some situations.⁸ Hydatid cysts that are located in the tail of the pancreas, a distal pancreatectomy with,⁸ or without,⁶ splenectomy is recommended. Combined medical

treatment using albendazole, percutaneous drainage and laparoscopic resection of the cyst have also been reported.¹⁰

REFERENCES

1. Mortazavi SH, Motamedi MH. Primary hydatid cyst of the maxillary sinus: case report. *Gen Dent* 2008; **56**:444-6.
2. Santin M, Fibrello A, Vicidomini G, Perrone A. A home-made device for safe interoperative aspiration of pulmonary hydatid cysts. *Interact Cardiovasc Thorac Surg* 2008; **7**:365-7.
3. Ashok Borisa, Girish D, Bakhshi, Mukund B Tayade, Narendra H Pawar, Narendra N Nikam, Satyajeet Pathrikar. Hydatid cyst of pancreas. *Bombay Hospital J* 2009; **51**:88-90.
4. Krige EJ, Mirza K, Bornman PC, Beningfield SJ. Primary hydatid cysts of the pancreas. *SAJS* 2005; **43**:37-40.
5. Jai SR, El Hattabi K, Bensardi F, Chehab F, Khaiz D, Bouzidi A. Primary hydatid cyst of the pancreas causing obstructive jaundice. *Saudi J Gastroenterol* 2007; **13**:191-3.
6. Heis HA, Bani-Hani KE, Elheis MA. Primary hydatid cyst of the pancreas. *Acta Chir Belg* 2009; **109**:626-8.
7. Abdelmalek O, Elboudhaddouti H, Ibnmajdoub KH, Mazaz K, AitTaleb K. Primary hydatid cyst of the pancreas with a hepatic pedicle compression. *Cases J* 2009; **2**:201.
8. Bedioui H, Chebbi F, Ayadi S, Daghfous A, Bakhtri M, Jouini M, et al. Primary hydatid cyst of the pancreas: diagnosis and surgical procedures: report of three cases. *Gastroenterol Clin Biol* 2008; **32**:102-6. Epub 2008 Mar 4.
9. Moosavi SR, Khajoue-Kermany H. Epigastric mass due to a hydatid cyst of the pancreas: a case report and review of the literature. *J Pancreas* 2007; **8**:232-4.
10. Ibis C, Albayrak D, Altan A. Primary hydatid disease of pancreas mimicking cystic neoplasm. *South Med J* 2009; **102**: 529-30.

....☆....