

Plexiform Neurofibroma of Uterus: A Rare Manifestation of Neurofibromatosis 1

Rafia Shahzad¹ and Farhana Younas²

ABSTRACT

Neurofibromatosis type 1 (NF1) rarely affects the female genital system. Plexiform neurofibromas are congenital lesions that occur exclusively in patients with neurofibromatosis type I. The vulva is the most frequent genital organ to be affected, whereas vaginal, cervical, uterine, and ovarian neurofibromas have also been reported only rarely. We present an 8 years old girl with plexiform neurofibroma primarily involving genital system.

Key Words: Neurofibromatosis type 1. Plexiform neurofibroma. Uterus. Von Recklinghausen disease. MRI.

INTRODUCTION

Neurofibromatosis type 1 (NF1) also known as peripheral neurofibromatosis or von Recklinghausen disease is a systemic disease of autosomal dominant inheritance. It affects all races and either gender equally, occurring one in every 3000 of the population.¹⁻³ Patients with NF1 are afflicted with a diverse group of lesions that are predominantly neuroectodermal or mesenchymal in origin.

A characteristic feature of NF1 is the occurrence of peripheral nerve sheath tumours, the neurofibromas, which are the most common cause of symptoms and disfigurement in NF1. The term plexiform neurofibroma is used to describe a network like growth of tumour involving multiple fascicles of a nerve, leading to a diffuse mass of thickened nerve fibers surrounded by proteinaceous matrix.⁴ Genitourinary neurofibroma is rare with fewer than 40 paediatric cases of genitourinary neurofibromatosis reported in the literature.³ Neurofibromatosis involving female genital tract is uncommon.

We present a case of plexiform neurofibroma primarily involving the uterus in a young girl.

CASE REPORT

An 8 years old girl presented with history of dull lower abdominal pain and mild abdominal distention for couple of weeks. On examination, the girl had multiple *café-au-lait* pigmentations over her trunk and a firm slightly mobile supra pubic mass. No similar lesions were seen on her parents or siblings, and her family history was unremarkable. Ultrasound abdomen and pelvis revealed

a heterogeneously echogenic mass posterior to bladder. Uterus was not separately visualized. She underwent contrast-enhanced CT scan of pelvis which showed a large soft tissue mass iso dense to the adjacent skeletal muscle involving the uterus and extending into vagina displacing urinary bladder anteriorly (Figure 1). Subsequently MRI was performed which revealed an inhomogeneous signal intensity mass with lobulated margins involving uterus and extending into vagina and labial folds. The mass had foci of target like appearance on T2-weighted MR images, with central low signal intensity and peripheral high signal intensity (Figure 2 and 3). Based on these clinical and imaging features diagnosis of plexiform neurofibroma was made.

Patient underwent laparoscopy which revealed an infiltrating tumour involving the entire uterus extending into the vagina. Bladder and rectum were spared. Laparoscopic biopsy was performed. Histology showed numerous nerve bundles with proliferating Schwann cells and fibroblasts suggesting plexiform neurofibroma. Surgical excision was refused and no follow-up is available as yet.

DISCUSSION

Plexiform neurofibromas are congenital lesions that occur exclusively in patients with NF1 and they do have potential for malignant transformation. The term ropelike has been applied to the macroscopic appearance of plexiform neurofibromas that involve non-branching nerves, and the term 'bag of worms' has been used to refer to plexiform neurofibromas of highly branching nerves.⁵

Plexiform neurofibromas can be found throughout the body. Some are cutaneous or in the subcutaneous tissue, and they can be visible and palpable due to thickening of the dermis. Others are located in deeper soft-tissue locations, such as the abdomen or pelvis, in which case the neurofibromas may be undetectable unless they cause secondary mass effect.

¹ Department of Radiology, INMOL Hospital, Lahore.

² Department of Radiology, Children Hospital, Lahore.

Correspondence: Dr. Rafia Shahzad, 3-M Johar Town, Lahore.

E-mail: rshk18@hotmail.com

Received: August 24, 2012; Accepted: February 03, 2014.

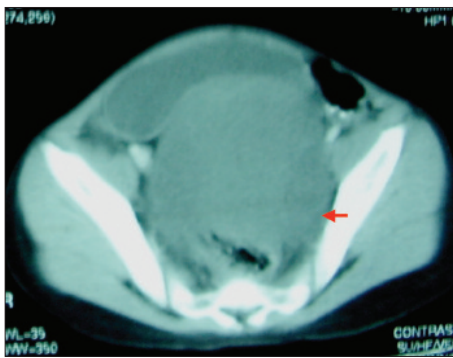


Figure 1: Heterogeneously enhancing pelvic mass displacing urinary bladder and rectum (arrow).

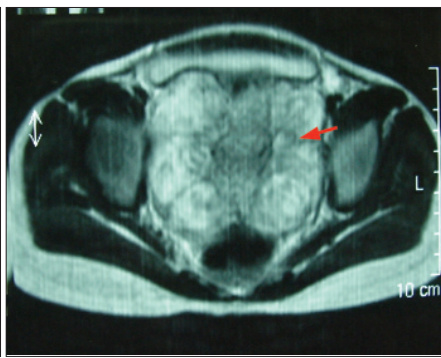

Figure 2: Heterogeneously hyperintense lobulated mass involving uterus with areas of target like appearance (central low signal intensity and peripheral high signal intensity-typical of neurofibroma) [arrow].

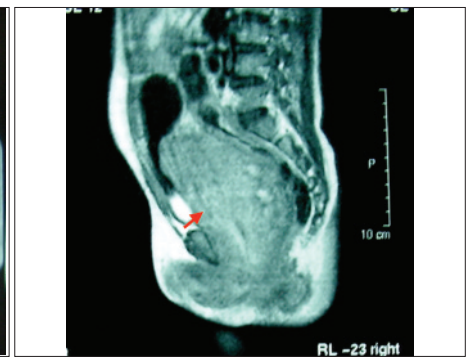


Figure 3: Heterogeneously enhancing mass involving uterus and extending into vagina and labial folds (arrow).

Genitourinary neurofibromas are rare. The bladder is the most common genitourinary organ affected by neurofibromas. Neurofibromas appear to be derived from the pelvic, vesical, and/or prostatic nerve plexuses, which form a continuous network, allowing the plexiform neurofibroma to spread and involve multiple organs.

The female genital system is rarely affected during NF1. Wei *et al.* reported the case of a 39-year-old woman with a plexiform NFB of the uterus associated with adenomyosis and uterine leiomyoma.⁶ NFBs are most commonly located on the vulva, but other locations such as the clitoris, vagina, myometrium and ovary have occasionally been reported. There are also very few cases of uterine cervical neurofibromas.

In this patient, the plexiform neurofibroma is primarily involving the genital system (uterus, vagina and labial folds). Bladder and rectum are largely spared whereas in many of the previously reported cases urinary system is also affected along with genital system. Differential diagnoses of uterine NFB include myxoma, schwannoma, leiomyoma.⁷

The MR imaging features of neurofibromas are characteristic and can be helpful in confusing cases and in the evaluation of a mass in a patient with known NF1. Neurofibromas have characteristically low signal intensity on T1-weighted images and heterogeneous high signal intensity on T2-weighted images. They typically have a target like appearance on T2-weighted MR images. The target like MRI appearance of deep neurofibromas reflects their histologic composition. Woodruff describes deep plexiform neurofibroma as microscopically consisting of a nerve or nerve fascicle distended by tumour cells, embedded in a rich myxoid matrix. Longitudinal bundles of residual nerve fibers are often centrally situated in the neurofibroma. This

architecture could account for the centrally T2 hypointense (nerve fibers) and peripherally T2 hyperintense (myxoid) appearance of these target like lesions.⁴ The areas of low T2 signal enhance following gadolinium administration. The multiplanar capability of MR imaging is also useful for defining the extent of plexiform neurofibromas because they may grow to large sizes and involve adjacent tissue planes and organs.

While excision is the logical treatment, it was refused in this case and since follow-up is not available as yet, it is difficult to predict the outcome at puberty and regarding future fertility.

REFERENCES

1. Thammaiah S, Manjunath M, Rao K, Uma Devi HS. Intraoral plexiform neurofibroma involving the maxilla - pathognomonic of neurofibromatosis type I. *J Pediatr Neurosci* 2011; **6**:65-8.
2. Arute JE, Nwosu P JC, Erah PO. Facial plexiform neurofibromatosis in a 16 years old female from Eastern Nigeria: a rare presentation. *Int J Health Res* 2008; **1**:105-10.
3. Nasir A, Abdur Rehman L, Ibrahim K, Adejoke M, Afolabi J, Adeniran J. Genitourinary plexiform neurofibroma mimicking sacrococcygeal teratoma. *J Surg Tech Case Rep* 2012; **4**:50-2.
4. Lim R, Jaramillo D, Poussaint TY, Chang Y, Korf B. Superficial neurofibroma: a lesion with unique MRI characteristics in patients with neurofibromatosis type 1. *AJR* 2005; **184**: 962-8.
5. Levy AD, Patel N, Dow N, Abbott RM, Miettinen M, Sobin LH. Abdominal neoplasms in patients with neurofibromatosis type 1: radiologic-pathologic correlation. *Radiographics* 2005; **25**: 455-80.
6. Wei EX, Albores-Saavedra J, Fowler MR. Plexiform neurofibroma of uterine cervix: a case report and review of literature. *Arch Pathol Lab Med* 2005; **129**:783-6.
7. Kluger N, Perrochia H, Guillot B. Pelvic mass in Von Recklinghausen's neurofibromatosis: diagnostic issue: a case report. *Cases J* 2009; **2**:191.

