

# Giant Pancreatic Pseudocyst

Syed Aslam Shah, Muhammad Tariq Abdullah, Abdul Hadi Kakar and Muhammad Zubair

## ABSTRACT

A 56 years old man presented with epigastric pain and abdominal distension. He suffered an attack of acute pancreatitis 6 weeks back followed by pseudopancreatic cyst formation. As the cyst kept on enlarging in size despite being on conservative management, the patient was operated after 5 weeks. A huge pancreatic pseudocyst was found containing about 4.5 liters of fluid. Cystogastrostomy was performed and the patient recovered un-eventfully. It was the third largest pancreatic pseudocyst reported so far.

**Key words:** Pancreatic pseudocyst. Giant pseudocyst. Acute pancreatitis. Cystogastrostomy.

## INTRODUCTION

Pancreatic pseudocyst has been recognized as a disease entity for nearly 250 years. Morgani is credited with the earliest description of a pancreatic pseudocyst in 1761. It is a collection of fluid, serum, and haematoma in the lesser sac and its walls without recognizable epithelial lining. However, at some point, most pancreatic pseudocysts connect with pancreatic glandular tissue or ductal system to discharge the contents through the pancreatic duct.<sup>1</sup> Pseudocysts are often single, but may be multiple; and represent more than 75% of cystic lesions of the pancreas.<sup>2</sup> Pancreatic pseudocyst develops in 5-10% cases of acute pancreatitis, and upto 50% of cases of chronic pancreatitis; 3-8% pseudocysts are traumatic in origin.<sup>3</sup> A pseudocysts more than 10 cm in size have been termed as being a giant.<sup>4</sup>

Although pancreatic pseudocyst may be suspected on clinical and laboratory grounds, imaging studies are usually necessary for confirmation. These include ultrasonography, CT scan or MRI. Asymptomatic pseudocysts upto 6 cm in diameter may be safely observed and are usually followed with serial ultrasound or CT scan examinations. Large symptomatic pseudocysts require intervention. Multiple options for drainage are available: endoscopic placement of plastic stent through the stomach or duodenal wall into adjacent cyst; CT or ultrasound guided percutaneous external drainage; or open drainage by cysto-gastrostomy or cysto-jejunostomy. In the absence of life threatening complications, elective surgery is usually delayed until the cyst has developed a mature wall that will hold suture line at the time of repair; usually by 4-6 weeks.<sup>5</sup>

*Department of General Surgery, Pakistan Institute of Medical Sciences, Islamabad.*

**Correspondence:** Prof. Syed Aslam Shah, House 352, Street 33, F-11/2, Islamabad.

E-mail: draslamshah@gmail.com

Received December 07, 2010; accepted January 19, 2012.

Acute abdomen is a common surgical emergency encountered in general surgical practice. There should be a high index of suspicion for acute pancreatitis, the incidence is around 4% in local studies.<sup>6</sup> The risk of complications in the patients suffering from pancreatitis is around 30%. Amongst those developing complications, about 5% develop local complications like pseudocyst, abscess etc. while rest suffer systemic complications including sepsis, adult respiratory distress syndrome.<sup>7</sup>

This report describes a giant pancreatic pseudocyst in a male.

## CASE REPORT

A 56 years old man presented to the Surgical Clinic at the Pakistan Institute of Medical Sciences, Islamabad, with complaints of abdominal pain and mass in the abdomen. Patient was in normal state of health 2 months back, when he developed severe abdominal pain which was non-radiating, associated with multiple episodes of vomiting and was not associated with aggravating or relieving factors. There was a large, firm, immobile mass in upper abdomen; that was non-tender and had smooth surface. Investigations revealed it to be a pancreatic pseudocyst. Open surgical internal drainage was planned but deferred to give appropriate time for maturation of the cyst wall.

Patient reported after 5 weeks with a huge mass extending from epigastrium to right hypochondrium and down to the right iliac fossa. Ultrasound showed a huge fluid collection, the size was not measurable on USG. Upper gastrointestinal endoscopy showed "gastric compression by the mass, so much that the antrum was compressed into a narrow channel, and pylorus mildly deformed; the duodenum was normal. CT scan revealed a huge pseudo-pancreatic cyst measuring 25 x 17 cm with multiple large fluid containing areas seen posterior to the stomach, extending from splenic hilum towards right sub-hepatic and right para-vertebral region. The pancreas was not visualized and there was mild right sided pleural effusion (Figure 1 and 2).

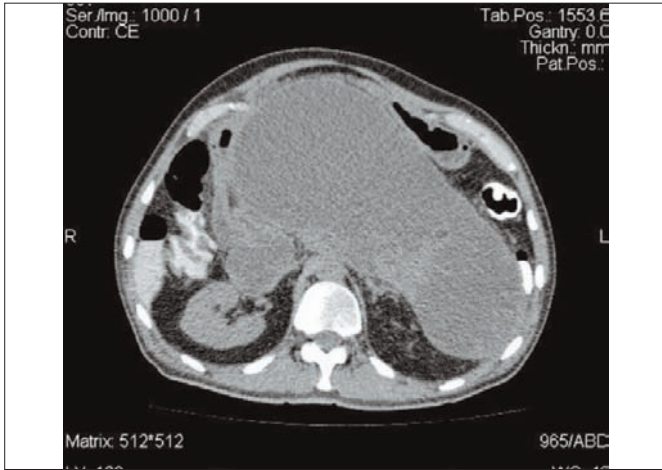


Figure 1: CT scan of the abdomen showing huge pseudocyst.

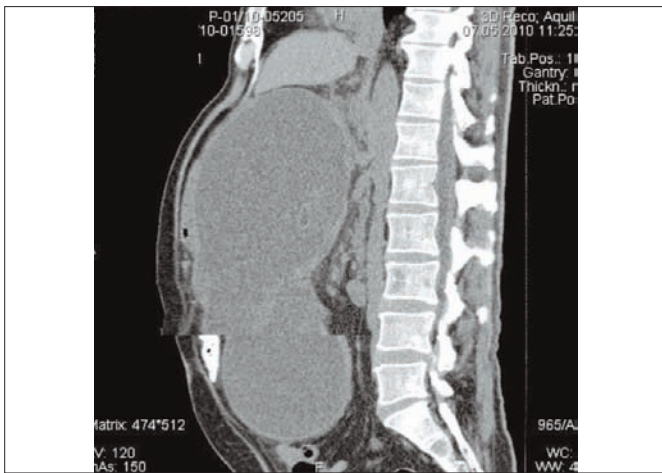


Figure 2: Sagittal section of the CT scan showing craniocaudal extent of giant pseudocyst.

The abdomen was explored through a midline incision. A huge cyst was found extending from epigastrium to paraumbilical region and right hypochondrium to left para-vertebral region. A 5 cm transverse incision was made on the anterior wall of the stomach near the greater curvature. Then posterior wall of the stomach and the cyst were opened. About 4.5 liters of turbid fluid was drained and cysto-gastrostomy was performed. Anterior gastrostomy was closed in two layers. Postoperative recovery was uneventful. Follow-up ultrasound of abdomen and pelvis were normal. Patient was discharged on the 10<sup>th</sup> postoperative day.

### DISCUSSION

Large pancreatic pseudocyst is now infrequently seen due to the availability of modern and sophisticated diagnostic and therapeutic tools. Previously clinical examination, barium studies, laparotomy and angiography only detected cysts big enough to cause morphologic abnormalities in adjacent viscera. Factors found to reduce the likelihood of spontaneous resolution

are multiplicity of cysts, location near the tail of the pancreas, thick wall, and a communication with the pancreatic duct with an associated proximal stricture of the pancreatic duct. This becomes evident by increasing size of the cyst on follow-up examinations. Severity of pancreatitis as well as extent of pancreatic necrosis is also known to influence spontaneous resolution rate.<sup>8</sup> Many conditions are considered in the differential diagnosis of pancreatic pseudocyst, including subphrenic abscess, cysts of the omentum and mesentery, duplication of the gastrointestinal tract, a distended gallbladder, tumours of the pancreas, liver, kidney, and retroperitoneal space, splenomegaly, and even aortic aneurysm.<sup>9</sup>

Currently, three principle forms of management are available: percutaneous drainage, endoscopic drainage, and open surgery. Traditionally, surgery has been the major treatment approach for pancreatic pseudocysts, comprising of internal or external drainage, or excision of the cyst. Internal drainage is usually in the form of a cystogastrostomy, cystoduodenostomy, or a Roux-en-Y-cystojejunostomy. These operative procedures carry a 10-30% morbidity rate, a 1-5% mortality rate and a 10-20% rate of recurrence.<sup>10</sup>

However, surgery has now been challenged by the newer techniques. Percutaneous catheter drainage of symptomatic pancreatic pseudocysts under computed tomography or ultrasound guidance is a valuable alternative to operative management of pseudocyst. It is now an established approach with a number of advocates. Insertion of a pigtail catheter allows the cyst to remain collapsed, and upto 90% of pseudocysts can be drained successfully in this way. Addition of endoscopic ultrasonography (EUS) for endoscopic drainage is a new development and may decrease the risks associated with endoscopic drainage.<sup>11</sup> Because of lower complications and mortality, and the high success rate of percutaneous and endoscopic drainage, surgical intervention should be reserved only for selected cases as in this patient. Resolution rates after surgical and non-surgical methods are comparable, but clinical and technical aspects may mandate either method. Each patient requires an individual, multidisciplinary approach, thereby obtaining optimal treatment outcome.

Giant pseudocysts have been reported in literature. Bozeman in 1882 reported the largest pseudopancreatic cyst which weighed ten (10) kg.<sup>3</sup> Walker *et al.* reported a huge cyst containing about 6100 ml fluid in his study covering 18 years of management of pancreatic pseudocysts.<sup>9</sup> In the present case, the cyst measured 25 x 17 cm and contained 4.5 liters of fluid. After extensive searching of the literature and exploring cyst size mentioned by various authors, this was found to be the third largest pancreatic pseudocyst reported in the literature so far.

## REFERENCES

1. Moosa AR, Bouvet M, Reza AG. Disorders of the pancreas. In: Cuschieri SA, Steel RJ, Moosa AR, editors. *Essential surgical practice*. 4th ed. London: *Arnold*; 2002. p. 477-526.
2. Yeo CJ, Camerone JL. Exocrine pancreas. In: Courtney M, Townsend JR, editors. *Sabiston textbook of surgery*. 16th ed. Philadelphia: *W.B. Saunders*; 2001. p. 1112-43.
3. Warshaw AL, Christison-Lagay ER. Pancreatic cystoenterostomy. In: Baker RJ, Fischer JE, editors. *Mastery of surgery*. 5th ed. New York: *Lippincott Williams & Wilkins*; 2009. p. 1277-98.
4. Oría A, Ocampo C, Zandalazini H, Chiappetta L, Morán C. Internal drainage of giant acute pseudocysts the role of video-assisted pancreatic necrosectomy. *Arch Surg* 2000; **135**:136-40; discussion 141.
5. Bhattacharya S. The pancreas. In: Williams NS, Bulstrode CJK, O'Connell PR, editors. *Bailey and Love's short practice of surgery*. 25th ed. London: *Arnold*; 2008. p. 1130-53.
6. Asif M, Hashmi JS, Almas D. Acute abdomen; causes. *Professional Med J* 2008; **15**:120-4.
7. Waris M, Ayyaz M, Ghafoor T, Fahim T. Management of acute pancreatitis: a hospital based study. *Pak J Surg* 2001; **17**: 27-30.
8. Sandberg AA, Ansorge C, Eiriksson K, Glomsaker T, Maleckas A. Treatment of pancreatic pseudocysts. *Scand J Surg* 2005; **94**: 165-75.
9. Walker LG Jr, Stone HH, Apple DG. Pseudocysts of pancreas: a review of 59 cases. *South Med J* 1967; **60**:389-93.
10. Kohler H, Schafmayer A, Ludtke FE, Lepsien G, Peiper JH. Surgical treatment of pancreatic pseudocysts. *Br J Surg* 1987; **74**: 813-5.
11. Goodfrey EM, Rushbrook SM, Carrol NR. Endoscopic ultrasound: a review of current diagnostic and therapeutic applications. *Postgrad Med J* 2010; **86**:346-53.

