

Big Toe Metastases as First Clinical Sign of Occult Bronchogenic Carcinoma

Naseer Ahmed Mir, Asif Nazir Baba, Suhail Majid, Simon D. Paljor and Javid Ahmed Bhat

ABSTRACT

Metastasis to bone is a common manifestation of malignant tumours. However, metastasis to the bones of the foot is exceedingly rare. It usually arise from genitourinary tract and colon, with the tarsal bones accounting for half of all metastases. We report a rare case of pain and destruction of the distal phalanx of great toe, initially suspected as osteomyelitis, which on biopsy proved to be metastases from a clinically silent bronchogenic carcinoma.

Key words: Foot. Phalanx. Metastases. Bronchogenic carcinoma.

INTRODUCTION

Bone is one of the most important sites for metastasis of tumours.¹ Bony metastases below the elbow and the knee are uncommon. Metastasis involving the distal phalanges of the foot is an even rare entity. Due to the rarity of their occurrence, patients with a clinically silent malignant tumour, presenting with metastatic foot involvement constitute a diagnostic dilemma for the surgeon. They are commonly mistaken for common, less benign conditions like osteomyelitis, gout, rheumatoid arthritis and primary tumours like enchondromas. This delay in diagnosis results in poor outcomes.

We report a patient with a lytic lesion of big toe, initially managed as osteomyelitis, which turned out to be a metastasis from bronchogenic carcinoma. The objective of the case presentation is to highlight the existence of this uncommon condition and to consider metastasis in the differential diagnosis of destructive lesion of phalanges.

CASE REPORT

A 62-year-old male reported to the hospital with a 4 months history of pain and swelling of the right big toe following a trivial trauma. Initially he was managed by a local practitioner with NSAIDs for 2 weeks. Later, he was put on antibiotics by the same doctor with an impression of osteomyelitis. However, there was no relief in pain or the swelling. The patient was non-diabetic and non-hypertensive. He had been smoking two packs of cigarettes for the past 35 years, but did not have any pulmonary symptom.

Department of Orthopaedics, SKIMS Medical College, Srinagar, India.

Correspondence: Dr. Asif Nazir Baba, Shameem Ashiana, S.K. Colony, Anantnag, Jammu and Kashmir, India.

E-mail: drasifbaba@yahoo.co.in

Received August 18, 2009; accepted May 25, 2010.

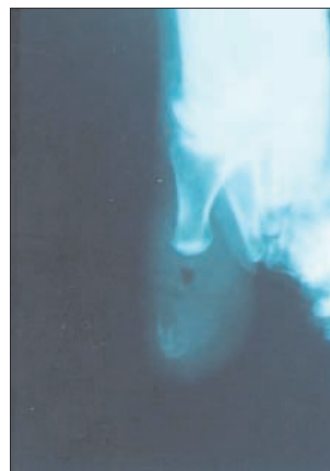

Figure 1: Radiograph of the foot demonstrates the complete destruction of the distal phalanx of great toe

Examination revealed a swollen great toe with tenderness over the distal phalanx. Radiographs of the foot showed complete destruction of the distal phalanx of the big toe with soft tissue shadow (Figure 1). Under ankle block, open biopsy of the lesion was performed. No frank pus could be evacuated and the whole of the distal phalanx was found extensively destroyed. Tissue planes were not visualized and the greyish and friable

material was removed. Histopathological examination of the lesion demonstrated poorly differentiated squamous cell carcinoma (Figure 2). Postoperatively, the chest radiographs revealed a circumscribed mass in left mid-zone. CT scan of the chest showed a thick-walled cavitory lesion in left perihilar region (Figure 3). Bronchoscopy confirmed the diagnosis and bronchial washings showed malignant cells consistent with squamous cell carcinoma. Bone scan revealed multiple skeletal metastases. Amputation of the ray was done through first ray as palliative procedure. The patient died 4 months after the diagnosis was made.

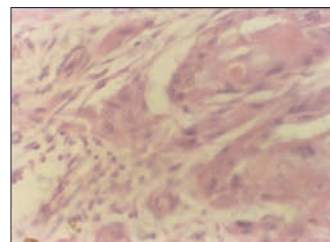


Figure 2: H&E stained slide of the lesion shows features of poorly differentiated squamous cell carcinoma.

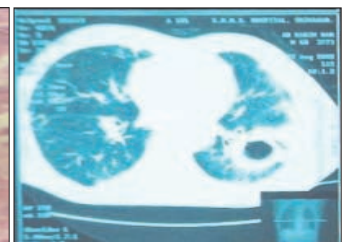


Figure 3: CT scan of chest reveals a thick-walled cavitory lesion in left perihilar region.

DISCUSSION

Although metastatic bone tumours are the most common malignant tumours, acrometastases or metastases to hands and feet are rare, occurring in only 0.5% of cases, hand involvement being twice as common as in feet.^{2,3} Foot metastasis usually involves tarsal bones (50%) and rarely the phalanges.⁴ Metastases to the distal phalanges of toes are exceedingly rare and accounts for less than 0.05% of all metastases.³ Since bone metastases usually develop in regions with abundant red bone marrow, the rarity of involvement of phalanges may be due to insignificant amount of red marrow in these bones.⁵ Foot metastases commonly arise from genitourinary, vesical, renal and uterine malignancies, with lung, prostate and breast being the other common primary sites.⁶ The pathway for the carcinoma to spread to the foot appears to occur through the valveless vertebral venous system, which has extensive communication between the lumbar spinal veins and ileo-femoral system. Trauma also plays a role as the repeated trauma may degrade the resistance of surrounding tissue, allowing the tumour emboli to settle in the skeletal tissue.⁷

The clinical presentation of the metastases involving the phalanges is usually that of a painful, red swollen toe which is tender to touch. This clinical picture is generally mistaken for benign entities like paronychia, osteomyelitis, infected hematoma, gout, rheumatoid arthritis, and even tuberculosis.⁸ The treating physician should always consider metastases in the list of differential diagnosis of a swollen, painful digit in a known malignancy patient. However, a high degree of suspicion and an astute treating physician is required in a patient who presents with acral metastases in an otherwise silent primary tumour. The lack of response to surgical drainage and antimicrobial therapy in a visibly infective lesion should raise suspicion of a neoplastic process.⁶

The initial radiological picture of metastases to phalanges is a diffuse demineralization of the bone which later on leads to destruction of the bone and replacement by a soft tissue mass. The radiological differential diagnosis of a lytic metastatic lesion includes enchondroma, intraosseous ganglion, simple bone cyst, aneurysmal bone cyst, giant cell tumour, giant cell reparative lesions, intraosseous epidermal cyst and gout. However, the most common entity to be considered is chronic infections. The absence of periosteal reaction and of reactive bone goes in favour of malignancy. Further, the metastases do not cross the joint space and even with extensive destruction do not penetrate the joint cartilage.⁹ Technecium bone scan is an effective tool in detecting the extent of distant metastases. However, the definitive diagnosis of meta-

stases is by histological examination of the tissue which resembles the primary lesion, although it can be less differentiated.⁸

The management of the lesion depends upon the type of the primary and the extent of metastases. In patients with an apparently isolated lesion, amputation of a phalanx, digit or ray may be recommended when the expected survival of the patient exceeds a few months.¹ Usually, the disease is widespread by the time the diagnosis is made which excludes any definitive surgery. After diagnosis of peripheral metastases, the average survival of a patient with foot lesion is 3-9 months.³ Due to the poor prognosis and widespread disease, the goal of therapy mostly is palliation of symptoms without adding any of the iatrogenic complications. Radiotherapy, disarticulation and amputation of phalanges, all are described to achieve a goal of pain relief and minimal disability.

As this case illustrates, bone metastases may be the initial sign of an otherwise silent primary malignancy.¹⁰ Although, the acral metastases are rare, the fact that these exist should prompt one to keep this diagnosis in mind. Thus, metastases should be considered as a probable diagnosis in patients with persistent pain and swelling of toes not responding to the usual conservative measures.

REFERENCES

1. Healey JH, Turnbull AD, Miedema B, Lane JM. Acrometastases: a study of twenty-nine patients with osseous involvement of the hands and feet. *J Bone Joint Surg Am* 1986; **68**:743-6.
2. Abrahams TG. Occult malignancy presenting as metastatic disease to the hand and wrist. *Skeletal Radiol* 1995; **24**:135-7.
3. Libson E, Bloom R, Husband J, Stoker D. Metastatic tumours of bones of the hand and foot: a comparative review and report of 43 additional cases. *Skeletal Radiol* 1987; **16**:387-92.
4. Zindrick MR, Young MP, Daley RJ, Light T. Metastatic tumours of the foot: case report and literature review. *Clin Orthop Rel Res* 1982; **170**:219-25.
5. Ozcanli H, Ozdemir H, Ozenci AM, Söyüncü Y, Aydın AT. [Metastatic tumours of the hand in three cases]. *Acta Orthop Traumatol Turc* 2005; **39**:445-8. Turkish.
6. Wu KK. Bronchogenic carcinoma with metastases to the foot: a report of two cases. *J Foot Ankle Surg* 1995; **34**:322-6.
7. Joll, CA. Metastatic tumours of bone. *Br J Surg* 1923; **11**:38-72.
8. Shepherd DM, Dzikowski M, Chussid F. Bronchogenic carcinoma mimicking paronychia and osteomyelitis in the great toe. *J Foot Ankle Surg* 1997; **36**:115-9.
9. Galamari CM, Kertesz A, Oliva R, Porta J, Galamari FC. Metastases of bronchogenic carcinoma to the thumb. *Med Oncol* 1998; **15**:282-5.
10. Gall RJ, Sim FH, Pritchard DJ. Metastatic tumours to bones of the foot. *Cancer* 1976; **37**:1492-5.

.....★.....