

Chronic Myeloproliferative Neoplasm with Concurrent BCR-ABL Translocation and JAK2 Mutation

Sir,

Chronic myeloproliferative neoplasms (CMNs) are clonal disorders of haematopoietic stem cells and are classified according to their clinical and phenotypical features and genetic aberrations.^{1,2} CMNs are divided according to the presence of a Philadelphia chromosome/BCR-ABL fusion as chronic myeloid leukaemia (CML Ph+). Philadelphia chromosome negative (Ph-CMN) conditions are polycythemia vera (PV), essential thrombocythemia (ET) and primary myelofibrosis (PMF). More than 95% cases of PV and 60% of ET and PMF are positive for JAK2 mutations.³

Among more than 100 published cases of Philadelphia chromosome positive chronic myeloid leukaemia (Ph+ CML) investigated for Janes kinase mutation, no mutated case has been found.^{4,5} Selected patients with Ph+ CML with marked thrombocytosis prove to be negative for the JAK2 mutation.⁵ We report here a case of untreated patient of chronic myeloproliferative neoplasm with concurrent BCR-ABL translocation and JAK2 mutation. This 50-year-old man presented with splenomegaly, leukocytosis (white blood cell count 27300/ul), haemoglobin (Hb) level of 12.7 g/dl and thrombocytes (platelet count 248000/ul), neutrophils at 57%, myelocytes at 30%, metamyelocytes at 6% and blasts at 2%.

Bone marrow aspiration revealed diluted cellularity, normoblastic erythropoiesis, myelopoiesis hyperplastic with left shift and megakaryocytosis. Sections of bone marrow trephine showed mostly bony trabeculae, however, haematopoietic tissue was fairly adequate. Architecture was preserved in the larger portions of the marrow with normal haematopoiesis. Other areas however, showed increased fibrosis and fibroblastic activity with loss of normal marrow architecture. In those areas, megakaryocytes were increased, whereas other haematopoietic elements were uniformly depressed. Plasma cells were prominent. Reticulin was increased Grade-II/III. BCR-ABL translocation by FISH was detected in 25% of the 500 nuclei counted. PCR was positive for JAK2 mutation.

This case demonstrates that in untreated patient of chronic myeloproliferative disorder BCR-ABL and JAK2, mutation may be concomitantly detectable in haematopoietic cells of a single patient. Four well documented

cases with concurrent JAK2 and BCR-ABL translocation were reported by Hussain *et al.*⁶ It has been hypothesized by Kralovics *et al.*⁷ that, a varying combination of different molecular defects in a pathologic stem cell might be responsible for the phenotypic heterogeneity as seen in this case. The frequency of BCR-ABL translocation and concurrent JAK2 mutation might be low. Further studies on large cohorts are needed to clarify the co-existence of JAK2 mutation and BCR-ABL translocation in CMNs, as the sensitivity of newer technique of mutated alleles improve. At present, patients with concurrent BCR-ABL translocation are being treated with TKI's imatinib, nilotinib and dasatinib. No drug is available to treat JAK2 mutation. The natural history of these patients and their prognosis is unknown and needs further follow-up.

REFERENCES

1. Tefferi A, Vardiman JW. Classification and diagnosis of myeloproliferative neoplasms.: the 2008 World Health Organization criteria and point-of-case diagnostic algorithms. *Leukaemia* 2008; **22**:14-22. Epub 2007 Sep 20. Comment in: *Leukaemia* 2008; **22**(11):2118-9.
2. Tefferi A, Thiele J, Orazi A, Kvasnicka HM, Barbui T, Hanson CA, *et al.* Proposals and the rationale for revision of World Health Organization diagnostic criteria for polycythemia vera, essential thrombocythemia, and primary myelofibrosis: recommendations from an ad-hoc international expert panel. *Blood* 2007; **110**:1092-7. Epub 2007 May 8. Comment in: *Blood* 2008; **111**:1741; author reply 1742.
3. James C, Ugo V, Le Couédic JP, Staerk J, Delhommeau F, Lacout C, *et al.* A unique clonal JAK2 mutation leading to constitutive signalling causes polycythemia vera. *Nature* 2005; **434**:1144-8.
4. Jelinek J, Oki Y, Gharibyan V, Bueso-Ramos C, Prchal JT, Verstovsek S, *et al.* JAK2 mutation 1849G > T is rare in acute leukaemias, but can be found in CMML, Philadelphia chromosome-negative CML, and megakaryocytic leukaemia. *Blood* 2005; **106**:3370-3. Epub 2005 Jul 21.
5. Bock O, Busche G, Koop C, Schroter S, Buhr T, Kreipe H. Detection of single hotspot mutation in the JH2 pseudokinase domain of Janes kinase 2 in bone marrow trephine biopsies derived from chronic myeloproliferative disorders. *J Mol Diagn* 2006; **8**:170-7.
6. Hussain K, Bock O, Theophile K, Seegers A, Arps H, Basten O, *et al.* Chronic myeloproliferative diseases with concurrent BCR-ABL junction and JAK2V617F mutation. *Leukaemia* 2008; **22**:1059-62.
7. Kralovics R, Teo S, Lis S, Theocharides A, Buser AS, Tichelli A, *et al.* Acquisition of the V617F mutation of JAK2 in a late genetic event in a subset of patients with myeloproliferative disorders. *Blood* 2006; **108**:1377-80.

DR. NAUMAN SALEEM SIDDIQUI, DR. HAROON SALEEM SSIDDIQUI,
DR. QURAT-UL-AIN AND DR. SALEEM AHMAD SIDDIQUI

Correspondence:

DR. SALEEM AHMAD SIDDIQUI
Consultant Medical Oncologist, Shifa International Hospital
H-8/4, Islamabad

Interferences or Real ECG Changes?

Sir,

A 76-year-old female with previous history of hypertension and hypercholesterolemia was admitted. She had 6 months history of intermittent episodes of complete loss of consciousness, however, she denied any symptoms suggestive of epilepsy, shortness of breath, palpitations, light-headedness, dizziness or chest pains either preceding or after the episodes of blackouts. She did however sustain bruises with each episode and was, therefore, increasingly scared to live on her own. During her admission, she was extensively investigated with normal baseline blood tests, normal CXR, a normal CT brain, a normal 12 lead ECG, several normal ambulatory ECG recordings and a normal trans-thoracic echocardiogram. She underwent a treadmill exercise stress test (standard Bruce protocol) and managed 96% of her age predicted heart rate, with no ECG changes or symptoms. In view of an unclear diagnosis, she was recommended for implantable loop recorder (ILR). Whilst awaiting ILR implantation, a review of her notes by a senior doctor in the team revealed a rhythm strip recording (obtained at 04:27 hours on the day of admission (Figure 1).

A junior doctor had labelled Figure 1 as “interference” only, following which it was filed in the notes! The strip

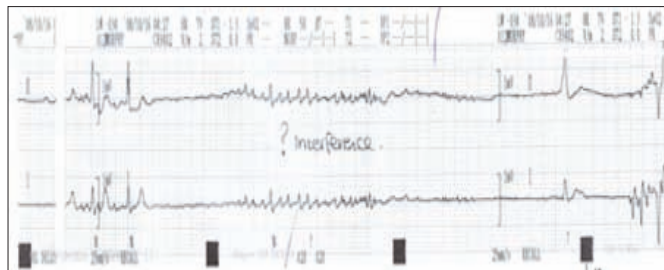


Figure 1: Rhythm strip recorded on ECG.

actually showed a 7-second pause with an escape ventricular beat, followed by restoration of normal sinus rhythm. In view of this rhythm strip, she was recommended for implantation of a dual chamber permanent pacemaker. Patient remained asymptomatic on 9 months follow-up with no further episodes of blackouts.

ECG interference has been reported with the use of electrocautery during the surgical procedure, use of mobile phones, those with hearing aid, permanent pacemaker and the use of portable digital media player in patients with implantable loop recorders.¹⁻⁴ In this case the patient had no external devices and the interference was probably motion artifacts.

The ECG rhythm strip had been wrongly labelled as interference. An appropriate early interpretation could have saved valuable time and cost to the patient.

REFERENCES

1. Ketchey C, Goldschlager N, Tang J, Young WL. Electrocautery interference with intra-operative electrocardiogram mimicking ST-segment depression. *J Electrocardiol* 2009; **42**:425.
2. Brodli M, Robertson D, Wyllie J. Interference of electrocardiographic recordings by a mobile telephone. *Cardiol Young* 2007; **17**:328-9.
3. Baranchuk AM, Kang J, Shaw C, Witjes R. Electromagnetic interference produced by a hearing aid device on electrocardiogram recording. *J Electrocardiol* 2008; **41**:398-400. Epub 2008 Mar 19.
4. Thaker JP, Patel MB, Jongnarangsin K, Liepa VV, Castellani M, Thakur RK. Electromagnetic interference in an implantable loop recorder caused by a portable digital media player. *Pacing Clin Electrophysiol* 2008; **31**:1345-7.

DR. TAHIR HAMID, DR. LUCY FOSKETT, DR. SAMMAN ROSE
AND DR. NADIM MALIK

Correspondence:

Dr. Tahir Hamid
28-Blanchard Street, Hulme, Manchester, M15 5PN,
United Kingdom
E-MAIL: tahirhamid76@yahoo.co.uk

.....★.....